

## Case Report

**Running Title:** Managing Pediatric Pituicytoma

Received: March 29, 2024; Accepted: October 13, 2024

### **Pediatric Pituitary Pituicytoma: A Case Report of Comprehensive Management**

Noushin Saleki<sup>\*</sup>, MD, Kazem Anvari<sup>\*\*♦</sup>, MD, Hamidreza Hashemian<sup>\*\*\*</sup>, MD

*\*Imam Reza Hospital, Radiation-Oncology Department, Mashhad University of Medical Sciences, Mashhad, Iran*

*\*\*Cancer Research Center, Mashhad University of Medical Sciences, Mashhad, Iran*

*\*\*\*Razavi Hospital, Pathology Department, Mashhad, Iran*

#### **♦Corresponding Author**

Kazem Anvari, MD

Cancer Research Center,

Mashhad University of Medical Sciences,

Mashhad, Iran

Tel: +98-5138426082

Fax: +985138428622

Email: [salekinoushin@gmail.com](mailto:salekinoushin@gmail.com)

#### **Abstract**

Pituicytoma, originated from pituicyte cells, is a rare pituitary tumor, especially in children. In 2007, this tumor was classified by WHO as grade 1 CNS tumors. The symptoms of this tumor can be headache, visual or endocrine disorders. Diagnosis is made through imaging and further confirmed by pathology and immunohistochemistry. Treatment is based on surgery, which can be risky due to the proximity to important organs and can also be accompanied by extensive bleeding. Given the low prevalence of the disease and the lack of sufficient information about the treatment of this disease, it is necessary to report the treatments performed in the existing cases to complete the evidence. We present the case of a 9-year-old boy who initially presented with headache and blurred vision, leading to the discovery of pituitary pituicytoma. This rare tumor necessitated a multidisciplinary approach involving neurosurgery and subsequent radiotherapy due to residual tumor presence post-surgery. This case highlights the challenges in diagnosis, surgical intervention, and long-term management of pediatric pituitary pituicytomas.

**Keywords:** Pediatrics, Pituitary neoplasms, Pituicytoma, Case reports, Comprehensive health care

## **Introduction**

Pituitary pituicytomas are exceedingly rare tumors arising from pituicytes of the neurohypophysis or infundibulum, particularly in pediatric patients.<sup>1</sup> This tumor was named in the 2007 World Health Organization (WHO) classification as tumors of the central nervous System (a WHO grade 1 tumor).<sup>2</sup> Initial symptoms depending on the location of the tumor and tumor size often include headache, visual disturbances, and endocrine abnormalities.<sup>3</sup> Differential diagnosis based on imaging exams can suggest pituitary adenoma, meningiomas, craniopharyngioma, granular cell tumor, pilocytic astrocytoma and lymphocytic hypophysitis.<sup>4</sup> Immunohistochemistry (IHC) characteristics of the pituicytomas include S-100 protein, glial fibrillary acidic protein (GFAP), and epithelial membrane antigen (EMA), which can help in the diagnosis.<sup>1</sup> Surgical resection is the primary treatment, but complete excision can be challenging due to the intricate location of the tumor and its vital importance that unlike pituitary adenomas, is prone to heavy bleeding during the surgical resection.<sup>2</sup> In this study, we present the case of a 9-year-old boy with a pituitary pituicytoma who underwent surgical intervention followed by radiotherapy due to residual tumor presence.

## **Case Presentation**

A 9-year-old male presented with a two-month history of persistent headaches and gradually worsening blurred vision. Physical examination revealed stable vital signs and no notable neurological deficits. Laboratory tests include complete blood count and biochemistry tests were within normal limits, except for vitamin D, which was deficient (Table1). Examination of hepatitis viruses, human T-lymphotropic virus (HTLV-1&2) and acquired immune deficiency syndrome (AIDS) was negative. Endocrine evaluation (growth hormone, insulin-like growth factor-

1 (IGF-1), thyroid stimulation hormone, luteinizing hormone, follicle-stimulating hormone, prolactin and adrenocorticotrophic hormone indicated normal hormone levels. Preoperative magnetic resonance imaging (MRI) of the brain demonstrated a suprasellar isodense solid mass with expansion to Sella that contain foci of calcification in imaging without contrast and a 29×30 mm lobulated mass with abnormal signal and enhancement in Sella with expansion to bilateral suprasellar, parasellar and suprasellar cistern spaces around the third ventricle with mass effect and pressure on optic chiasm and pituitary stalk in contrasted images; and a little peripheral restriction in this mass was seen in diffusion-weighted imaging sequence. Other parts of the brain are normal in MRI. Differential diagnoses based on images included: pituitary adenomas and meningiomas, and less commonly, from pilocytic astrocytomas, craniopharyngiomas, ganglioglioma, germ cell tumors, sarcoidosis, and metastatic tumors. MRI images can be seen in figure 1.

## ***Surgical intervention***

According to the progress of symptoms, the patient underwent trans-sphenoidal surgery. Intraoperatively, the tumor was found to be adherent to surrounding structures, leading to a subtotal resection to preserve critical neural and vascular elements. No bleeding was observed.

Histopathological gross examination shows 0.8×0.4×0.3 cm tumor consists of tiny fragments of light brown soft tissue. Microscopic findings show neoplastic lesion composed of spindle cells with wavy spindly nuclei with no atypia arranged as fascicles haphazardly arranged with some histiocytes between them. Necrosis, mitosis, verocay bodies, nuclear palisading and psammoma bodies were not seen. Immunohistochemistry shows S100 protein, GFAP, CD56 and synaptophysin positive, and negative for progesterone receptor (PR), estrogen receptor

(ER), EMA and chromogranin (Table 2). The specimen was also viewed by a pathologist skilled in the field of central nervous system (CNS). The microscopic report was similar to the previous one and another IHC was performed, which reported positive thyroid transcription factor-1 (TTF1) (Figure 2) marker that confirmed the diagnosis of pituicytoma. You can see the histopathological images in figure 3.

A 3-month postoperative brain MRI without contrast showed a lobulated extra axial mass in the Sella with suprasellar extension without affecting surrounding structures.

#### ***Radiotherapy***

Due to the residual tumor and the potential for recurrence, the patient underwent adjuvant Intensity-modulated radiation therapy (IMRT). Radiotherapy was administered with 54 Gray /30 Fraction over 6 weeks, gross tumor volume was defined to residual mass.

#### ***Follow-up and outcome***

In the 9-month follow-up, the patient had no symptoms, and serial hormonal tests were normal. MRI scans displayed a gradual reduction in the size of the residual tumor. The patient remains under close surveillance with regular imaging and endocrine assessments.

#### ***Ethical considerations***

The study was approved by the ethics committee of Mashhad University of Medical Sciences, Mashhad, Iran (ethics code: IR.MUMS.REC.1403.106).

#### **Discussion**

Brain tumors are the most common solid tumors in children which account for 15-20% of pediatric cancers. Fewer pituitary tumors in children compared with adults cause more complicated evaluation and management. Pituitary masses have a wide range of histologies and include adenomas, craniopharyngiomas, germ cell tumors, and

others. Tumors are mostly benign, but they can also cause serious morbidity.<sup>3</sup>

Pituicytoma is a very rare tumor defined as a benign spindle cell tumor originates from pituicytes, and was recognized as an entity by the WHO Classification of Tumors of the Central Nervous System in 2007.<sup>5</sup> There were no more than 150 cases of pituicytoma total reported worldwide based on available information.<sup>2</sup> Eight cases occurred in children under 15 years of age, and other cases occurred in adults. The average age of the patients was fifties and sixties, which is the same between men and women.<sup>1</sup>

The clinical symptoms are variable depends on tumor size and location the most common symptoms at presentation of pituicytoma have been headache (38.9%) followed by vision disturbance (31.5%) and pituitary insufficiency.<sup>6</sup>

The neuroimaging characteristics of pituicytomas are easily confused with other tumors in the sellar or suprasellar region, such as pituitary adenomas and craniopharyngiomas.<sup>1</sup>

The radiological imaging reveal iso- or hypointense T1 weighted images which are homogeneously contrast enhancing and slightly hyperintense or isointense on T2-weighted images.<sup>7</sup> These features can be seen in patients with pituitary adenomas. However, based on the imaging, it is not possible to make an accurate diagnosis.<sup>8</sup> Our case has a sellar enhancing mass with expansion to bilateral suprasellar, parasellar and suprasellar cistern spaces.

Histologic appearance and immunohistochemical findings help to diagnose. Pituicytomas contain bipolar spindle cells that are arranged in a bundle or storiform pattern with no granules. Nuclei are moderate in size, often oval or elongate, and have little atypia. Mitoses are rare and can be absent. No Rosenthal fibers and eosinophilic granular components were seen.<sup>5</sup> Most of these features are present in this case. IHC is

positive for S-100, GFAP, EMA, and TTF-1, and negative for PAS, neuroendocrine marker reactivity, such as neurofilament protein, synaptophysin or chromogranin.<sup>8</sup> This case has S-100, GFAP and TTF-1 positive IHC but the EMA was negative. The best chance for pituitary tumor cure appears to be surgical gross total resection because partial resection carries the possibility of recurrence.<sup>3</sup> The surgical approaches are trans-frontotemporal craniotomy and a trans-nasal transsphenoidal.<sup>2</sup> But since most tumors are not completely resected and the possibility of recurrence is high, target adjuvant treatments can be considered as a treatment option in the future. Mende et al. have mentioned the potential use of targeted therapies due to the presence of VEGFR and SSTR positive in pituitary tumor, which requires further investigation and clinical trial.<sup>9</sup> The patients who underwent subtotal resection such as our case were also treated with postoperative radiotherapy. However, the value of adjuvant therapy is unclear in the absence of evidence from a large series.<sup>10</sup> Considering that pituitary tumor in children is rare and treatment information is incomplete in this case, it is important that clinicians and pathologists consider this issue in the differential diagnosis of sellar masses. We decided to introduce our own patient and the treatment method performed to help increase information about this rare disease in children.

### **Conclusion**

Pediatric pituitary pituitary tumors are extremely rare and pose diagnostic and therapeutic challenges. Surgical resection is the primary treatment, although achieving complete excision may not always be feasible. In cases of residual tumor, radiotherapy can be a suggestive adjuvant therapy. Long-term follow-up is crucial to monitor tumor recurrence and potential late effects of radiotherapy.

This case underscores the importance of a multidisciplinary approach in managing pediatric pituitary pituitary tumors. Timely diagnosis, surgical intervention, and adjuvant radiotherapy, when necessary, can lead to favorable outcomes and improved quality of life for affected children. Further research is needed to better understand the optimal treatment strategies for these rare tumors.

### **Informed Consent**

Written informed consent was obtained from the patient's parent.

### **Acknowledgements**

We would like to thank the patient and their family for their cooperation and consent for this case report.

### **Funding**

None declared.

### **Authors' Contribution**

Dr. Noushin Saleki: Conception and design of the study; acquisition of data; analysis and interpretation of data; drafting the article; critical revision of the article for important intellectual content; final approval of the version to be published. Dr. Kazem Anvari: Conception of the study; Acquisition of data; analysis and interpretation of data; drafting the article; revising the article critically for important intellectual content; final approval of the version to be published. Dr. Hamidreza Hashemian: Conception and design of the study; acquisition of data; drafting the article; revising the article critically for important intellectual content; final approval of the version to be published.

### **Conflict of Interest**

None declared.

### **References**

1. Guerrero-Pérez F, Marengo AP, Vidal N, Iglesias P, Villabona C.

- Primary tumors of the posterior pituitary: A systematic review. *Rev Endocr Metab Disord.* 2019;20(2):219-38. doi: 10.1007/s11154-019-09484-1. PMID: 30864049.
2. Yasuda ME, Recalde R, Jalón P, Prost D, Golby A, Zaninovich R. Surgical approach to the treatment of pituicytoma. Report of five cases and a literature review. *World Neurosurg X.* 2023; 19:100186. doi: 10.1016/j.wnsx.2023.100186. PMID: 37026087; PMCID: PMC10070180.
  3. Castellanos LE, Misra M, Smith TR, Laws ER, Iorgulescu JB. The epidemiology and management patterns of pediatric pituitary tumors in the United States. *Pituitary.* 2021;24(3):412-9. doi: 10.1007/s11102-020-01120-5. PMID: 33433891; PMCID: PMC8415131.
  4. Lefevre E, Bouazza S, Bielle F, Boch AL. Management of pituicytomas: a multicenter series of eight cases. *Pituitary.* 2018;21(5):507-14. doi: 10.1007/s11102-018-0905-3. PMID: 30062665.
  5. Salge-Arrieta FJ, Carrasco-Moro R, Rodríguez-Berrocal V, Pian H, Martínez-San Millán JS, Iglesias P, et al. Clinical features, diagnosis and therapy of pituicytoma: an update. *J Endocrinol Invest.* 2019;42(4):371-84. doi: 10.1007/s40618-018-0923-z. PMID: 30030746.
  6. Zygourakis CC, Rolston JD, Lee HS, Partow C, Kunwar S, Aghi MK. Pituicytomas and spindle cell oncocytomas: modern case series from the University of California, San Francisco. *Pituitary.* 2015;18(1):150-8. doi: 10.1007/s11102-014-0568-7. PMID: 24823438.
  7. Wang J, Liu Z, Du J, Cui Y, Fang J, Xu L, et al. The clinicopathological features of pituicytoma and the differential diagnosis of sellar glioma. *Neuropathology.* 2016;36(5):432-40. doi: 10.1111/neup.12291. PMID: 26919073.
  8. El Hussein S, Vincentelli C. Pituicytoma: Review of commonalities and distinguishing features among TTF-1 positive tumors of the central nervous system. *Ann Diagn Pathol.* 2017;29:57-61. doi: 10.1016/j.anndiagpath.2017.05.004. PMID: 28807344.
  9. Mende KC, Matschke J, Burkhardt T, Saeger W, Buslei R, Buchfelder M, et al. Pituicytoma-An outlook on possible targeted therapies. *CNS Neurosci Ther.* 2017;23(7):620-6. doi: 10.1111/cns.12709. PMID: 28556544; PMCID: PMC6492650.
  10. Yang X, Liu X, Li W, Chen D. Pituicytoma: A report of three cases and literature review. *Oncol Lett.* 2016;12(5):3417-22. doi: 10.3892/ol.2016.5119. PMID: 27900014; PMCID: PMC5103963.

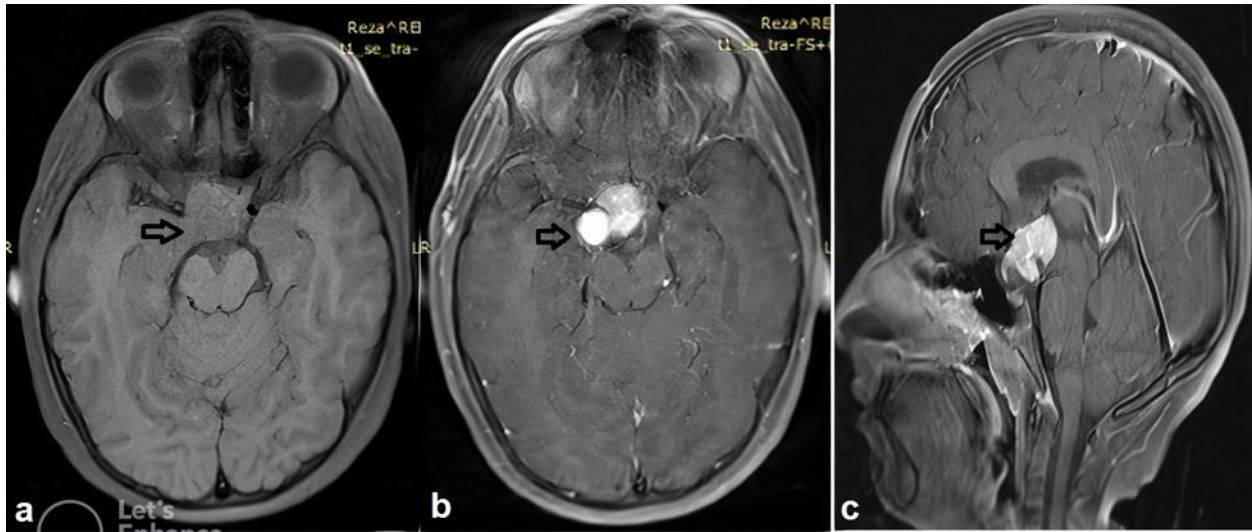


Figure 1. This figure shows the MRI images of the patient; axial cut of T1 images without contrast (a) show a suprasellar isodense solid mass that contain foci of calcification, axial (b) and sagittal (c) cut of T1 images with contrast shows an enhancing lobular mass invaded to surrounding structures.

MRI: Magnetic resonance imaging

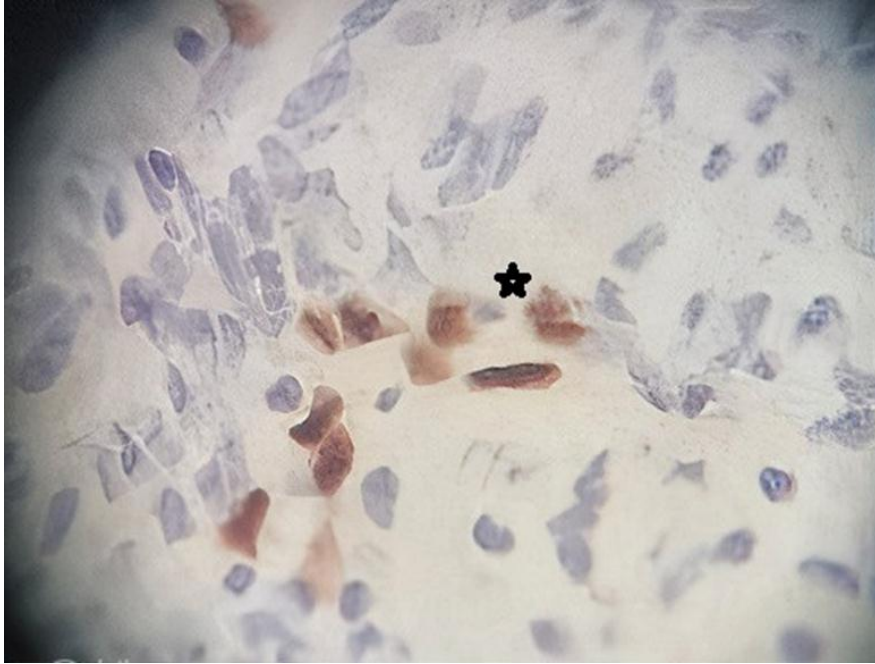

Figure 2. This figure shows the microscopic images of the patient's IHC findings; TTF1 staining in IHC shows the nuclear positivity in tumor cells.

IHC: Immunohistochemistry; TTF1: Thyroid transcription factor 1



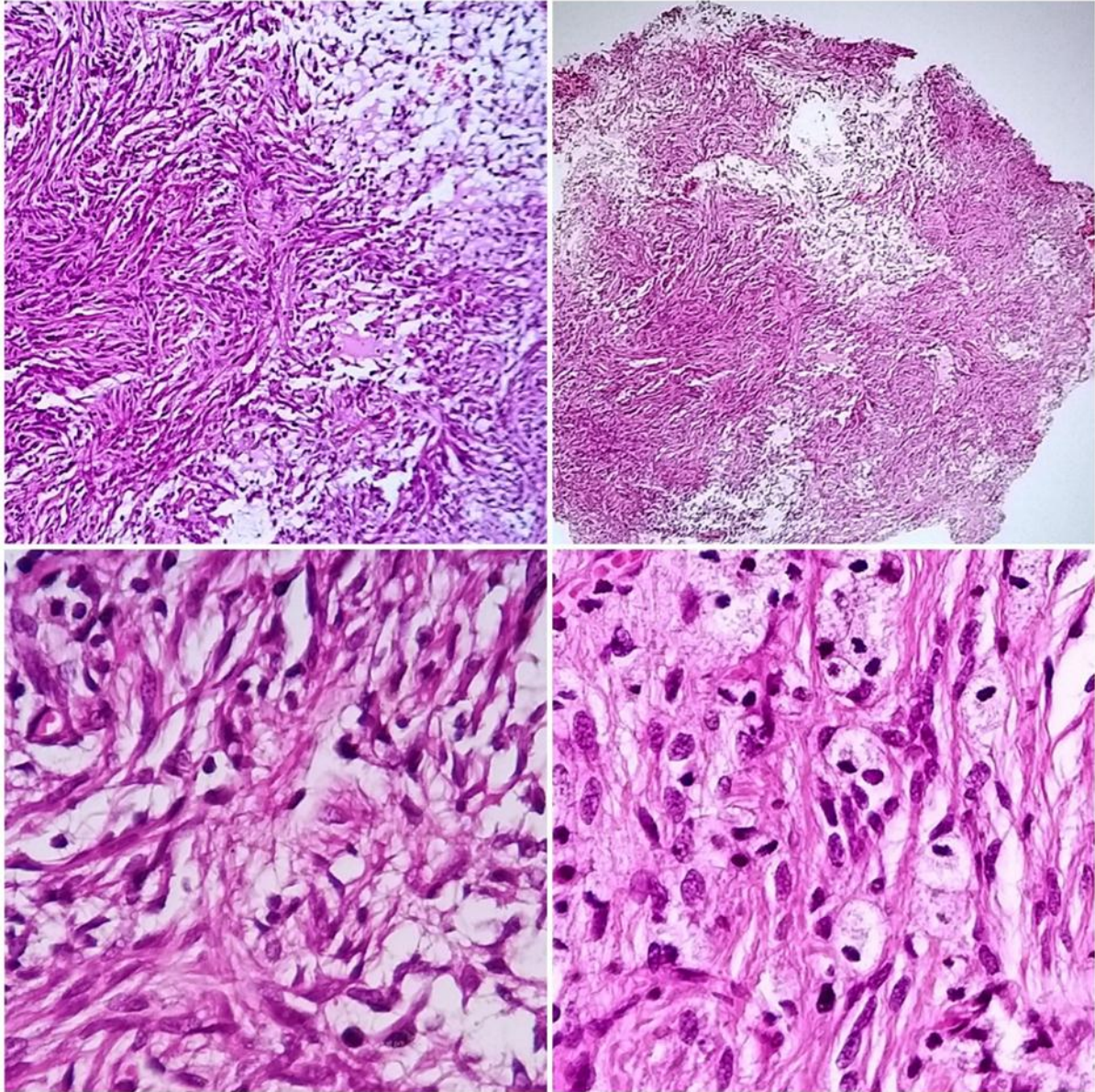


Figure 3. This figure shows the pituitary adenoma, microscopic finding; cytological benign cells with round hyperchromatic nuclei, rare mitosis and no necrosis within fibrillary matrix. All the figures have H&E staining. The microscopic magnification in left upper figure is 100 $\times$ , right upper figure is 40 $\times$  and both lower figures are 400 $\times$ .  
H&E: Hematoxylin and eosin



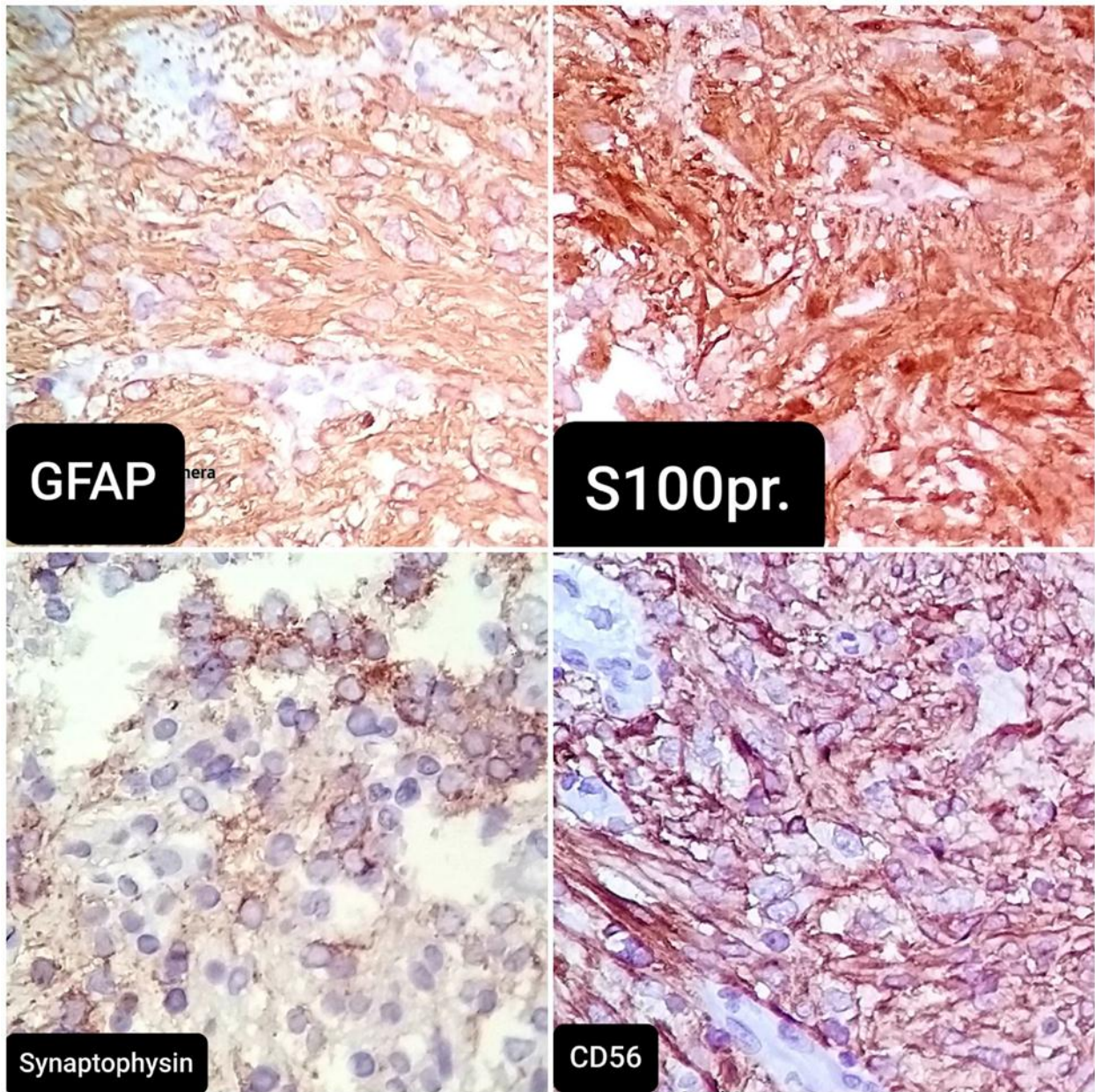


Figure 4. This figure shows the pituitary tumor, IHC studies; cells and fibrillary background are positive for GFAP, Synaptophysin, CD56 and S100 protein. Microscopic magnification is 400× in all images.

H&E: Hematoxylin and eosin; GFAP: Glial fibrillary acidic protein

Table 1. The patient's tests before starting the treatment

<b>Test</b>	<b>Result</b>	<b>Unit</b>	<b>Reference range</b>
<b>White blood cells</b>	9540	1000/ $\mu$ L	4300-11000
<b>Hemoglobin</b>	15	g/dL	11.5-18
<b>Platelets</b>	464000	1000/ $\mu$ L	150000-450000
<b>Fasting blood sugar</b>	95	mg/dL	70-100
<b>Blood urea nitrogen</b>	12	mg/dL	8-25
<b>Creatinine</b>	0.7	mg/dL	0.2-0.7
<b>Calcium</b>	10.1	mg/dL	8.2-10.6
<b>Phosphorus</b>	4.9	mg/dL	3-5.4
<b>Alkaline phosphatases</b>	519	U/L	180-1200
<b>Lactate dehydrogenase</b>	343	U/L	<500
<b>Sodium</b>	138	mEq/L	135-145
<b>Potassium</b>	4.1	mEq/L	3.5-5.5
<b>c-reactive protein</b>	1.6	mg/L	Up to 10
<b>25-hydroxyvitamin D</b>	<b>16</b>	ng/mL	Deficiency <20

Table 2. The results of immunohistochemical staining of the patient

<b>IHC test</b>	<b>Result</b>
<b>S100</b>	Positive
<b>GFAP</b>	Positive
<b>Synapthophysin</b>	Positive
<b>CD56</b>	Positive
<b>TTF1</b>	Positive
<b>ER</b>	Negative
<b>PR</b>	Negative
<b>EMA</b>	Negative
<b>Chromogranin</b>	Negative

GFAP: Glial fibrillary acidic protein; TTF1: Thyroid transcription factor 1; ER: Estrogen receptor; PR: Progesterone receptor; EMA: Epithelial membrane antigen; IHC: Immunohistochemistry