

Giant Liver Hydatid Cyst: A Case Report and Review of the Literature

Ahmad Izadpanah¹, MD,^{ID} Ali Mohammad Bananzadeh^{1*}, MD,^{ID} Gholamreza Abdollahifard², MD; Cambyz Irajie³, MD, PHD; Qasem Asgari⁴, PhD; Elham Ahmadi¹, MD; Mohammad Javad Yavari Barhaghtalab^{1*}, MD, MPH^{ID}

¹Colorectal Research Center, Shiraz University of Medical Sciences, Shiraz, Iran

²Department of Community Medicine, School of Medicine, Shiraz University of Medical Sciences, Shiraz, Iran

³Department of Medical Biotechnology, School of Advanced Medical Sciences and Technologies, Shiraz University of Medical Sciences, Shiraz, Iran

⁴Department of Parasitology and Mycology, School of Medicine, Shiraz University of Medical Sciences, Shiraz, Iran

*Corresponding authors:

Ali Mohammad Bananzadeh, MD; Colorectal Research Center, Shahid Faghihi Hospital, Shiraz University of Medical Sciences, Shiraz, Iran. Tel/Fax: +98 71 36281453
Mohammad Javad Yavari Barhaghtalab, MD, MPH; Colorectal Research Center, Shahid Faghihi Hospital, Shiraz University of Medical Sciences, Shiraz, Iran.
Tel/Fax: +98 71 36281453

Received: 2024-02-26

Revised: 2024-03-24

Accepted: 2024-04-15

Abstract

Cystic *echinococcosis* (CE) is a parasitic disease caused by the larval stages of *Echinococcus* and is considered a neglected disease of public health worldwide. CE primarily affects the liver and demonstrates distinctive radiological findings in computed tomography (CT) and ultrasonography (US). Surgery is considered the mainstay of CE treatment. The patient was a 17-year-old man admitted to the Emergency Department of Shahid Faghihi Hospital affiliated with Shiraz University of Medical Sciences with dull right upper quadrant abdominal pain, loss of appetite, abdominal distention, and fullness. An abdominal CT scan revealed a giant hepatic cyst measuring about 24×20×15 cm in the right hepatic lobe (RHL) with a pressure effect on the right kidney, pancreas, and bowel loops. Semi-chevron incision was done and the patient underwent partial precystectomy with capitonage and omentoplasty. The surgical outcome was uneventful and the patient was discharged on the eighth day after the surgery with the oral Albendazole. Reviewing the literature, our case was the 5th rank according to the size of the recorded published cases. The most common countries where the largest liver hydatid cysts were reported were Greece and Turkey. The most common surgery was the open surgery and the most common incisions were Kocher and then Chevron incisions. When dealing with a huge liver cyst, a high index of suspicion for echinococcal etiology becomes important in endemic areas such as Iran. The choice of treatment for giant hepatic cysts substantially seems to be radical surgery by surgical ablation in general to mitigate the mortality and morbidity rate, because they are at risk of rupture, anaphylaxis, and so forth. (The abstract is too long for a case report [260 words], it should be around 100 words. The part I highlighted can be deleted.)

Keywords: Giant, Liver, Cysts, Echinococcosis, hepatic, Case reports

Please cite this paper as:

Izadpanah A, Bananzadeh AM, Abdollahifard GR, Irajie C, Asgari Q, Ahmadi E, Yavari Barhaghtalab MJ. Giant Liver Hydatid Cyst: A Case Report and Review of the Literature. *Iran J Colorectal Res.* 2024;12(1):27-32. doi: 10.30476/acrr.2024.101868.1210.

Introduction

Echinococcosis is a zoonotic disease caused by the larval stages of the taeniid cestodes

of the genus *Echinococcus*. The two major types of infection in humans are cystic *echinococcosis* or hydatidosis and alveolar *echinococcosis* (1). Currently, the hydatid cyst has become a re-emerging

disease and a public health concern around the world (2). Hydatid cyst of the liver is a significant but neglected public health concern in Iran (3). The liver followed by the lungs is the most common site for the occurrence of the larval form of hydatid disease. Though a variety of treatment modalities have been successfully employed, there is a lack of consensus on the most appropriate method (4, 5). Medical therapy in the form of Benzimidazole and its derivatives and praziquantel has been advocated for treatment (6). Minimal invasive procedures such as PAIR (puncture, aspiration, injection, re-aspiration) and PEVAC (percutaneous evacuation of cyst content), open surgery (conservative or radical) and laparoscopic surgery are other recommended treatments(4, 6-8).

Patients affected by liver hydatid cysts from *Echinococcus granulosus* are generally asymptomatic for a long time. They usually seek medical care when their cysts have reached a large size with pressure effect or devastating impact on their liver parenchyma (9-11). The word "Giant" has different connotations for different locations and organs of the body. A 2 cm cyst is described as a giant hydatid cyst in the heart (interventricular septum) (12, 13). This means that the term giant cyst is probably relative to the site and size of the cyst, concerning the hosting organ (10).

Giant cysts in the liver are defined as cysts measuring ≥ 10 cm in diameter, and these cysts require more caution and need an experienced surgeon and relevant instrumentation for their operation (14). Herein, we present a rare case of a giant hydatid cyst from the right hepatic lobe (RHL) and review the literature on giant liver hydatid cysts.

Case Presentation

In 2017, a 17-year-old man was admitted to the Emergency Department of Shahid Faghihi Hospital affiliated with the Shiraz University of Medical Sciences with chief complaints of dull right upper quadrant abdominal pain, loss of appetite, abdominal distention, and fullness for about a month. The patient was afebrile, non-icteric with mild pallor. Abdominal examination revealed right upper quadrant abdominal tenderness with an enlarged liver and a palpable mass. The patient was living in the city ringway and had contact with dogs. His medical history was unremarkable, and he had no history of liver disease. He had no surgical history. The family history of the patient was unremarkable. The patient did not smoke or drink alcohol.

The abdominal ultrasonography (US) revealed that the liver is prominent in size with normal liver parenchymal echoic pattern and a huge cyst with a large floating membrane with internal echo in the liver lobe (Figure 1). Abdominal computed tomography (CT) scan confirmed the diagnosis of the US, as there were two cysts, one giant cyst

measuring about $24 \times 20 \times 15$ cm in the RHL (segments – V, VI, VII, VIII) with pressure effect on the right kidney, pancreas, and bowel loops and another smaller one measuring $9 \times 8 \times 8$ cm in the left liver lobe (segments – II, III) (Figure 2).

The Anti-*Echinococcus* IgM and IgG Enzyme-Linked Immunosorbent Assay (ELISA) test was used for the detection of parasite-specific antibodies in the serum for detection of the hydatid cyst and both of them were positive confirming the diagnosis. Complete blood count and liver function tests were within the normal range.

RHL extends to the sub-hepatic fossa, occupying the entire right lobe of the liver measuring about $26 \times 20 \times 15$ cm (about 4000 cc). The features were highly suggestive of a giant active hydatid cyst. There was another cyst measuring $9 \times 8 \times 7.5$ cm in the posterior aspect of the left

A semi-chevron incision was conducted and the operative field was protected from any spillage

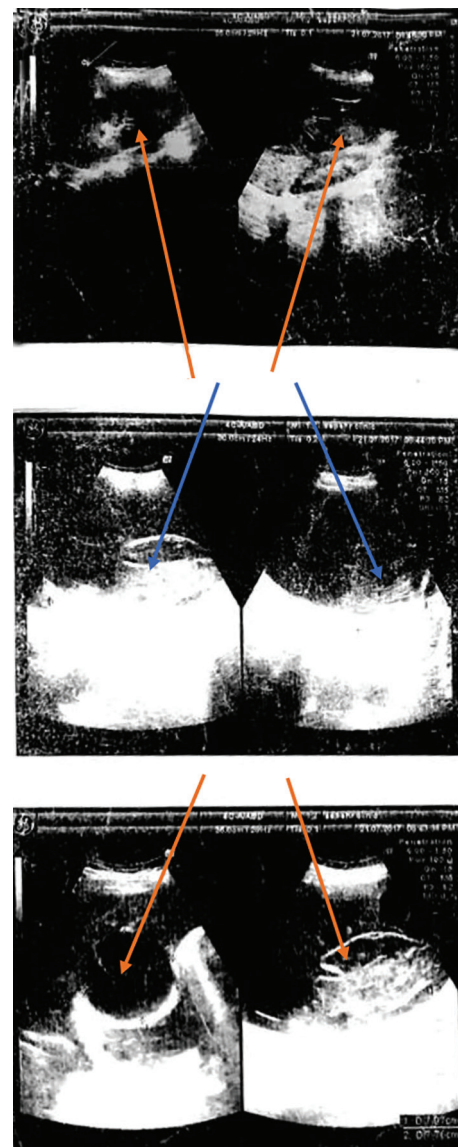


Figure 1: Abdominal US showed a giant active hydatid cyst with a large floating membrane with internal echo in the RHL, $26 \times 20 \times 15$ cm (brown arrows), and another hydatid cyst measuring $9 \times 8 \times 7.5$ cm in LHL (blue arrows).

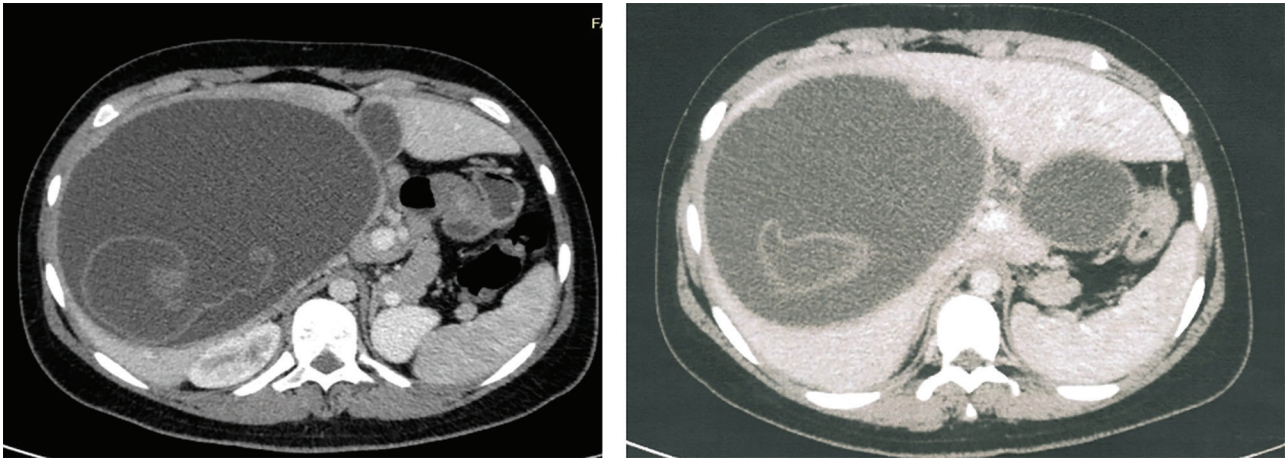


Figure 2: Abdominal CT scan revealed two cysts in the liver, one giant cyst measuring about 24×20×15 cm in the RHL with pressure effect on the right kidney, pancreas, and bowel loops and another smaller one measuring 9×8×8 cm in the LHL.

to reduce the risk of intraperitoneal soiling and contamination by using gauze packs soaked in 20% hypertonic saline. Afterward, the instillation of the scolicidal agent (hypertonic saline 20% sodium chloride solution) was done for 10 minutes, followed by respiration through the exposed cyst wall using a 16-gauge needle. Then, the cyst was unroofed, and careful evacuation of the multiple daughter cysts by aspiration with a closed system suction device was performed. Following this, partial precystectomy with capitonnage was done, dead spaces were filled with pedicled omentum (omentoplasty), and two external tube drainage (two mushroom drains) were placed at the subhepatic and subdiaphragmatic area for cavity obliteration.

Representative tissue sample associated with liver hydatid cyst was collected and preserved in 10% formalin. The fixed tissue samples were processed by routine paraffin embedding technique, and tissue sections were stained using the H&E method. Assessing the slides revealed parasitic membranes (laminated membranes and germinal layers), brood capsules with protoscolices.

There was no bile fistula. The first patient's tube drainage was removed on the postoperative Day 4, and the second one on Day 7 after surgery. His postoperative course was uneventful and the patient was discharged on the eighth day after the surgery with Albendazole (400 mg twice a day) for six months to reduce recurrence. The patient was followed and visited one week and one month after the operation, and there were good results without any complications.

Discussion

The largest liver hydatid cyst ever seen was a 45 cm cyst in the left hepatic lobe (LHL) of a man from India. The second largest one was a 37 cm cyst in a woman from India who underwent PAIR. The 3rd rank was for a 35 cm cyst in a woman from Turkey. The 4th one was a 30 cm cyst in an Egyptian man, and finally, the 5th rank is for our case in whom a

24 cm cyst was seen in a 17-year-old man. Table 1 shows the information on all of the reported giant liver hydatid cases in the literature.

The most common countries where the largest liver hydatid cysts were reported were Greece and Turkey. The oldest and the youngest patients were a 77-year-old woman from Greece, and an 8-year-old boy from Nepal, respectively. The male-to-female ratio according to the giant size of the cyst was 1:1. The most common affected lobe was RHL seen in 12 (75.0%) patients. There were six (37.5%) patients with LHL involvement. The most common surgery was the open surgery and the most common incisions were Kocher and then Chevron incisions. PAIR and laparoscopy were done in one patient each, respectively (16, 21).

During different stages of hydatid disease, the variation in the serum level of specific IgG, IgM, and IgA antibodies has been demonstrated. Specific IgG antibodies are present in patients with either current or past infections. IgM antibodies, detected during periods of antigenic activity, disappear soon after removal of the cyst. In many cases, IgA antibodies also disappear soon after removal of the cyst (25).

Indications and contraindications for the laparoscopic technique for hydatid cyst surgery are summarized in Table 2 (23, 26). In huge liver hydatid cysts, because of the location and size of the cysts, it is too difficult to access through the laparoscopic technique, and the risk of trans-diaphragmatic rupture into the lungs during manipulation could result in sudden breathlessness and intraoperative anaphylaxis. Moreover, laparoscopy is associated with higher risks of fluid spillage and subsequent recurrence (23), so it is contraindicated in a huge cyst larger than 15 cm (23, 26).

Minimally invasive methods have also been described such as PAIR and PEVAC. Indications and contraindications of minimally invasive methods are summarized in Table 3 (26, 27). In using minimally invasive methods, the increased risk of secondary hydatidosis requires careful monitoring by postoperative serological and imaging tests (26, 27). As is seen, the huge size of the cyst is not a

Table 1: Summarized information on the reported giant liver hydatid cases in the literature

	Author	Country	Year	Age (years)	Sex	Size (cm)	Location	Type of surgery	Surgical approach
1	Sahin et al (15)	Turkey	2005	19	♀	35×15	RHL	Open	NA
2	Battyány et al (16)	Hungary	2006	35	♀	37×15	RHL	PAIR	—
3	Ezer et al (9)	Turkey	2007	19	♂	16	RHL	Open	NA
4	Salemis (17)	Greece	2008	55	♀	16	LHL	Open	Kocher
5	Barbosa et al (18)	USA	2008	66	♀	14	RHL	Open	Kocher
6	Duttaroy (4)	India	2008	60	♂	19×13	RHL	Open	Upper midline
7	Gole et al (10)	India	2011	60	♂	45×35	LHL	Open	NA
8	Krokos et al (5)	Greece	2011	77	♀	21.5×21	LHL	Open	Kocher
9	Ettorre et al (19)	Egypt	2012	55	♂	30×18	RHL	Open	Mercedes Benz
10	Cuzic et al (20)	Romania	2013	12	♂	23×21	RHL	Open	NA
11	Turk et al (11)	Turkey	2015	60	♀	11.5×9	RHL, LHL	Open	NA
12	Stanciu et al (21)	Romania	2017	28	♀	10.2×6.8	RHL	Laparoscopy	—
13	Syllaios et al (22)	Greece	2019	70	♂	21×14	RHL	Open	Kocher
14	Shrestha et al (23)	Nepal	2020	8	♂	>10	RHL, LHL	Open	NA
15	Pavlidis et al (24)	Greece	2021	39	♀	17×11	LHL	Open	Chevron
16	Izadpanah et al (Our study)	Iran	2021	17	♂	24×20	RHL	Open	Chevron

Table 2: Indications and contraindications for the laparoscopic technique for hydatid cyst surgery

Indications	Contraindications
Superficial smaller cysts (<6cm) over the anterior surface of the liver	Cyst rupture in the biliary tree
Cysts without biliary communication	Central cyst localization
Cysts ≤3 in number	Cystic dimensions over 15 cm
	Thickened or calcified cystic walls

Table 3: Indications and contraindications of minimally invasive methods (PAIR and PEVAC)

Indications	Contraindications
Applicable to the hepatic hydatid cyst in stages CE1, CE2, CE3	Non-cooperative patients
Cyst with daughter vesicles +/-	Cysts that cannot be punctured
Detached proligere membrane	Inactive/calcified cysts
Multiple cysts if accessible to puncture	Cysts that communicate with the biliary tree
Superinfected cyst	
Patients refusing surgery	
Patients with surgical contraindications	
Post-surgical relapse	
Patients not responding to drug therapy	
Pregnancy	

contraindication using these methods.

In general, the preferred choice of treatment for huge liver hydatid cysts with giant dimensions, unusual locations, with multiple lesions, in children, is the open approach (22, 24). In our study similar to other studies mentioned in Table 1, we chose an open technique over other procedures. The advantages of the open approach are cyst cavity obliteration using various techniques such as omentoplasty or cyst capitonnage as well as better management of bleeding and spillage of cyst content (22, 24).

The main limitation of this study was the major weakness of all retrospective studies generating a great deal of missed data. As with any retrospective study, the investigator depends on the availability and accuracy of the medical record.

Conclusion

When dealing with a huge liver cyst, a high index of suspicion for echinococcal etiology becomes important in endemic areas such as Iran. These giant hepatic cysts need radical surgery by surgical ablation in general because they are at risk of rupture, anaphylaxis, and so forth. In addition, antihelmintic drugs are advised as an adjacent therapy to surgery to prevent a recurrence. The preferred surgical approach depends upon the cyst dimension, location, and complication, however in our patient, we chose to do the open surgery, and the patient was discharged with Albendazole (400 mg twice a day) for six months to reduce recurrence.

Ethics Approval and Consent to Participate

The project received the ethical approval code, IR.SUMS.MED.REC.1399.327, from the Shiraz University of Medical Sciences Research Vice-Chancellor. The patient data was obtained from hospital records without any intervention on patient by the research groups. The details of the subject were protected by confidentiality measures. Written informed consent was obtained from the patient for participation. A copy of the written consent is available for review by the Editor-in-Chief of this journal.

Consent for Publication

Written informed consent was obtained from the patient for publication of this case report and any accompanying images. A copy of the written consent is available for review by the Editor-in-Chief of this journal.

Availability of Data and Materials

The datasets used and/or analyzed during the current

study are available from the corresponding author at reasonable request.

Acknowledgment

We all express our gratitude to the patient who kindly gave consent for this case to be presented in this paper.

Authors' Contribution

AMB supervised the manuscript preparation and revised it. GA, CI, QA, and EA read and revised the paper. AI was the main surgeon who operated on the patient. MJYB prepared the first draft and revised the paper. All authors read and approved the final manuscript and agreed to be accountable for all aspects of the work in ensuring that questions related to the accuracy or integrity of any part of the work are appropriately investigated and resolved.

Conflict of interest: None declared.

References

- Mahmoudi S, Mamishi S, Banar M, Pourakbari B, Keshavarz H. Epidemiology of *echinococcosis* in Iran: a systematic review and meta-analysis. *BMC Infect Dis*. 2019 Nov 4;19(1):929. <https://doi.org/10.1186/s12879-019-4458-5>
- Grosso G, Gruttadauria S, Biondi A, Marventano S, Mistretta A. Worldwide epidemiology of liver hydatidosis including the Mediterranean area. *World J Gastroenterol*. 2012 Apr 7;18(13):1425-37. <https://doi.org/10.3748/wjg.v18.i13.1425>
- Fasihi Harandi M, Budke CM, Rostami S. The monetary burden of cystic *echinococcosis* in Iran. *PLoS Negl Trop Dis*. 2012;6(11):e1915. <https://doi.org/10.1371/journal.pntd.0001915>
- Duttaroy DD, Kacheriwala S, Duttaroy B, Jagtap J, Patel G, Modi N. Giant hepatic hydatid cyst with sub-fascial extension treated by open minimally invasive surgery: a case report. *J Med Case Rep*. 2008 Jan 28;2:26. <https://doi.org/10.1186/1752-1947-2-26>
- Krokos N, Mihailidou E, Margioulas A, Karakatsanis A, Drizis T. A giant hydatid cyst of the liver. *Hellenic J Surg*. 2011; 83: 102–106. <https://doi.org/10.1007/s13126-011-0019-0>
- Khanfar N. Hydatid disease: a review and update. *Current Anaesthesia & Critical Care*. 2004; 15 (3):173-183. <https://doi.org/10.1016/j.cacc.2004.06.002>
- Acar F, Sahin M, Alptekin H, Yilmaz H, Kafalı ME. Surgical treatment of giant liver hydatid cysts: comparison of cystojejunostomy and partial cystectomy. *Surg Today*. 2014 Nov;44(11):2065-71. <https://doi.org/10.1007/s00595-014-0887-3>
- Acharya H, Agrawal V, Tiwari A, Sharma D. Single-incision trocarless endoscopic management of giant liver hydatid cyst in children. *J Minim Access Surg*. 2018 Apr-Jun;14(2):130-133. https://doi.org/10.4103/jmas.JMAS_42_17
- Ezer A, Nursal TZ, Noyan T, Moray G. Giant hepatic hydatid cyst: a case report. *World J Gastroenterol*. 2007 Apr 28;13(16):2388-9. <https://doi.org/10.3748/wjg.v13.i16.2388>
- Gole GN, Tati SY, Bashetty S, Somani S. Pedunculated giant hepatic hydatid cyst: Largest ever reported. *Trop Parasitol*. 2011 Jul;1(2):132-4. <https://doi.org/10.4103/2229-5070.86966>
- Turk O, Polat H, Badak B (2015) Primary Multiple Giant Hydatid Cyst of the Liver: A Case Report. *J Surg Surgical Res* 1(3): 075-077. <https://doi.org/10.17352/2454-2968.000018>
- Dahniya MH, Hanna RM, Ashebu S, Muhtaseb SA, el-Beltagi A, Badr S, el-Saghir E. The imaging appearances of hydatid disease at some unusual sites. *Br J Radiol*. 2001 Mar;74(879):283-9. <https://doi.org/10.1259/bjr.74.879.740283>
- Tetik O, Yilik L, Emrecan B, Ozbek C, Gurbuz A. Giant hydatid cyst in the interventricular septum of a pregnant woman. *Tex Heart Inst J*. 2002;29(4):333-5.
- Botrugno I, Gruttadauria S, Li Petri S, Cintorino D, Spada M, Di Francesco F, Pagano D, Crino F, Anastasi D, Gridelli B. Complex hydatid cysts of the liver: a single center's evolving approach to surgical treatment. *Am Surg*. 2010 Sep;76(9):1011-5.
- Sahin DA, Kusaslan R, Sahin O, Dilek ON. Huge hydatid cysts that arise from the liver, growing exophytically. *Can J Surg*. 2007 Aug;50(4):301-3.
- Battyány I, Herbert Z, Rostás T, Vincze A, Fülöp A, Harmat Z, Gasztonyi B. Successful percutaneous drainage of a giant hydatid cyst in the liver. *World J Gastroenterol*. 2006 Feb 7;12(5):812-4. <https://doi.org/10.3748/wjg.v12.i5.812>
- Salemis NS. Giant hydatid liver cyst. Management of residual cavity. *Ann Hepatol*. 2008 Apr-Jun;7(2):174-6.
- Barbosa R, Mahmoud A, Matolo N, Kapre S. Giant Hydatid Cystic Liver Disease: A Challenging Problem for Western Surgeons. *Surgical Rounds*. 2006 May; 0 (0). https://www.hcplive.com/view/2006-05_02
- Ettorre GM, Vennarecci G, Santoro R, Laurenzi A, Ceribelli C, Di Cintio A, Rizzi EB, Antonini M. Giant hydatid cyst of the liver with a retroperitoneal growth: a case report. *J Med Case Rep*. 2012 Sep 13; 6:298. <https://doi.org/10.1186/1752-1947-6-298>
- Cuzic V, Tica C, Enache F, Mihai C, Bălășa A, Mihai L, Frecuș C, Ungureanu A. Giant Liver Hydatid Cyst. *ARS Medica Tomitana*.

- 2012;18(1): 50-53. <https://doi.org/10.2478/v10307-012-0010-1>
21. Stanciulea O, Eftimie MA, Mosteanu I, Tirca L, Popescu I. Primary Giant Splenic and Hepatic Echinococcal Cysts Treated by Laparoscopy. *J Minim Invasive Surg* 2017; 20(4): 155-159 <https://doi.org/10.7602/jmis.2017.20.4.155>
22. Syllaios A, Schizas D, Koutras A, Zotos PA, Davakis S, Vailas M, Hasemaki N, Triantafyllou E, Georgiou C. Abdominal pain caused by a giant liver hydatid cyst and the management of the residual cavity in a tertiary public hospital in Greece. *Pan Afr Med J*. 2019 Sep 4;34:11. <https://doi.org/10.11604/pamj.2019.34.11.17198>
23. Shrestha AL, Paudel SB, Malla SK. Multiple Giant Liver Cysts in a Nepalese Lad. *Case Rep Pediatr*. 2020 Aug 29;2020:6196252. <https://doi.org/10.1155/2020/6196252>
24. Pavlidis ET, Symeonidis NG, Psarras KK, Martzivanou EK, Marneri AG, Stavrati KE, Pavlidis TE. Total cystopericystectomy for huge echinococcal cyst located on hepatic segment IVb. Case report and review of the literature. *J Surg Case Rep*. 2021 Jan 31;2021(1): rjab002. <https://doi.org/10.1093/jscr/rjab002>
25. Matossian RM, Kane GJ, Chantler SM, Batty I, Sarhadian H. The specific immunoglobulin in hydatid disease. *Immunology*. 1972 Mar;22(3):423-30.
26. Botezatu C, Mastalier B, Patrascu T. Hepatic hydatid cyst - diagnose and treatment algorithm. *J Med Life*. 2018 Jul-Sep;11(3):203-209. <https://doi.org/10.25122/jml-2018-0045>
27. WHO/CDS/CSR/APH/2001.6: PAIR. Puncture, Aspiration, Injection, Re-Aspiration an options for the treatment of cystic *echinococcosis*. *Bull World Health Organization*. 2001: 1-44.