


Iranian Journal of Colorectal Research



Pathological Review of Resected Gastric Specimens Following Laparoscopic Sleeve Gastrectomy Over Four Years at Two Major Referral Hospitals in Shiraz, Iran

Faranak Bahrami¹, MD;  Arian Najdi¹, MD; Khadijeh Gorgi¹, MD; Mohammed Abd-zaid Akool², MD; Hajar Khazraei^{1*}, MD 

¹Colorectal Research Center, Shiraz University of Medical Sciences, Shiraz, Iran

²Department of Surgery, Faculty of Medicine, Jabir Ibn Hayyan Medical University, Najaf, Iraq

*Corresponding authors:

Hajar Khazraei,
Colorectal Research Center, Shiraz University of Medical Sciences, Shiraz, Iran.
Tel: +98 71 36281453;
Email: hajarkhazraei@gmail.com

Received: 2023-05-01
Revised: 2023-05-03
Accepted: 2023-06-07

Abstract

Background: Bariatric surgery is the most effective treatment for morbid obesity, resulting in long-term weight loss and considerable improvements in coexisting conditions. We conducted a histopathologic evaluation of resected stomach specimens after laparoscopic sleeve gastrectomy.

Methods: We evaluated the medical records of 827 patients who underwent laparoscopic sleeve gastrectomy between 2015 and 2018 at two major refer hospitals in Shiraz, Iran. In this retrospective cross-sectional study, the pathological findings of resected stomach specimens and other variables such as age, sex, preoperative body mass index (BMI), and comorbid illnesses were evaluated.

Results: Six hundred and fifty-three cases (78.9%) had chronic gastritis in some form; lymphoid follicle formation (in 197 cases), acute on chronic gastritis (in 67 cases), complete intestinal metaplasia (in 5 cases), hyperplastic polyps (in 5 cases), and gastrointestinal stromal tumors (GISTs) (2 cases) were the next most common findings. Most lymphoid follicle formation was reported in the context of gastritis. Two patients with GIST and one with submucosal lymphoma received further treatment.

Conclusion: Abnormal histopathologic findings were found in 88% of sleeve gastrectomy specimens. While almost no malignancies were found, less than 15% of samples were completely normal. Because of the high rate of abnormal pathologies in the resected gastric specimens and since gastric cancer is the most common gastrointestinal malignancy in Iran, we recommend that all patients in our region who are candidates for sleeve gastrectomy undergo an upper gastrointestinal endoscopy before surgery.

Keywords: Laparoscopy, sleeve gastrectomy, pathology, GIST

Please cite this paper as:

Bahrami F, Najdi A, Gorgi K, Abd-zaid Akool M, Khazraei H. Pathological Review of Resected Gastric Specimens Following Laparoscopic Sleeve Gastrectomy Over Four Years at Two Major Referral Hospitals in Shiraz, Iran. *Iran J Colorectal Res.* 2023;11(2):68-72. doi: 10.30476/ACRR.2023.99280.1180.

Introduction

Obesity is a worldwide medical and social problem. Bariatric surgery is the most effective treatment for morbid obesity, resulting in long-term weight loss and significant improvements in concomitant diseases such as hypertension, diabetes, and obstructive sleep apnea, eventuating in a reduced mortality rate (1, 2). According to the World Health Organization, the number of bariatric procedures performed on adults has doubled in the last decade worldwide (3).

The Roux-en-Y operation is currently the most popular gastric bypass procedure, accounting for around half of all bariatric surgeries, followed by laparoscopic sleeve gastrectomy (LSG) and adjustable gastric banding (AGB). Sleeve gastrectomy (SG) is a relatively new but popular bariatric surgery that grew fourfold in popularity between 2008 and 2011. It is currently the world's second most prevalent bariatric surgery (3). The criteria and patient selection for SG are identical to other obesity and metabolic surgeries: body mass index (BMI) ≥ 40 kg/m² or BMI ≥ 35 kg/m² with other related medical conditions.

Many centers and surgeons transmit resected gastric tissue for full pathological examination after an LSG. These situations, however, differ from one center to the next and from one surgeon to another. The cost of a comprehensive pathological investigation of LSG specimens is difficult to quantify, ranging between \$500 and \$1,500 per specimen in the United States. It is believed that 2% of laparoscopic surgeries reveal unexpected pathologies.

In this study, we wished to determine what we should expect to encounter in a histopathology evaluation of a resected stomach after LSG in our referral centers.

Patients and Methods

This study evaluated the medical records of

patients who underwent LSG due to morbid obesity at Shiraz's Ghadir Mother and Child Hospital or Shahid Faghihi Hospital (two major referral centers in Shiraz, Iran) between 2015 and 2018. These individuals filled either of the mentioned criteria that necessitate bariatric surgery. Initially, 895 patients were included; however, 68 patients were excluded due to missing data.

In this retrospective cross-sectional study, age, sex, preoperative BMI, and concomitant conditions were investigated in addition to the pathological evaluation of resected stomach specimens. Gallbladder pathology reports were also added if cholecystectomy was performed during the main procedure.

Data from 827 patients were analyzed in SPSS software version 18. Q² test was used to compare pathological findings between age and BMI groups. The study was approved by the Ethics Committee of Shiraz University of Medical Sciences (IR.SUMS.REC.1396.S968).

Results

This study involved data from 827 patients who had undergone LSG, including 171 (20.7%) men and 656 (77.3%) women. The mean age was 36.59 (12-70) years. The highest BMI was 65.8 kg/m², with an overall average of 43.69 kg/m².

Except for one case of submucosal lymphoma, no other malignancy was seen in the removed gastric samples. Six hundred and fifty-three cases (78.9%) had chronic gastritis in some form, representing the most common pathological finding. Other pathological findings included lymphoid follicle formation (in 197 cases), acute on chronic gastritis (in 67 cases), complete intestinal metaplasia (in 5 cases), hyperplastic polyps (in 5 cases), and gastrointestinal stromal tumors (GISTs) (2 cases) (Figure 1).

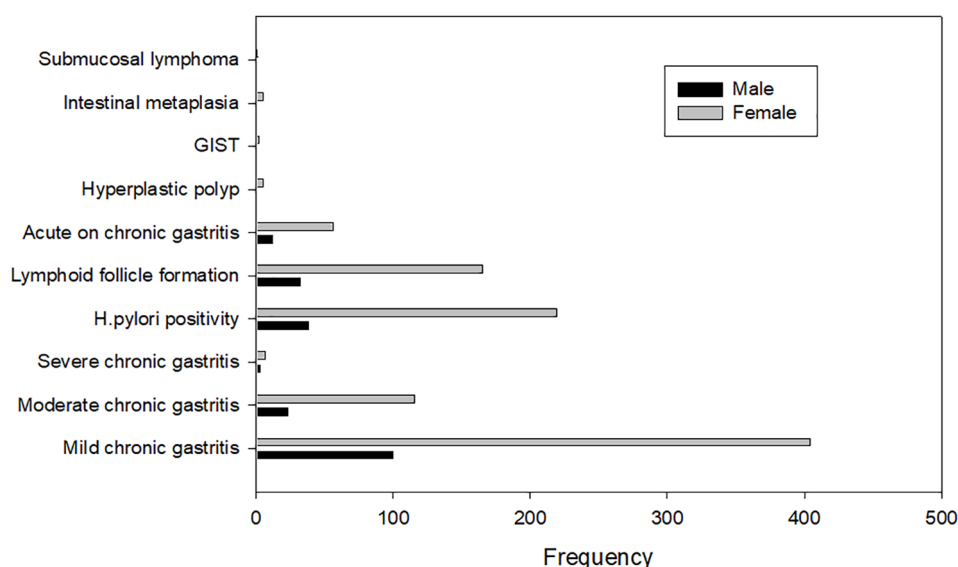


Figure 1: Frequency of pathological findings in resected specimens following laparoscopic sleeve gastrectomy. GIST: gastrointestinal stromal tumor.

Three hundred and forty patients (41.1%) had significant comorbidities, including 67 males (39.1%) and 273 females (41.6%). Among the diseases, diabetes, hypertension, thyroid disorders, and respiratory problems were the most common (Table 1).

Most lymphoid follicle formation was reported in the context of gastritis. *Helicobacter pylori* was present in 257 (31%) of the specimens. Two patients with GIST and one with submucosal lymphoma received further treatment.

Fifty-eight patients (7%) underwent cholecystectomy concomitantly with the main procedure. Fifty-three gall bladder specimens (91.3%) showed evidence of chronic cholecystitis.

Significant differences were recorded between the different age groups regarding the rates of acute on chronic gastritis ($P<0.001$) and *H. pylori* positivity ($P=0.001$) (Figure 2).

The frequency of pathological findings in the different BMI groups is depicted in Figure 3.

Discussion

We studied the medical and histopathological records of 827 patients who underwent laparoscopic sleeve gastrectomy (LSG) between 2015 and 2018 at two major referral centers in Shiraz, Iran. Other than

lymphoid follicle formation, the rate of abnormal histopathologic findings of resected stomachs was about 88%. Although almost no malignancies were recorded, less than 15% of samples were entirely normal.

A 2017 cohort study by Hansen et al. (4) on resected gastric samples following LSG in 351 patients showed that 28.2% had gastritis or inflammation (as the most common finding), while 2.6% were positive for *H. pylori*. None of the samples had evidence of malignancy or conditions requiring immediate intervention. Hence, the authors suggested that a routine pathological evaluation of gastric specimens following LSG is not required (4). Clapp et al. reported that 45% of their samples had abnormal pathological findings, and 19% had evidence of *H. pylori* infection (5). Almazeedi et al. reported in 2012 that the rate of chronic gastritis in their study was 74.4%, and the rate of *H. pylori* infection was 7.3% (6).

In a 2015 prospective study by Clapp et al. on 145 patients who underwent LSG at a center over a period of 3 years, 49.7% of patients had positive histopathologic findings in the resected specimens. The most important of these findings were acute on chronic gastritis in 4 patients (2.7%), chronic gastritis in 61 patients (42.1%), and follicular lymphoid hyperplasia in 11 patients (7.6%). One case

Table 1: The prevalence of comorbidities in the study participants

| | DM | HLP | HTN | Thyroid* | Biliary | GI ** | Respiratory *** | Skeletal | Other **** |
|---|-------|------|-------|----------|---------|-------|-----------------|----------|------------|
| N | 92 | 24 | 109 | 101 | 56 | 25 | 59 | 6 | 29 |
| % | 11.1% | 2.9% | 13.2% | 12.2% | 6.8% | 3% | 7.1% | 0.7% | 3.5% |

DM: diabetes mellitus; HLP: hyperlipidemia; HTN: hypertension. GI: gastrointestinal; *Thyroid disorders included both hyperthyroidism and hypothyroidism. **GI disorders included dyspepsia, reflux, and peptic ulcer disease. ***Respiratory disorders included asthma, obstructive sleep apnea, chronic obstructive pulmonary disease, and allergies. ****Other diseases included a history of ischemic heart disease, breast cancer, cerebrovascular accident, hepatitis, anemia, renal stone, polycystic ovarian syndrome, deep vein thrombosis, and psychiatric conditions.

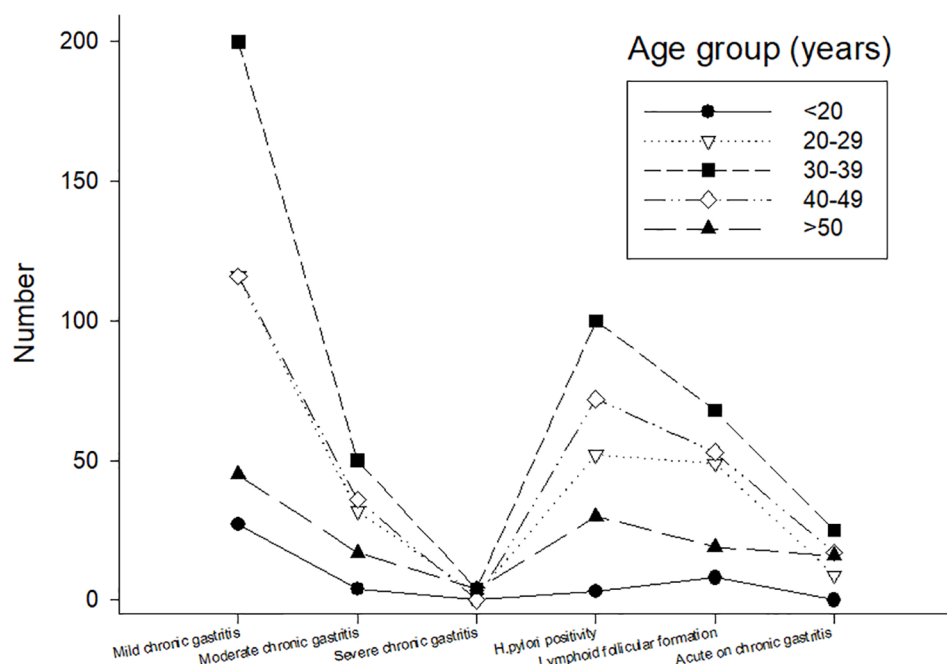


Figure 2: Frequency of pathological findings in different age groups. Significant differences were recorded between the age groups regarding the rates of acute on chronic gastritis ($P<0.001$) and *Helicobacter pylori* positivity ($P=0.001$).

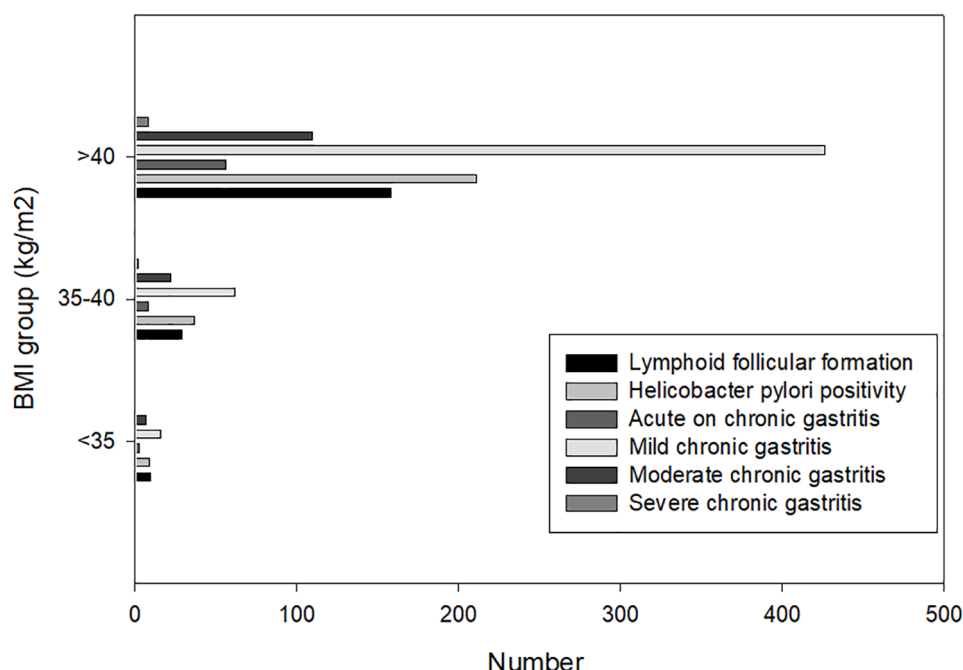


Figure 3: The frequency of pathological findings in different body mass index (BMI) groups.

of leiomyoma and two cases of fundal polyp were also reported. Seventy-three patients (50.3%) did not have histopathological changes (5)

In our study, evaluation of the resected gastric specimens of 827 patients after LSG revealed that 653 patients had chronic gastritis (79%) and 67 patients (8.1%) had acute on chronic gastritis, representing the most common findings. Two cases of GIST were observed by chance, one of which was associated with complete intestinal metaplasia. Five cases had a hyperplastic polyp, and five others had complete intestinal metaplasia; one was multifocal. One case of submucosal leiomyoma was recorded, and 23.7% of patients showed lymphoid follicle formation. Just 21% of patients had no pathological changes. More than in previous studies, almost a third (31.1%) of our patients had an *H. pylori* infection. Among 58 patients (7%) who underwent a simultaneous cholecystectomy, 51 (87.9%) had chronic cholecystitis, while the others (5%) had acute on chronic cholecystitis.

Gastric cancer, with an annual incidence of 7300, is among the five most common cancers in Iranian men and women (7). It is the first cause of cancer death in both genders in Iran, as most patients are diagnosed at advanced stages of the disease (8). Also, the five-year survival rate in Iran is estimated at less than 25% (9). On the other hand, over 80% of the Iranian population over 40 years have a history of *H. pylori* infection (10, 11). *H. pylori* is the most prominent risk factor for gastric cancer (12). One study reported that people with *H. pylori* infection have an 18% higher chance of developing gastric cancer than those without this infection (OR=18.58; CI=1.63–221.520) (13). The significant prevalence of gastritis and *H. pylori* infection (as potential precursors of gastric cancer) in the present article compared to similar studies is completely consistent

with the high incidence of stomach cancer in our country.

Because of the high rate of abnormal pathology in resected gastric specimens in this trial and the fact that gastric cancer is the most common gastrointestinal malignancy in Iran, it is recommended that all patients in our region who are candidates for LSG undergo an upper GI endoscopy before surgery. Furthermore, follow-ups should be scheduled in the postoperative period if necessary.

Conclusion

The prevalence rates of gastritis (chronic or acute) and *H. pylori* infection, as potential precursors of gastric cancer, were higher than in similar research in other regions, consistent with the high incidence of stomach cancer in Iran. Hence, performing upper GI endoscopy before LSG and sending all postoperative specimens for histopathological examination is beneficial in our region.

Ethics Approval

The study was approved by the Ethics Committee of Shiraz University of Medical Sciences (IR.SUMS.REC.1396.S968).

Authors' Contribution

FB, AN, MAA: substantial contributions to conception and design, acquisition of data, or analysis and interpretation of data; KG, AN, FB, and HK: data interpretation and drafting the article or revising it critically for important intellectual content; all authors approved the final version.

Conflict of interest: None declared.

References

1. Chang SH, Stoll CR, Song J, Varela JE, Eagon CJ, Colditz GA. The effectiveness and risks of bariatric surgery: an updated systematic review and meta-analysis, 2003-2012. *JAMA surgery*. 2014;149(3):275-87.
2. Sjöström L, Peltonen M, Jacobson P, Sjöström CD, Karason K, Wedel H, et al. Bariatric surgery and long-term cardiovascular events. *Jama*. 2012;307(1):56-65.
3. Buchwald H, Oien DM. Metabolic/ bariatric surgery worldwide 2011. *Obesity surgery*. 2013;23(4):427-36.
4. Hansen SK, Pottorf BJ, Hollis HW, Jr., Rogers JL, Husain FA. Is it necessary to perform full pathologic review of all gastric remnants following sleeve gastrectomy? *American journal of surgery*. 2017;214(6):1151-5.
5. Clapp B. Histopathologic findings in the resected specimen of a sleeve gastrectomy. *JSLS : Journal of the Society of Laparoendoscopic Surgeons*. 2015;19(1):e2013.00259.
6. Almazeedi S, Al-Sabah S, Al-Mulla A, Al-Murad A, Al-Mossawi A, Al-Enezi K, et al. Gastric histopathologies in patients undergoing laparoscopic sleeve gastrectomies. *Obesity surgery*. 2013;23(3):314-9.
7. Dehdari T, Dehdari L, Jazayeri S. Diet-Related Stomach Cancer Behavior Among Iranian College Students: A Text Messaging Intervention. *Asian Pacific journal of cancer prevention : APJCP*. 2016;17(12):5165-72.
8. Akhavan A, Binesh F, Seifaddiny A. Results of combination chemotherapy and radiation therapy in non-metastatic gastric cancer in Yazd-Iran. *Indian journal of cancer*. 2015;52(1):40-3.
9. Movahedi M, Afsharfard A, Moradi A, Nasermoaddeli A, Khoshnevis J, Fattahi F, et al. Survival rate of gastric cancer in Iran. *Journal of research in medical sciences : the official journal of Isfahan University of Medical Sciences*. 2009;14(6):367-73.
10. Zendehtel N, Nasser-Moghaddam S, Malekzadeh R, Massarrat S, Sotoudeh M, Siavoshi F. *Helicobacter pylori* reinfection rate 3 years after successful eradication. *Journal of gastroenterology and hepatology*. 2005;20(3):401-4.
11. Keramati MR, Sadeghian MH, Ayatollahi H, Badice Z, Shakibayi H, Moghimi-Roudi A. Role of the Lewis and ABO Blood Group Antigens in *Helicobacter pylori* Infection. *The Malaysian journal of medical sciences : MJMS*. 2012;19(3):17-21.
12. Compare D, Rocco A, Nardone G. Risk factors in gastric cancer. *European review for medical and pharmacological sciences*. 2010;14(4):302-8.
13. Kalan Farmanfarma K, Mahdavi N, Hassanipour S, Salehiniya H. Epidemiologic Study of Gastric Cancer in Iran: A Systematic Review. *Clinical and experimental gastroenterology*. 2020;13:511-42.