



## Isolated Adrenal Gland Hemorrhage: A Case of a Car Accident

Hossein Abdolrahimzadeh Fard<sup>1</sup>, Soheil Bolandi<sup>1\*</sup>, Zahra Mohammadi<sup>1</sup>

<sup>1</sup>Trauma Research Center, Rajaei (Emtiaz) Trauma Hospital, Shiraz University of Medical Sciences, Shiraz, Iran

\*Corresponding author: Soheil Bolandi

Address: Trauma Research Centre, 6<sup>th</sup> Floor, Rajaei (Emtiaz) Hospital, Chamran Blvd., Shiraz, Iran.

e-mail: soheil.bolandi@yahoo.com

Received: May 20, 2023

Revised: June 28, 2023

Accepted: July 3, 2023

### ► ABSTRACT

Due to the specific features of the adrenal glands, traumatic adrenal injury is a rare phenomenon. The majority of these rare types of traumas are caused by blunt force injuries and rarely by penetrating mechanisms. In such cases, a whole-body computed tomography scan is essential for early diagnosis. This paper describes an uncommon case of adrenal hematoma and contusion followed by blunt abdominal trauma. A 35-year-old woman was admitted to the emergency department after a high-speed vehicle-pedestrian collision. She presented with decreasing level of consciousness. Additionally, a thoracoabdominal CT scan revealed a left flank hematoma. Blunt adrenal injury, often accompanied by multiorgan damage, is a rare occurrence resulting from severe accidents. Accurate diagnosis based on clinical symptoms requires high clinical suspicion, particularly in isolated cases, and treatment depends on the patient's condition.

**Keywords:** Adrenal gland injury; Trauma; Adrenal hematoma.

Please cite this paper as:

Abdolrahimzadeh Fard H, Bolandi S, Mohammadi Z. Isolated Adrenal Gland Hemorrhage: A Case of a Car Accident. *Bull Emerg Trauma*. 2023;11(3):162-165. doi: 10.30476/BEAT.2023.98940.1446.

### Introduction

Adrenal gland injury (AGI) is a rare condition often associated with high or low blunt torso trauma. It is frequently overlooked and difficult to diagnose, particularly when it is isolated [1]. Isolated AGIs occur in about 1.5 to 4% of all adrenal trauma cases [2]. Before the advent of computed tomography (CT), AGIs were primarily detected during post-mortem examinations and were mostly associated with severe injuries [3]. Adrenal hematoma (AH) accounts for 1.9% of trauma patients who underwent CT, or 0.8% of all patients who enter the trauma registry [4]. Adrenals are paired retroperitoneal ductless glands

located in the superomedial of kidneys on the level of the 11<sup>th</sup> ribs. Adrenal veins can exhibit various anatomical variations while being very small in size (with an average length of less than 5 cm and a weight of about 4 g). Surgeons who perform adrenalectomies need to be aware of these variants. Clinically, the most common anatomical variants are those with one central vein draining each adrenal gland. The inferior phrenic vein and the left renal vein are the first and second destinations of the long left adrenal vein, while the short right adrenal vein runs straightly into the Inferior Vena Cava (IVC) [5, 6]. There are no specific signs or symptoms related to blunt adrenal gland trauma. It is an asymptomatic injury that is

simply left undiagnosed; however, blunt adrenal gland trauma may lead to persistent hemorrhage, retroperitoneal hematoma, abscesses, and lethal adrenal crisis [7]. This case report describes an uncommon case of isolated AGI following blunt abdominal trauma in Iran.

### Case Presentation

A 35-year-old Caucasian woman was admitted to the Emergency Department after a high-speed vehicle-pedestrian collision with decreasing level of consciousness (LOC). Initially, the patient's vital signs were as followed: Blood pressure: 96/91 mmHg, heart rate: 96bpm, peripheral oxygen saturation (SpO<sub>2</sub>): 97%, Temperature 36.8 °C, and Glasgow Coma Scale (GCS): 3/15 without any sort of sedative medication. She was intubated by emergency medical technicians at the accident scene with no signs of external bleeding, impaired breathing, ecchymosis, and lacerations on her body. Only some superficial abrasions were visible on her left elbow and her left lower abdomen quadrant.

No abnormalities were found in her blood analysis, metabolic panel, coagulation panel, or urinalysis, which showed no signs of microscopic hematuria. Plain radiographs of the chest, spine, and pelvis were all normal. There was no evidence of contours or fluid on the abdominal-focused assessment sonography for trauma (AFAST). Due to the persistent hypotension, high-force trauma, and decreased LOC, an abdominal Contrast-enhanced computed tomography (CE-CT) scan with the suspension of AGI was performed. The findings revealed a round shape enlargement of the left adrenal (51×68 mm) and linear shape lesion (58×61mm) with increased density (60-70HU), as well as the left diaphragmatic crus thickening with extravasation of the intravascular contrast in the portal phase from the left superior adrenal vein. No injuries or abnormalities were found in other organs, particularly solid organs, as well as the brain CT scan. Therefore, an isolated adrenal hematoma (AH) was diagnosed (Figure 1).

She was admitted to the Intensive Care Unit (ICU) after receiving a blood transfusion and fluid resuscitation. For the first six hours in the ICU, her vital signs remained stable. However, her condition

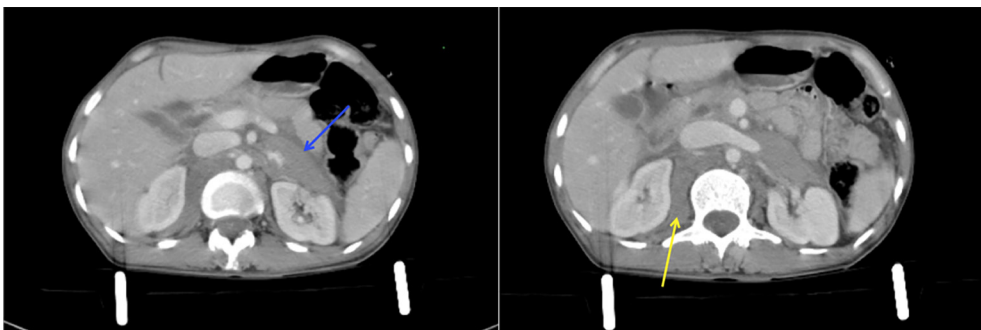
gradually deteriorated, developing into hypotension and tachycardia. Consequently, she was transferred to the operating room. Following resuscitation, a mid-line incision was made to explore the abdomen. A non-expanding hematoma in the left retroperitoneal area was detected. Then, the left medial visceral rotation hematoma was explored, and the injured left suprarenal vein (left adrenal vein) was ligated. Then, hemostasis and irrigation were performed. Finally, the abdomen was closed layer by layer, and the patient was transferred to ICU with stable vital signs. The patient was hospitalized in ICU for one week. During her ICU stay, her LOC gradually increased. A CT scan of the brain indicated no abnormalities such as epidural or subdural hematoma. As a result, according to our neurologist consultant, a decrease in her level of consciousness was justified by undetectable diffused axonal injury (DAI) on a brain CT scan. She was discharged on oral antibiotics and analgesia.

The patient did not present any new symptoms, and the laboratory data including CBC, BUN, Cr, Urinalysis, VBG, and adrenocorticotrophic hormone (ACTH) stimulation test, were all normal.

### Discussion

In a normal healthy adult, each adrenal gland weighs about 4–5 g, which are located just below the crura of the diaphragm and capped the superomedial pole of each kidney. Despite being small, the adrenal glands are highly vascular, with an estimated flow rate of about 5 mL per minute. Each adrenal gland is supplied by three critical arteries and up to fifty arterial branches. The superior, middle, and inferior suprarenal arteries are the three main arteries. Blood is directed into the adrenal cortex and drains into the adrenal medulla before entering the IVC via the central vein to the right adrenal [8, 9].

The right adrenal is connected to the IVC and right lobe of the liver. From the lateral retroperitoneal view, it is located in front of the 12<sup>th</sup> rib with a pyramid shape and more posteriorly than the left. The pancreas and spleen surround the crescent-shaped left adrenal, which is located in front of the 11<sup>th</sup> and 12<sup>th</sup> ribs. Disregarding the various sizes and depths of adipose subcutaneous tissue, the adrenals are located in the middle of the abdominal cavity [10, 11].



**Fig. 1.** Round shape, well-defined lesion (51×68 mm) with high density (blue arrow) at the left anterior pararenal space and a linear shape lesion (58×61 mm) located at the right posterior perirenal space (yellow arrow) are illustrated, which is indicative of acute hematoma and attributed to devascularization of left superior adrenal vein. No periadrenal fat stranding is noticed.

The venous plexus within the left adrenal gland drains into the left adrenal vein (30mm), which passes downward, inferior, medial, and posterior to the body of the pancreas, then joins the inferior phrenic vein before entering the left renal vein 2–5 cm from the IVC [12]. The vascular regulation of the adrenal vein on the right side is more complicated. The shorter length of the right adrenal vein (6 mm) before emptying directly into the posterior part of the IVC, increases the risk of vena cava injury, which can lead to severe contusion and edema [10]. Hence, the majority of studies reported that adrenal trauma is more likely to involve the right adrenal.

Our AGI case demonstrated several uncommon features of adrenal trauma. Concerning the fact that most AGIs are often related to specific traumatic events, such as a car accident, and are usually accompanied by severe life-threatening injuries, our patient had only an AH and no other thoracoabdominal injuries [13, 14]. The results of laboratory, radiologic, or other diagnostic tests revealed no additional findings except an isolated unilateral adrenal injury. According to numerous studies, isolated traumatic unilateral AGI cases are extremely rare [13,2,4].

Due to the left-sided adrenal gland injury, this case was distinct from the previous studies. Because of its anatomical and physiological characteristics, it is believed that the right adrenal gland is more vulnerable to trauma [15].

Traumatic adrenal hematomas frequently present with a specific set of clinical symptoms, including acute abdominal pain, flank pain, fever, nausea, vomiting, hypotension, hypertension, palpable flank mass, agitation, sudden weakness, and altered mental status [15]. However, due to the LOC, the present patient was unable to describe pain or other symptoms.

Laboratory findings are frequently normal in cases of unilateral adrenal gland injury, such as the one experienced by our patient. However, bilateral adrenal gland injuries can present with biochemical markers of adrenal insufficiency, such as hyponatremia, hyperkalemia, hypoglycemia, and microscopic hematuria [7].

FAST is a preferred tool for detecting AGIs, searching in view of Morison's pouch or the splenorenal recess. However, similar to the present case, abdominal CT scans are more accurate and can detect additional lesions that could be missed by FAST. On a CT scan, an adrenal hemorrhage appears as a round to ovoid lesion, which may be contributed to peri-adrenal fat stranding, as well as the bleeding that may extend into the peri-nephric space [9]. In our case, an unenhanced CT scan revealed a 60-70 HU, hyperdense solid lesion with periadrenal fat stranding, which was suggestive of an adrenal hemorrhage.

Although ultrasound sonography can detect clinically significant AGI, it can sometimes fail due to the small size of the glands and the expert dependency of the

examiner. Ultrasonography is the modality of choice in infants due to their small body size and relatively large adrenal size [11]. In the present case, due to the patient's persistent hypotension and decreased LOC, the diagnosis was based on high clinical suspicion and was confirmed by a CT scan.

Magnetic resonance imaging (MRI) is an uncommon, yet the best and most accurate diagnostic modality.

The severity of the injury, the status of contralateral AG, and hemodynamic stability all play a vital role in the management of AGIs or hemorrhage. Adrenal hematoma by itself is typically a self-limited and benign lesion that does not require intensive care monitoring or surgical intervention. However, due to the possibility of substantial hemorrhage requiring transfusion, AH should not be considered an incidental finding. Operative exploration is recommended when active bleeding along with unstable hemodynamics is present [7]. In our case, an adrenalectomy was performed due to her unstable presentation for her.

To the best of our knowledge, there have been no previously reported cases of solitary adrenal blunt injury in adult patients in Iran.

Blunt adrenal injury is a rare phenomenon and is frequently accompanied by multiorgan damage resulting from severe life-threatening accidents. Clinical diagnosis requires a high level of clinical suspicion and is frequently misdiagnosed in emergency circumstances, particularly in isolated cases. Treatment is remarkably dependent on the patient's condition.

## Declaration

**Ethics approval and consent to participate:** The study was approved by the Ethics committee of Shahid Rajaei (Emtiaz) Trauma Hospital, Shiraz, Iran. Written informed consent was obtained from the patient for the publication of this case report and accompanying images.

**Consent for publication:** The authors provide consent for publication.

**Conflict of Interest:** None declared.

**Funding:** The authors received no financial support for the research, authorship, and publication of this article.

**Authors' Contributions:** HAF: played a crucial role in the conceptualization and design of the study. SB: assisted in the data collection process and contributed to the writing the manuscript and provided critical feedback during manuscript preparation and revision. ZM: coordinated data collection and contributed to the writing the manuscript

**Acknowledgment:** None declared.

## References

1. Stawicki SP, Hoey BA, Grossman MD, Anderson HL, 3rd, Reed JF, 3rd. Adrenal gland trauma is associated with high injury severity and mortality. *Curr Surg.* 2003;**60**(4):431-6.
2. Lehrberg A, Kharbutli B. Isolated unilateral adrenal gland hemorrhage following motor vehicle collision: a case report and review of the literature. *J Med Case Rep.* 2017;**11**(1):358.
3. DiGiacomo JC, Angus LD, Coffield E. Adrenal Injuries: Historical Facts and Modern Truths. *World J Surg.* 2017;**41**(4):975-9.
4. Rana AI, Kenney PJ, Lockhart ME, McGwin G, Jr., Morgan DE, Windham ST, 3rd, et al. Adrenal gland hematomas in trauma patients. *Radiology.* 2004;**230**(3):669-75.
5. Cesmebasi A, Du Plessis M, Iannatuono M, Shah S, Tubbs RS, Loukas M. A review of the anatomy and clinical significance of adrenal veins. *Clin Anat.* 2014;**27**(8):1253-63.
6. Angara V, Digiacomo JC. Adrenal gland injury due to gunshot. *Chin J Traumatol.* 2020;**23**(3):149-51.
7. Liao CH, Ouyang CH, Fu CY, Wang SY, Lin KJ, Kuo IM, et al. The current status and management of blunt adrenal gland trauma. *Surgery.* 2015;**157**(2):338-43.
8. Yeoh P. Anatomy and Physiology of the Adrenal Gland. *Advanced Practice in Endocrinology Nursing*: Springer; 2019. p. 645-55.
9. Willenberg H, Bornstein S. Adrenal cortex; development, anatomy, physiology. *Endotext [Internet]*. 2017.
10. Avisse C, Marcus C, Patey M, Ladam-Marcus V, Delattre JF, Flament JB. Surgical anatomy and embryology of the adrenal glands. *Surg Clin North Am.* 2000;**80**(1):403-15.
11. Papadopoulos KS, Strigklis K, Kordeni K, Xaplanteri P, Zacharis G. Adrenal gland injury after blunt abdominal trauma: Two case series and review of the literature. *Int J Surg Case Rep.* 2020;**67**:34-8.
12. Siebert M, Robert Y, Didier R, Minster A, M'Sallaoui W, Bellier A, et al. Anatomical Variations of the Venous Drainage from the Left Adrenal Gland: An Anatomical Study. *World J Surg.* 2017;**41**(4):991-6.
13. Addeo G, Cozzi D, Danti G, Bertelli E, Ferrari R, Pradella S, et al. Multi-detector computed tomography in the diagnosis and characterization of adrenal gland traumatic injuries. *Gland Surg.* 2019;**8**(2):164-73.
14. DiGiacomo JC, Gerber N, Angus LDG, Munnangi S, Cardozo-Stolberg S. Blunt Adrenal Injury: Results of a State Trauma Registry Review. *Am Surg.* 2019;**85**(4):390-6.
15. Ortu M, Vaccarezza M, Trovati S, Galli M, Gervasoni C, Vella A. A martial arts injury: karate induced unilateral haematoma of the adrenal gland. *Br J Sports Med.* 2006;**40**(8):730-1; discussion 1.

**Open Access License**

All articles published by Bulletin of Emergency And Trauma are fully open access: immediately freely available to read, download and share. Bulletin of Emergency And Trauma articles are published under a Creative Commons license (CC-BY-NC).