



***Enterobius Vermicularis* Infestation Causing Appendiceal Diverticulitis**

Semra Demirli Atıcı^{1*}, MD;  Tayfun Kaya¹, MD; Dudu Solakoğlu Kahraman², MD; Mümin Emiroğlu², MD

¹Department of General Surgery, University of Health Sciences Tepecik Training and Research Hospital, Yenisehir/Konak/Izmir, Turkey

²Department of Pathology, University of Health Sciences Tepecik Training and Research Hospital, Yenisehir/Konak/Izmir, Turkey

*Corresponding authors:

Semra Demirli Atıcı, MD;
Department of General Surgery, S.B.Ü. Tepecik Eğitim ve Araştırma Hastanesi Güney Mahallesi, 1140/1. Sk. No:1, 35180 Yenisehir/Konak/Izmir, Turkey. Tel: +90 53 63624585
Email: smrdemirli@hotmail.com

Received: 13-09-2021

Accepted: 13-09-2021

Abstract

Introduction: *Enterobius vermicularis* is one of the parasitic diseases involved in the etiology of acute appendicitis. Appendiceal diverticulitis is a rare clinical condition that often presents with the clinical manifestations of acute appendicitis.

Case Presentation: A 57-year-old woman was admitted to the emergency department with complaints of abdominal pain and loss of appetite. The patient, whose physical examination and imaging modalities were compatible with acute appendicitis, was hospitalized. An explorative laparotomy showed findings consistent with acute appendicitis, and an appendectomy was performed. No problem was seen during the postoperative follow-up of the patient, and she was discharged with healing. The examination of the pathology specimen revealed the coexistence of appendiceal diverticulitis and *E. vermicularis*.

Conclusion: Although many cases of acute appendicitis due to *E. vermicularis* infestation have been reported, the coexistence of appendiceal diverticulitis with *E. vermicularis* has not been reported in the literature. Histopathological confirmation was vital as the necessary anthelmintic treatment was prescribed to the patient and her close contacts, averting the spread of infection.

Keywords: *Enterobius vermicularis*, Appendiceal diverticulitis, Diverticulitis

Please cite this paper as:

Demirli Atıcı S, Kaya T, Solakoğlu Kahraman D, Emiroğlu M. *Enterobius vermicularis* infestation causing appendiceal diverticulitis. *Ann Colorectal Res.* 2021;9(3):114-117. doi: 10.30476/ACRR.2021.92776.1115.

Introduction

Acute appendicitis is the most common condition requiring emergency abdominal surgery all over the world (1). The clinical manifestations of acute appendicitis result from the obstruction of the appendiceal lumen secondary to lymphoid hyperplasia, fecaloid material, and, rarely, parasitic infections (1). Appendiceal diverticulitis is often asymptomatic, and its preoperative diagnosis is

difficult. It is a rare pathological condition with a clinical presentation similar to complicated acute appendicitis (2). Appendiceal diverticula are usually incidentally identified during the postoperative histopathological examination (2, 3).

In this case report, we present a case of appendiceal diverticulitis mimicking the clinical presentation of acute appendicitis and compatible with the postoperative histopathological diagnosis of *Enterobius vermicularis* infestation.

Case Report

A 58-year-old female patient with no known chronic disease history was admitted to the emergency room with complaints of anorexia and abdominal pain that started two days beforehand and increased progressively in severity. The patient, who had no history of surgery, described that the abdominal pain had started from the umbilical region and migrated to the right lower quadrant. She had concomitant nausea and fever (38.6 °C). The physical examination revealed tenderness and rebound tenderness in the right lower quadrant. In the laboratory tests, the white blood cell count was 9500/mm³ (normal range: 4200-10.600/mm³), while other results, including liver and renal function tests, were within normal limits. The abdominal computed tomography (CT) revealed a tubular structure measuring 10 mm in the widest part adjacent to the cecum, compatible with acute appendicitis. The patient, whose physical examination and imaging were compatible with acute appendicitis, was hospitalized for surgery. During the laparotomy performed with a McBurney incision following general anesthesia, it was observed that the appendix was erectile, inflamed and there was a cloudy, purulent peri-appendiceal fluid collection. Samples were taken from this fluid. The patient underwent an appendectomy. The patient, who was followed up postoperatively, was discharged without any problem after three days of antibiotic therapy. In the direct examination of the peri-appendiceal fluid, 3-4 polymorphonuclear leukocytes were seen in each field; the culture yielded no growth. The macroscopic examination of the appendectomy material showed an area compatible with an appendix with a size of 10×0.8 cm and an acquired diverticulitis protruding 0.7 cm from the tip of the appendix (Figure 1). Diverticulitis secondary to inflammation of the appendiceal diverticulitis was observed (Figure 2). Eggs of *E. vermicularis* infestation were also seen in the serial sections of the appendix (Figure 3).

The patient was referred to the Department of Infectious Diseases with the postoperative pathology result. Anthelmintic treatment was initiated for the patient and for individuals with whom the patient was in contact at home, and they were informed about the necessary contact measures. Written informed consent was obtained from the patient for publication and any accompanying images.

Discussion

Appendiceal diverticular disease is a rare condition first described by Kelynack in 1893 (1). Based on histopathological features, appendiceal diverticula are divided into two subtypes: true (congenital) and false (acquired) diverticula (2, 3). The incidence of congenital appendiceal diverticulitis is reportedly 0.014%, less than that of acquired appendiceal diverticulitis (1.9%) (3). Congenital diverticula are

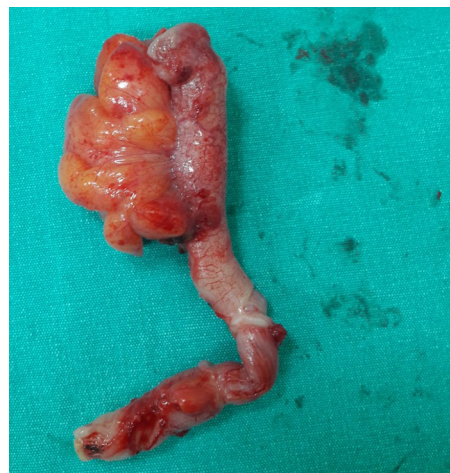

Figure 1: The macroscopic examination of the appendectomy material showed an area compatible with an appendix with a size of 10×0.8 cm and an acquired diverticulitis protruding 0.7 cm from the tip of the appendix.

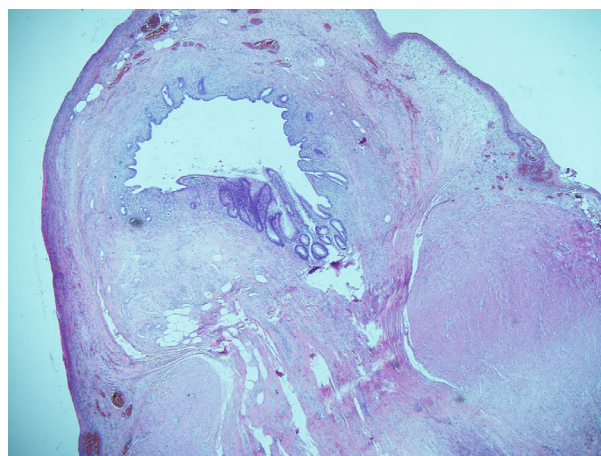


Figure 2: Microscopic view of appendiceal pseudodiverticulitis: acute inflammation and herniation of mucosa and submucosa are seen (H&E, ×40).

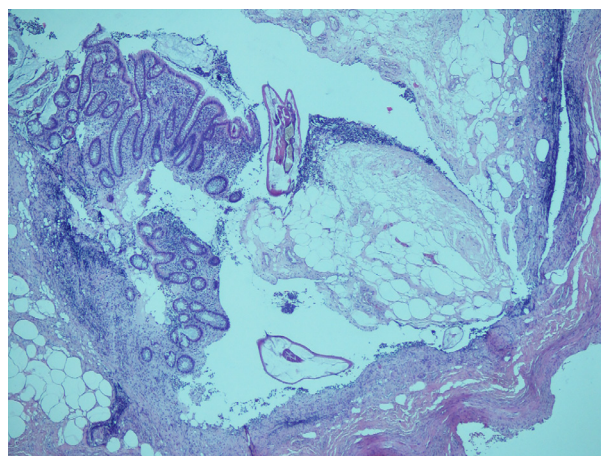


Figure 3: Eggs of *Enterobius vermicularis* infestation were seen in the serial sections of the appendix (H&E ×100).

located on the appendix's antimesenteric side, and herniation is observed with mucosa, submucosa, muscularis propria, and serosa. Congenital appendiceal diverticulitis, which is very rare, is associated with several inherited diseases (1, 2). Acquired (pseudo) diverticula, which constitute the

majority of the appendiceal diverticula, appear on the mesenteric side and, unlike the congenital form, muscularis propria herniation does not accompany (1, 2). Although it has been reported that there are some risk factors involved in the etiology of acquired appendiceal diverticulitis (male gender, >30 years of age, Hirschsprung's disease, and cystic fibrosis), none were present in our case (6).

Appendiceal diverticula commonly follow an asymptomatic course (2, 3). Generally, when these diverticula are complicated, they present with a clinical presentation similar to that of acute appendicitis and are detected incidentally during postoperative histopathological examinations. Appendiceal diverticulitis is reported as a rare etiology of acute appendicitis, with an incidence between 0.004% and 2.1% (2, 3).

Identification of appendiceal diverticulitis with CT, one of the preoperative imaging modalities, is important in making an accurate diagnosis. Different studies report that CT can predict appendiceal diverticulitis diagnostically and have specific appearances (4, 5). Yardimci et al. (4) reported that an increase in appendix length and inflammation in peri-appendicular fatty tissue support the diagnosis of appendiceal diverticulitis. However, as in the case we present, preoperative CT of most patients who had a postoperative histopathological examination compatible with acute diverticulitis revealed an appearance consistent with acute appendicitis in the literature (2, 3). Although appendiceal diverticulitis often presents with the clinical presentation of acute appendicitis, their mortality is higher because they have a higher perforation rate. Therefore, an appendectomy with a conventional or laparoscopic method is recommended, even if detected incidentally (2, 3).

Enterobius vermicularis is a fecal-orally transmitted intestinal nematode common worldwide, especially in areas with poor fecal sanitation (6). Although it is seen at any age and socioeconomic level, the incidence is higher among children and females (6, 7). *E. vermicularis* has a simple life cycle, and humans are the only natural host (6). Once *E. vermicularis* enters through the mouth and reaches maturity, it may stay in the terminal ileum, cecum, appendix, and colon, and may not cause symptoms in the patient (6, 7). Although the

most typical symptom of an infestation is pruritus ani, which worsens particularly at night, symptoms such as abdominal pain, loss of appetite, teeth grinding, anemia, and mouth drooling may also be observed (6, 8). *E. vermicularis* infestation is most commonly manifested by the clinical picture of acute appendicitis; nonetheless, it has been reported that it may lead to diseases such as salpingitis, ileocolitis, mesenteric abscess, or Meckel's diverticulitis (6-9). However, appendiceal diverticulitis secondary to *E. vermicularis* infestation has not been reported.

Two hypotheses have been proposed as inflammatory and non-inflammatory causes related to the development of acquired-type appendiceal diverticulitis, the most common type of appendiceal diverticulitis (10). The inflammatory hypothesis advocates that chronic inflammation in the appendix leads to the development of appendiceal diverticulitis secondary to lymphoid tissue atrophy and thinning of the appendiceal wall. This is while the non-inflammatory hypothesis holds that obstruction caused by fecaliths, tumor, and parasites gives rise to increased muscular activity in the appendiceal wall, eventuating in appendiceal diverticulitis (10). It may be thought that *E. vermicularis* supports both hypotheses. The parasite may cause chronic inflammation, with diverticulitis developing secondary to appendiceal wall atrophy and weakness. It may also play a role in diverticulitis formation by increasing intraluminal inflammation, leading to obstruction and elevated intraluminal pressure. Although there is no literature on this subject, in the current case, diverticulitis may have developed following obstruction and inflammation caused by *E. vermicularis* infestation. As there are no case series and studies on this subject, no data are available in support of our hypothesis, indicating a key study limitation.

In conclusion, many cases of acute appendicitis due to *E. vermicularis* infestation have been reported in the literature. However, the coexistence of *E. vermicularis* and appendiceal diverticulitis, a rare condition, has not been reported. Histopathological confirmation is crucial. The spread of infection may be avoided by giving the necessary anthelmintic treatment to the index case and their close contacts.

Conflicts of interest: None declared.

References

- Baird DLH, Simillis C, Kontovounisios C, Rasheed S, Tekkis PP. Acute appendicitis. *BMJ*. 2017;357:j1703. doi: 10.1136/bmj.j1703.
- Marcacuzco AA, Manrique A, Calvo J, Loinaz C, Justo I, Caso O et al., Clinical implications of diverticular disease of the appendix. Experience over the past 10 years., *Cir Esp*. 2016;94(1):44-7. doi: 10.1016/j.ciresp.2014.05.003.
- Altieri ML, Piozzi GN, Salvatori P, Mirra M, Piccolo G, Olivari N, Appendiceal diverticulitis, a rare relevant pathology: Presentation of a case report and review of the literature, *Int J Surg Case Rep*. 2017;33:31-34. doi: 10.1016/j.ijscr.2017.02.027.
- Yardimci AH, Bektas CT, Pasaoglu E, Kinaci E, Ozer C, Sevinc MM,, Retrospective study of 24 cases of acute appendiceal diverticulitis:CT findings and pathological correlations, *Jpn J Radiol*. 2017;35(5):225-232.
- Osada H, Ohno H, Saiga K, Watanabe W, Okada T, Honda N. Appendiceal diverticulitis: multidetector CT features. *Jpn J Radiol*. 2012;30:242-248.
- Rawla P, Sharma S. *Enterobius*

- Vermicularis (Pinworm) [Updated 2019 Nov 21]. In: StatPearls [Internet]. Treasure Island (FL): StatPearls Publishing; 2020 Jan-. Available from: <https://www.ncbi.nlm.nih.gov/books/NBK536974/>
7. Hammood ZD, Salih AM, Mohammed SH, Kakamad FH, Salih KM, Omar DA, Int J Surg Case Rep. Enterobius vermicularis causing acute appendicitis, a case report with literature review., 2019;63:153-156. doi: 10.1016/j.ijscr.2019.09.025.
 8. Zouari M, Louati H, Abid I, Trabelsi F, Ben Dhaou M, Jallouli M, et al. Arch Iran Med. Enterobius vermicularis: A Cause of Abdominal Pain Mimicking Acute Appendicitis in Children. A Retrospective Cohort Study. 2018 1;21(2):67-72.
 9. Dos Santos VM, Enterobius vermicularis: Uncommon Clinical Presentations., Arch Iran Med. 2019 1;22(2):104-105.
 10. Abdullgaffar B. Diverticulosis and diverticulitis of the appendix. Int J Surg Pathol. 2009;17:231-237.