



Technique of Ghost (*Khatith*) Ileostomy: Our Experience and Guidelines

Mudassir Ahmad Khan^{1*}, MBBS, MS, FACRSI, FCRS;  Nisar A Chowdri², MBBS, MS, FACS, FACRSI, FMAS; Rauf A Wani², MBBS, MS, MRCS, FACRSI; Fazl Q Parray², MBBS, MS, FACS, FACRSI, FMAS; Asif Mehraj², MBBS, MS, FACRSI, FCRS; Arshad Baba³, MBBS, MS, FACRSI; Mushtaq Laway³, MBBS, MS, FACRSI

¹Assistant Professor, Department of General Surgery; GMC Rajouri, J&K, India

²Department of Colorectal Surgery SKIMS, Srinagar, J&K, India

³Directorate of Health Services, Kashmir, India

*Corresponding authors:

Mudassir Ahmad Khan,
Assistant Professor, Department of General Surgery; GMC Rajouri, J&K, India.
Tel: +91 9419070892, +91 9796730645;
Email: khanmudassir925@gmail.com

Received: 19-01-2021

Revised: 05-04-2021

Accepted: 05-04-2021

Abstract

Background: The concept of ghost ileostomy (GI) or *Khatith* (meaning 'hidden' in the Kashmiri language) ileostomy is a bridge between covering ileostomy (CI) and no ileostomy.

Methods: To evaluate the feasibility and the eventual advantages and disadvantages of GI, we carried out a prospective case-control study of GI vs. CI in restorative colorectal resections for rectal carcinoma. We divided restorative colorectal resection patients into two groups, i.e., a GI group (33 patients) and a CI group (29 patients). Postoperatively, the two groups were studied with respect to complications, mortality, morbidity, cost, hospital stay, the conversion rate of GI, and the operating time. We also provided our instructions and guidelines for performing the GI.

Results: According to our findings, the GI group was characterized by a shorter mean operating time, shorter overall hospital stay, decreased total morbidity, decreased overall treatment cost, and higher rates of stoma-free life of the patient as compared to the CI group. There was no statistically significant difference in the patients of the two groups concerning the start of oral liquids, drain removal, and anastomotic leakage (AL) rate.

Conclusion: The GI prevents the creation of a formal covering loop ileostomy in more than 80% of patients undergoing restorative colorectal resections for rectal carcinoma. The GI presents as an alternative to CI in patients at low or medium risk for AL. However, we should be cautious of creating the GI in patients with post-neoadjuvant treatment status with a history of neutropenia or patients with malnutrition and hypoalbuminemia.

Keywords: Ghost ileostomy, Carcinoma rectum, Anastomotic leak, Pre-stage ileostomy, Virtual ileostomy

Please cite this paper as:

Khan MA, Chowdri NA, Wani RA, Parray FQ, Mehraj A, Baba A, Laway M. Technique of Ghost (*Khatith*) Ileostomy: Our Experience and Guidelines. *Ann Colorectal Res.* 2021;9(2):51-57. doi: 10.30476/ACRR.2021.89835.1082.

Introduction

Anastomotic leakage (AL) is the most significant complication after colorectal surgery, especially after low anterior resection. The consequences of AL are generalized peritonitis, localized abscess formation, and formation of an enterocutaneous fistula. Most minor leaks are managed conservatively. However, if re-exploration becomes necessary, the mortality rate of this complication is very high. In fact, the mortality rate associated with symptomatic anastomotic leaks varies between 6 and 22 % (1). The role of a protective diverting stoma in avoiding this serious complication has repeatedly been discussed, but prospective randomized studies on this subject are rare and their results contradictory. Several authors have also argued that the stoma only mitigates the consequences of leakage but does not lower the leakage rate itself (2). In addition, ostomy construction and closure are associated with considerable morbidity and increased costs (3). Also, there is a considerable risk of AL at the time of stoma take-down. Moreover, the creation of a stoma is hardly acceptable to the patient and represents an added psychological trauma to the patient and caregivers. Therefore, the benefits of a protective stoma in decreasing the rate of AL must be balanced against the morbidity of its construction and closure (4). The quality of life in a patient with a stoma is affected by physical and psychological factors, especially body image and self-concept (5). In short, some authors have recommended the routine use of a temporary stoma to reduce the morbidity rate from AL (6, 7), while others have discouraged the routine use of temporary stomas, preferring selective use. The overall incidence of clinical leakage in a colorectal anastomosis is 8%, meaning that covering stoma confectioning, if analyzed retrospectively, is with minimal or no clinical usefulness in the majority of patients (92%) (8).

Recently, the concept of pre-stage ileostomy (ghost ileostomy [GI]/virtual ileostomy) has been developed in order to combine the advantages of a covering ileostomy (CI) without entailing its complications in patients subjected to low rectal resection. In the case of clinical and radiological AL, the pre-stage GI is matured to complete the CI and divert the fecal stream from the anastomotic site leakage. However, in the case of an uneventful postoperative course, a pre-stage GI prevents all complications related to a defunctioning ileostomy (9). GI is characterized by shorter recovery, a lesser degree of total as well as anastomosis-related morbidity, and higher quality of life for both the patient and the family (10-13). Moreover, in the case of anastomotic dehiscence and the necessity of delayed stoma opening, the mortality and morbidity in patients with GI are comparable with those that occur in patients who had a classic covering stoma. On the other hand, it is simple to think about the possible economic savings

in patients with GI, avoiding a second admission for closure of the ileostomy and all of its associated costs; this represents a huge saving for the patient and the hospital and also raises the quality of life of the patients (14).

Ghost ileostomy or virtual ileostomy is simply a pre-stage ileostomy that at any time can be externalized and opened. We also regard this procedure as *Khatith* (meaning 'hidden' in the Kashmiri language) ileostomy. There are two types of GI, including GI without parietal wall split and GI with parietal wall split. In GI without parietal wall split, the ileal loop is neither brought outside the abdominal cavity and nor is opened to the exterior, while in GI with parietal wall split, the ileal loop is brought out of the abdominal cavity at the usual site of ileostomy but the ileal loop is not incised. In this paper, we will be discussing in detail the technique of GI without parietal wall split.

Methods

Study Design

To evaluate the feasibility and the eventual advantages and disadvantages of GI, we carried out a prospective case-control study of GI vs. CI in restorative colorectal resections for rectal carcinoma. We divided restorative colorectal resection patients into two groups, i.e., a GI group (33 patients) and a CI group (29 patients). Postoperatively, the two groups were studied with respect to complications, mortality, morbidity, cost, hospital stay, the conversion rate of GI, and the operating time. The compiled data were statistically analyzed and inferences were drawn from the results.

Surgical Procedure

In patients of sigmoid and rectal cancers, after performing total mesorectal excision (anterior resection [AR]/low anterior resection [LAR]/ultra-LAR) and resection of the tumor with adequate circumferential margins, colorectal/coloanal anastomosis is performed in an end-to-end or end-to-side fashion using a circular stapler or the hand-sewn technique. After the completion of the anastomosis, a GI without parietal wall split can be fashioned. The patient is kept in the supine/lithotomy position and maintained under anesthesia (whether general anesthesia or combined spinal-epidural anesthesia). Then, a terminal ileal loop at almost 20 cm from the ileocecal junction is identified, without any tension or twist at the mesentery. The proximal end of the GI loop is marked (Figure 1) by a suture with a single long thread while the distal end is marked by a suture with double (two) long threads ('d' for distal and 'd-' for double). Such marking helps us in identifying the proper orientation of the loop in case the GI needs maturation. Subsequently, a small (3-4 mm) hole/window is created in the mesentery of this identified ileal loop with the help of electrocautery

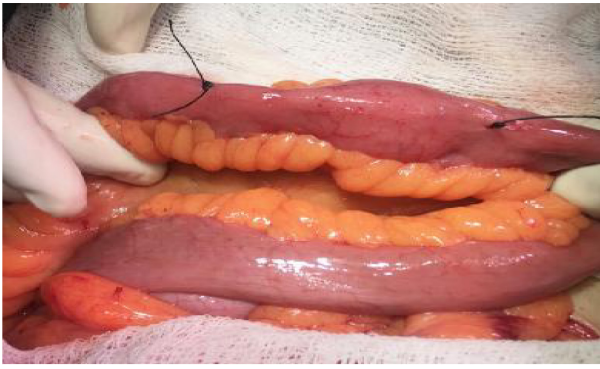


Figure 1: Identifying and marking the ends of the terminal ileal loop; 'D' for distal and 'D-' for the double long thread.

and a hemostatic artery clip, taking care not to injure the vascular arcade (Figure 2). Also, this hole in the mesentery should be away from adjacent vessels and about 2-3 cm from the mesenteric border of the ileum. This is to avoid the possible erosion of the hanging tube into the adjacent vessels and the gut wall. Next, a small (10-12 F) soft Ryle's tube (feeding tube) or Foley catheter is passed through this small opening in the mesentery of the identified ileal loop (Figure 3). Again, a small 5 mm incision is made at the pre-operatively marked proposed ileostomy site on the parietal wall in the right iliac fossa region. A Kelly hemostatic forceps is then introduced (Figure 4) through this small incision to get out the two limbs of Ryle's (feeding) tube, which has already been looped around the identified ileal loop (Figure 5). These two limbs of the feeding tube are subsequently cut short and fixed to each other and to the surrounding skin with 2-0 silk sutures, taking care to keep the tubing loop loose enough to avoid any tension to the vascular supply and without causing any luminal compression of the ileal loop (Figures 6 and 7). After fixation of the feeding tube, the main laparotomy incision is closed, taking care to keep away the GI loop from the main wound and also to cover the laparotomy incision area from inside with omentum, preventing the adherence of the GI loop to the main laparotomy wound. In this way, in the case that the GI needs maturation, this ileal loop is free of adhesions with the parietal wall and main incision site and can be easily mobilized and

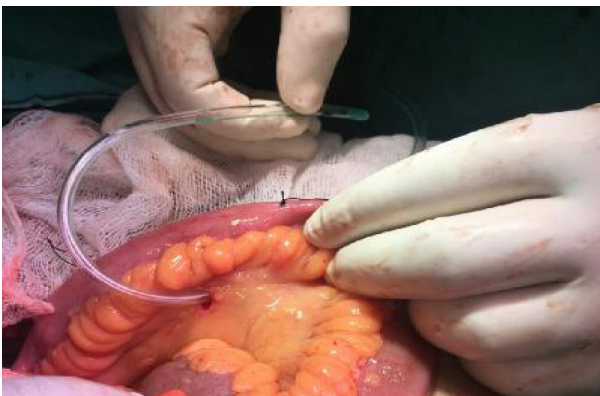

Figure 3: Passing a small Ryle's tube through the hole in the mesentery.

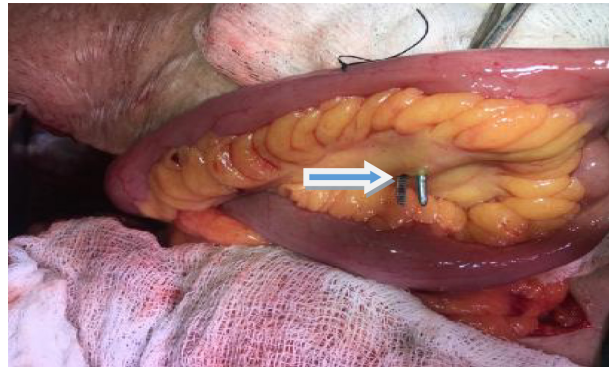


Figure 2: Making a small hole in the mesentery of the identified loop.

exteriorized.

Postoperative Monitoring

Postoperatively, patients should be monitored clinically on a regular basis with a close watch on the pulse, blood pressure, respiratory rate, fever, abdominal distension or tenderness, and drain contents. On the third postoperative day (POD), a complete blood count and C-reactive protein assay should be sent for all patients to assess for sepsis or, indirectly, for AL. Postoperatively, limited contrast radiology is routinely performed. Ultrasonography of the abdomen and pelvis is done on 5th-7th POD to rule out any abdominal or pelvic collection. If any collection is seen, a contrast X-ray of the pelvis can be done after instilling water-soluble contrast just above the anal canal to rule out any significant contrast leak at the anastomotic site. In case of significant AL on X-ray, a CT scan of the abdomen and pelvis should be performed.

Release Down of Ghost Ileostomy

After the confirmation that there is no AL, the removal of the hanging Ryle's tube loop (or any other hanging material) from the abdominal cavity in order to release the tucked ileal loop is referred to as the 'release down' of GI. It can be done after the seventh POD but should be preferably done after the tenth POD. In the case of an uncomplicated postoperative course, this fixing tube of the GI is removed in the ward without the need for any anesthesia as described

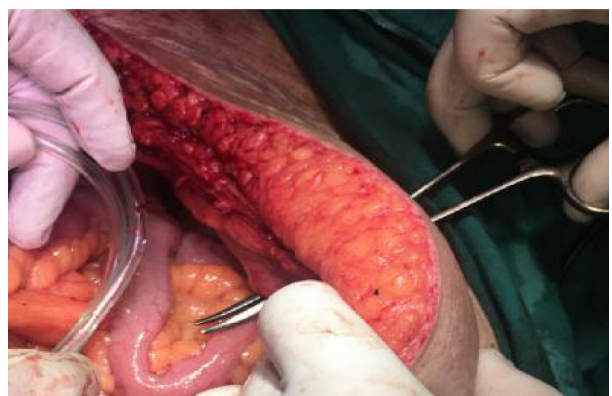

Figure 4: Insertion of Kelly forceps through the 5 mm incision in the right iliac fossa.

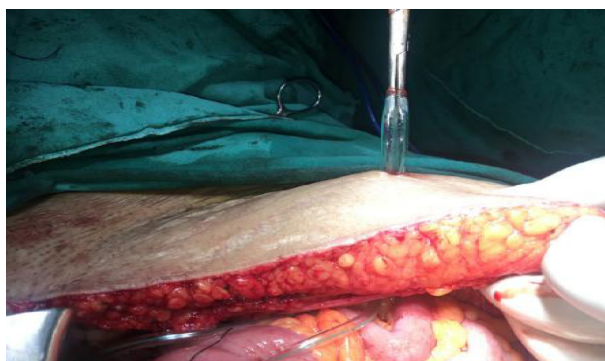


Figure 5: Bringing out the two limbs of looped RT through the parietal wall.

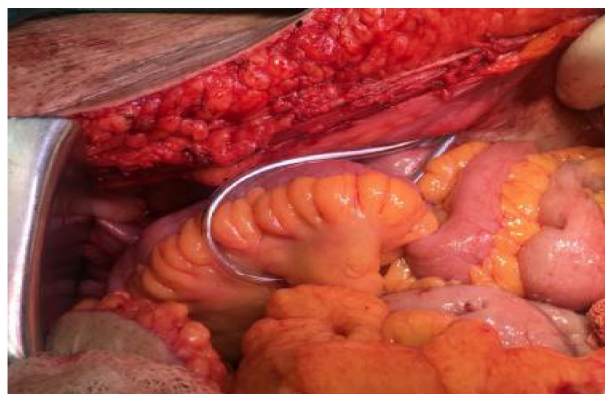

Figure 7: Final internal appearance of the ghost ileostomy loop.

in the following steps: (i) keep the patient in the supine position on his/her bed and uncover the area of the GI; (ii) apply betadine paint on the GI tubing and the skin around it; (iii) cut the fixing suture of the GI tube to free the tubing from the surrounding skin (Figure 8); (iv) slightly pull both limbs of the tubing (Figure 8) and cut one limb with the help of scissors deeper to the skin level (Figure 9); (v) slightly dip the cut end of the loop into the peritoneal cavity with the help of forceps; (vi) gently pull the other end of the tubing from the abdominal cavity to release down the already tucked ileal loop; (vii) clean the wound area and apply a small antiseptic dressing.

Ghost Ileostomy Maturation

To mitigate the consequences of AL after restorative colorectal resections, the pre-stage GI is converted into a full-fledged formal diversion loop ileostomy. This conversion into a formal diversion loop ileostomy is referred to as maturation or exteriorization of the GI. Keeping in view the safety of the patient, the threshold for exteriorization should be kept low. In case of AL suspected on clinical plus radiological grounds, the pre-stage GI is easily transformed into a formal covering stoma as described in the following steps: (i) the exteriorization of the GI is usually done under local anesthesia by infiltrating about 15 ml of diluted lignocaine-adrenaline solution around the GI site into the subcutaneous plane and in-between the parietal wall muscles (transverse abdominis plane block). Alternately, if the patient is anxious and uncooperative, spinal anesthesia can be used; (ii) the

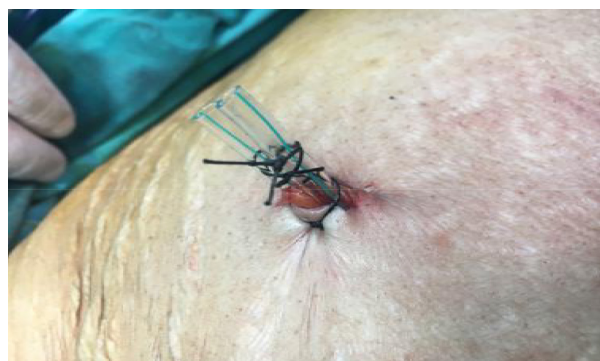

Figure 6: Final external appearance of the ghost ileostomy.

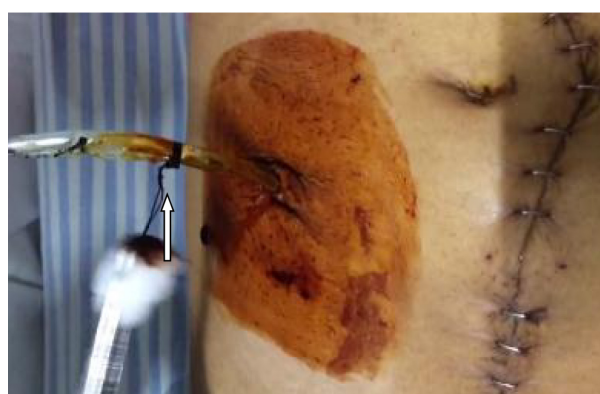

Figure 8: Gently pull out the ghost ileostomy tubing after cutting the suture around it.

patient is kept in the supine position on the operating table; (iii) after painting and draping the patient, hold the two limbs of the looped feeding (Ryle's) tube with the help of an artery clip; (iv) a circular incision about 2-2.5 cm diameter is made around the GI tubing with the help of monopolar cautery (Figure 10). This circular incision is deepened up to the parietal wall sheath and the disc-shaped skin patch is excised along with the fat; (v) in order to enter the peritoneal cavity, a cruciate incision is given on the sheath around the tubing of the GI taking care not to injure the underlying ileal loop. This cruciate incision should be large enough to admit 2-3 fingers so that the ileal loop can be easily pulled up and accommodated as loop ileostomy; (vi) to get the desired ileal loop out of the peritoneal cavity through this incision, gently pull the tubing up along with the tucked ileal loop (Figure 11). If the ileal loop does not come out easily, gently sweep your finger around the ileal loop to break the adhesions and make this loop mobile before pulling up any further; (vii) bring out the adequate length of the ileal loop sufficient to construct the formal loop ileostomy. Cut the tubing around the ileal loop and remove it along with the excised skin and subcutaneous fat disc; (viii) to give proper orientation to the ileostomy, identify the proximal and distal ends of the loop by identifying the already placed suture marks (described in the above section); (ix) now, make a transverse incision on the antimesenteric border of this ileal loop and complete the ileostomy in the standard fashion (Figure 12).

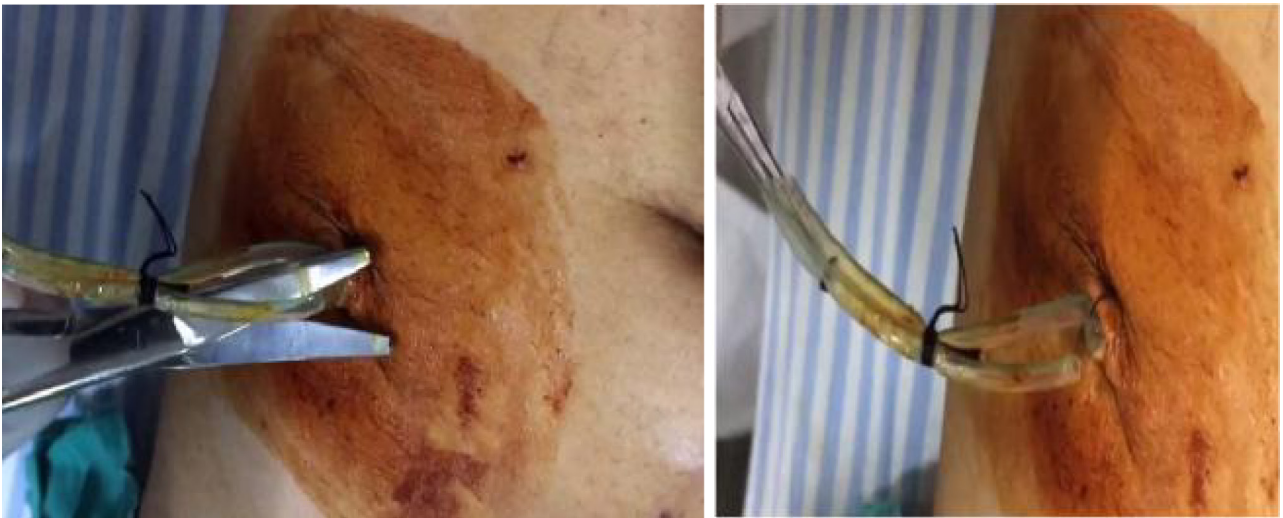

Figure 9: (A&B): Cut one end of the tubing deeper to the skin level.

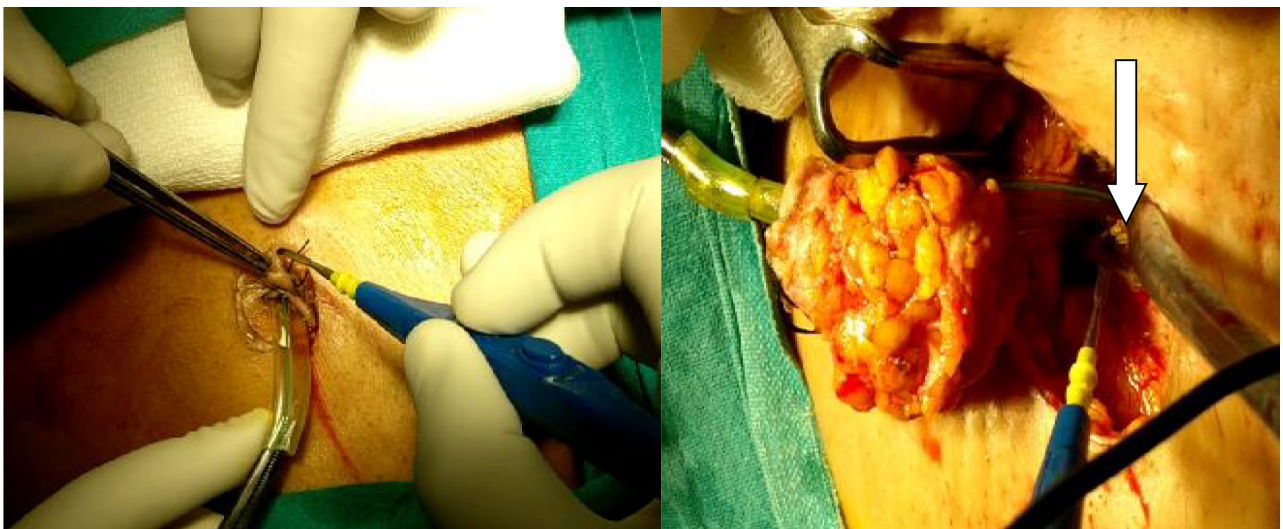


Figure 10: Make a circular incision around the ghost ileostomy tubing and dissect up to the sheath.

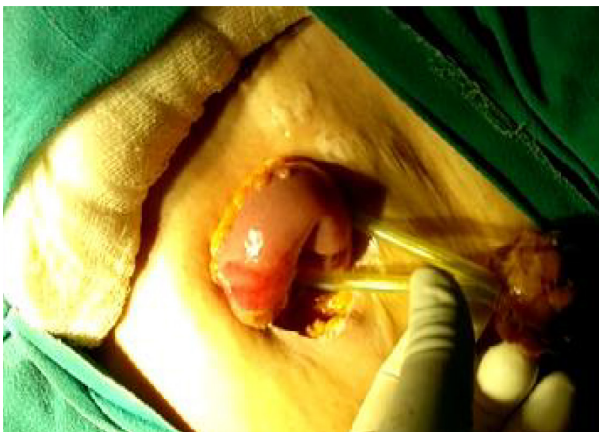

Figure 11: Gently pull out the ileal loop around the tubing.

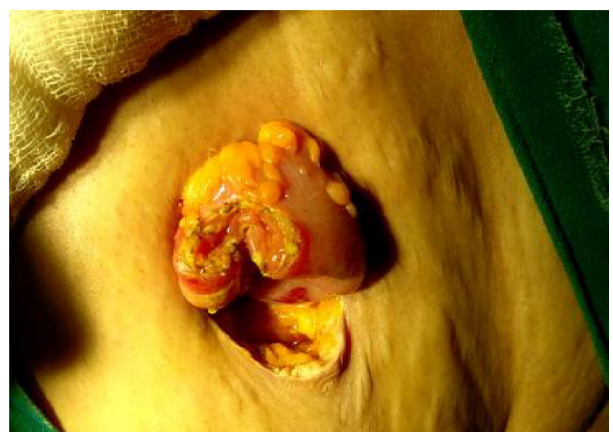

Figure 12: Transverse incision of the ileal loop and fashioning of formal loop ileostomy.

Results

The two study groups (GI vs. CI) were statistically comparable with respect to gender distribution, BMI, comorbidity status, smoking history, ASA grade, tumor grade, tumor stage, pre-operative albumin and hemoglobin levels, colon leakage score, neoadjuvant

therapy status, and distance of anastomosis from the anal verge. Follow-up of the patients in both groups ranged from 1 to 22 months (mean of 9.146 ± 3.50 months).

There was no statistically significant difference in the patients of the two groups concerning the start of oral liquids, drain removal, and AL rate (18 vs.

14%). The mean operating time in the GI group (136.40±40.40 mins.) was significantly less (P=0.000) than the CI group (193.00±53.03 mins). The mortality rate of the two groups was comparable. Six patients (18.2%) in the GI group needed exteriorization of pre-stage GI in view of AL. In other words, 82% of patients were saved from formal ileostomy in the GI group. A shorter overall hospital stay, lesser degree of total morbidity, lesser overall cost of treatment, and higher rates of stoma-free life were recorded in the GI group relative to the CI group.

Discussion

In the present article, we discuss our experience with GI and provide some recommended guidelines concerning its application. According to our findings, the concept of GI is a bridge concept between CI and no ileostomy. The GI group was characterized by a shorter mean operating time, shorter overall hospital stay, decreased total morbidity, decreased overall cost of treatment, and higher rates of stoma-free life of the patient as compared to the CI group. Notably, roughly four-fifths of the patients were saved from a formal ileostomy in the GI group.

Whenever there is any possibility of AL after restorative colorectal resections and the surgeon on the table doesn't feel the absolute need of a covering ileostomy, the GI is a good alternative option and can be constructed in the following situations: restorative colorectal resections for rectal carcinoma (AR/LAR/ultra-LAR); left hemicolectomy for left-sided colonic malignancies if the patient's nutritional status is low and there are other significant risk factors for AL; restorative colorectal resections for benign diseases like diverticulitis, diverticulosis, and resection rectopexy; advanced gynecological malignancies requiring pelvic exenteration with resection-anastomosis of the rectum (15); intraoperative finding of metastatic unresectable but non-obstructing colorectal lesions can be covered with GI so that in case of future bowel obstruction, the diversion ileostomy can be done under local anesthesia; after primary repair of left-sided colorectal injuries.

Though there is no absolute contraindication for GI done in elective settings, patients with a high Colon Leakage Score and multiple risk factors for AL should be covered with a formal ileostomy. The GI should be avoided in the following groups: patients with significant risk factors for AL or operated in emergency settings; patients taking steroids and immunosuppressant drugs; malnutrition and severe hypoalbuminemia (serum albumin <2.5 g/dl); acute bowel obstruction, perforation, and peritonitis; and familial adenomatous polyposis (FAP) and ulcerative colitis patients requiring total proctocolectomy (TPC) with ileal pouch-anal anastomosis (IPAA).

Though there are some reports of performing GI in patients of FAP (16), the AL in these patients may increase the chances of pouch excision and pouch failure, so it is better to cover these patients with a covering ileostomy.

Despite the fact that we did not come across any significant complications in our study apart from the conversion to formal loop ileostomy in six patients, there remains the theoretical possibility of the following complications and the surgeon should be vigilant to prevent these complications or at least to pick them up earlier: bowel obstruction due to kink or luminal compression of the ileal loop by the tightly fixed Ryle's tubing loop; bleeding in the mesentery due to erosion of Ryle's tube into a vessel; compression of the ileal vasculature resulting in chronic ischemia of the ileal loop with the possibility of subsequent stricture formation; difficulty of removing the tubing at the time of release down; difficulty of bringing out the ileal loop due to adhesions at the time of maturation; and internal herniation of the gut loop or the omentum into excessively loose tubing.

Conclusion

A GI prevents the creation of a formal covering loop ileostomy in more than 80% of patients of LAR/ultra-LAR/AR. The concept of GI is a bridge concept between covering ileostomy and no ileostomy and comes to the rescue of the surgeon in a state of ambivalence. This is an alternative to the covering ileostomy in patients at low or medium risk for AL. However, we should be cautious of creating the GI in patients with post-neoadjuvant treatment status with a history of neutropenia or patients with malnutrition and severe preoperative hypoalbuminemia.

Funding Information

This research did not receive any grants from any funding agency in the public, commercial or not-for-profit sectors.

Author Contribution

All authors have contributed equally to the preparation of this article.

Acknowledgment

We acknowledge the support of all our staff in the Department of General Surgery at SKIMS, Srinagar, Kashmir.

Conflicts of interests: None declared.

References

1. Ajani JA. In rectal carcinoma, colostomy or no colostomy: is this the question? *J Clin Oncol* 1993; 11: 193-4. [4]
2. Gastinger I, Marusch F, Steinert R, Wolff S, Koeckerling F, Lippert H. Protective defunctioning stoma in low anterior resection for rectal carcinoma. *Br J Surg* 2005; 92: 1137-42.
3. Tsunoda A, Tsunoda Y, Narita K, Watanabe M, Nakao K, Kusano M (2008). Quality of life after low anterior resection and temporary loop ileostomy. *Dis Colon Rectum*;51:218–222.
4. Pakkaste TE, Ovaska JT, Pekkala ES, Luukkonen PE, Järvinen HJ (1997). A randomised study of colostomies in low colorectal anastomoses. *Eur J Surg*;163:929–933.
5. Moore AK, Esquibel KA, Thal W(2008) Ostomy options for clients with ileostomies. *Gastroenterol Nurs* 31:418–420, quiz 21–2
6. Chude GG, Rayate NV, Patris V, Koshariya M, Jagad R, Kawamoto J, Lygidakis NJ (2008) Defunctioning loop ileostomy with low anterior resection for distal rectal cancer: should we make an ileostomy as a routine procedure? A prospective randomized study. *Hepatogastroenterology* 55:1562–1567
7. Pata G, D'Hoore A, Fieuws S, Penninckx F (2009) Mortality risk analysis following routine vs selective defunctioning stoma formation after total mesorectal excision for rectal cancer. *Colorectal Dis* 11:797–805
8. Hautefeuille P, Valeur P, Perniceni TH, Martin B, Galian A, Cherqui D, Hoang C: Functional and oncologic results after colo-anal anastomosis. *Ann Surg* 1988, 207:61-65.
9. Miccini M, Bonapasta SA, Gregori M, Barillari P, Tocchi A. Ghost ileostomy: real and potential advantages. *The American Journal of Surgery* (2010) 200, e55–e57
10. Nino Gullà, Trastulli S, Boselli C, Cirocchi R, Cavaliere D et. al. Ghost ileostomy after anterior resection for rectal cancer: a preliminary experience *Langenbecks Arch Surg* (2011) 396:997–1007
11. Sacchi M, Legge PD, Picozzi P, Papa F, Giovanni CL, Greco L. Virtual ileostomy following TME and primary sphincter-saving reconstruction for rectal cancer. *Hepatogastroenterology*. 2007 Sep;54(78):1676-8.
12. Mori, Lorenzo M.D.; Vita, Matteo M.D.; Razzetta, Francesco M.D.; Meinero, Piercarlo M.D.; D'Ambrosio, Giovanni M.D. Ghost Ileostomy in Anterior Resection for Rectal Carcinoma: Is It Worthwhile? *Diseases of the Colon & Rectum: January 2013 - Volume 56 - Issue 1 - p 29–34*
13. Blas Flor-Lorente, Luis Sanchez-Guillen, Gianluca Pellino, Matteo Frasson, et al. Virtual ileostomy combined with early endoscopy to avoid diversion ileostomy in low and ultralow colorectal anastomosis; a preliminary report. *Langenbeck's Archives of Surgery*. pp 1-9.
14. Michele Cerroni et al. Ghost Ileostomy with or without abdominal parietal split. *World Journal of Surgical Oncology* 2011, 9:92
15. Víctor Lago, Santiago Domingo, Luis Matute, Pablo Padilla, Blas Flor, Álvaro García-Granero. Ghost ileostomy in advanced ovarian cancer. *Gynecologic Oncology* 147 (2017) 488
16. Ambe PC, Zirngibl H, Möslein G. Routine Virtual Ileostomy Following Restorative Proctocolectomy for Familial Adenomatous Polyposis. *World J Surg*. 2018 Jun;42(6):1867-1871. doi: 10.1007/s00268-017-4365-0.