



Comparative Analysis of Triple Hemostatic Open Hemorrhoidectomy Versus Traditional Open Hemorrhoidectomy

Muhammad Shamim^{1*}

¹Department of Surgery, College of Medicine, Prince Sattam bin Abdulaziz University, Alkharj, Kingdom of Saudi Arabia

*Corresponding author: Dr Muhammad Shamim, Department of Surgery, College of Medicine, Prince Sattam bin Abdulaziz University, Alkharj, Kingdom of Saudi Arabia. Tel: +96-6536242618, E-mail: surgeon.shamim@gmail.com

Received 2018 February 04; Revised 2018 March 02; Accepted 2018 March 22.

Abstract

Background: Traditional open hemorrhoidectomy is the most commonly performed operation for the third or fourth degree hemorrhoids in the developing world, despite considerable postoperative pain and bleeding complications. This modification is an attempt to reduce these complications and compare the outcome of both methods.

Methods: A prospective, comparative study was conducted in phase I, at Fatima hospital at Baqai Medical University, from March 2009 to August 2011. It was followed by a descriptive case-series in phase II, conducted at different hospitals from September 2011 to August 2017. The inclusion criteria were patients of both genders and all age groups, with third or fourth degree hemorrhoids requiring surgery. The exclusion criteria were patients in between blocks (operated by other surgeons), patients with complicated hemorrhoids, closed hemorrhoidectomy cases, cases operated by residents, and cases lost to follow-up. In phase I, a total of 182 patients were enrolled and randomly allocated to group A or B undergoing triple hemostatic hemorrhoidectomy and traditional open hemorrhoidectomy, respectively; 231 patients were included in phase II (group C) undergoing modified hemorrhoidectomy. The analyzed variables were operative blood loss, operative time, postoperative pain, hospital stay, time to pain-free defecation, and per-operative or postoperative complications.

Results: There was significantly more operative blood loss in group B patients. Pain perception was significantly high in group B patients at eight and 24 hours, as well as eighth, 15th, and 30th days. Group B patients also had longer duration of operation and more prolonged pain-free defecation. Both, intra-operative and post-operative complications were higher among the group B. The outcome of phase II (group C) was similar to those of group A.

Conclusions: In a limited resource setting, triple hemostatic open hemorrhoidectomy offers potential advantages of less operative blood loss, shorter duration of operation, shortened hospital stay, shorter time to pain free defecation, and less postoperative pain and other complications.

Keywords: Hemorrhoidectomy, Surgical Diathermy, Hemostatic Techniques, Hemorrhoids

1. Background

Hemorrhoids are dilated cushions of anal veins covered by anal mucosa (1). It is one of the commonest diseases presented to the general surgeon, with a reported incidence of about 44% (2, 3). It is classified into 4 grades on the basis of symptoms. First degree hemorrhoids present with bleeding per rectum only; the second degree presents with prolapse during defecation, which reduces spontaneously, whereas the third degree needs to be manually reduced. Fourth degree hemorrhoids are prolapsed permanently. Finally, complicated hemorrhoids such as thrombosed, fibrosed, and inflamed can be labelled as the fifth degree hemorrhoids.

First and second degree hemorrhoids are usually dealt

by minimally invasive treatments (such as injection, sclerotherapy, and band ligation) (1, 2, 4, 5). Third and fourth degree hemorrhoids require definitive surgical treatment (6, 7). Fifth degree (complicated) hemorrhoids are first treated conservatively followed by operative treatment (if needed). Hemorrhoidectomy is one of the most commonly performed anorectal operations (8). Traditional open hemorrhoidectomy (Milligan-Morgan) and closed hemorrhoidectomy (Ferguson) are the well-established procedures for several decades. However, both are associated with postoperative complications such as bleeding, pain, and anal stenosis, which invites surgeons to develop new techniques such as the modified Ferguson, stapled hemorrhoidectomy (Longo), and many other modifications such as use of electrothermal device, laser, harmonic scalpel,

ultrasonic blade, LigaSure, Doppler-guided hemorrhoidal artery ligation, and mucopexy (recto-anal repair) (5, 7, 9-12). The aim of these modifications is to decrease postoperative pain, reduce bleeding, make healing, and resumption of normal activities faster (9). But, still there is lack of guidelines and recommendations about the indications of these modifications adding confusion about the choices, which may put burden on healthcare resources (13).

During residency, patients cried out in pain at the time of removal of anal pack surgeons placed in the anal canal at the end of surgery. One patient had pinpoint anal stenosis one month postoperatively; he was operated for thrombosed piles without initial conservative treatment. Another patient bled profusely 12 hours after operation, and had to be returned to the operation theatre to secure the hemostasis. The survey among surgeons at the 19th National Surgery Congress about the most frequent complications encountered in routine general surgery cases showed that post-hemorrhoidectomy pain and hemorrhage were on the top; however, complications did not discourage the surgeons to perform the same operation again (14). The traditional Milligan-Morgan operation is still the most commonly performed operation for the third and fourth degree hemorrhoids (15).

The author's modification, triple hemostatic hemorrhoidectomy, is an attempt to reduce these postoperative complications in resource-limited settings where the expenses of circular stapler, ultrasonic blade, and LigaSure cannot be afforded. The current study aimed at comparing the outcome of traditional open hemorrhoidectomy with that of the modified approach in resource-limited settings.

2. Methods

An open randomized comparative study was conducted in phase I, at Fatima Hospital affiliated to Baqai Medical University from March 2009 to August 2011. It was followed by a descriptive case-series in phase II, conducted at different hospitals (Fatima, Shamsi, Nehal, Moazzum, and Prince Sattam-bin Abdulaziz University-hospitals), from September 2011 to August 2017. In phase I, the patients were enrolled in groups A or B using block randomization methods. Each block included two consecutive patients; the first patient was included in group A (operated by the author), and the second patient in group B (operated by any other surgeon of the hospital). The patients operated by other surgeons in between the blocks were excluded to balance the patient number in the two arms. However, it was also the limitation of the study that in group 'A' patients were operated by the author only (mastering one technique) and group 'B' patients operated by many surgeons (with different experiences and

skills). The other limitations include open study, small sample size, and only one-year follow-up.

The hypothesis was that the triple hemostatic hemorrhoidectomy would have better outcomes than traditional open hemorrhoidectomy. The amount of per-operative blood loss was the primary outcome variable; it was calculated by measuring the used swabs' weight. The other analyzed variables were demography, diagnosis, operative duration, pain visual analogue scores (at eight and 24 hours, as well as eighth, 15th, and 30th days), time to pain-free defecation, hospital stay, and complications. The study sample size was calculated using G-power computer software; the input parameters include medium (0.5) effect size, 0.05 α error, and 0.90 power to detect statistically significant differences ($P = 0.05$). It led to 86 patients in both groups with a total sample size of 172. Five patients were further added to each group anticipating drop-out of some cases, making a total of 182 patients in phase I. In phase II, which was a descriptive case-series, 231 patients were included and all of them were candidates to triple hemostatic hemorrhoidectomy. The inclusion criteria were patients of both genders and all age groups with third or fourth degree hemorrhoids requiring surgery. The exclusion criteria were patients in between blocks (operated by other surgeons), patients with complicated hemorrhoids, closed hemorrhoidectomy cases, cases operated by residents, and cases lost to follow-up.

Ethical approval was obtained from the ethics committee of Baqai Medical University (Karachi, Pakistan) in the beginning of the study. The informed consent was taken from all patients, and the study was conducted following the ethical standards of Helsinki declaration (1964) and its later amendments.

2.1. Operative Procedure

The spinal anesthesia was used in all cases. The antibiotic prophylaxis was given at induction, using 1 g ceftriaxone and 500 mg metronidazole, intravenously. All patients were operated in lithotomy position.

In groups A and C, anocutaneous junction was infiltrated with 1:200,000 adrenaline solution (first hemostasis), followed by gentle gauze compression. Digital rectal examination and proctoscopy were performed. Each hemorrhoid was grasped with artery forceps at the pedicle and at the distal end. V-shaped muco-cutaneous incision was given around each prolapsed hemorrhoid using cutting diathermy, followed by dissection of the hemorrhoids till its pedicle using coagulation diathermy (second hemostasis). The pedicle was transfixed using chromic catgut 2/0 suture and divided using coagulation diathermy (third hemostasis). After dealing with each hemorrhoid, proctoscopy was performed to exclude any bleeding. A small

4 × 4-cm gauze was placed at the anal orifice and secured by adhesive.

In contrast, there was no local anesthetic infiltration in group B cases. V-shaped incision was given with scissor, and hemostasis was secured with coagulation diathermy. The hemorrhoids were dissected with blunt gauze dissection, and excised after transfixing pedicles (5, 10). However, at the end of the procedure, anal canal packing was done using thick-rolled 2.5 × 10-cm gauze soaked in petroleum jelly, followed by T-bandage.

All patients received 50 mg diclofenac sodium, intramuscularly at eight hours postoperatively, followed by 50 mg oral diclofenac twice daily for three days. The gauze pieces (group A and C) or pack (group B) was either removed manually at eight hours postoperatively, or fall itself when the patient passed feces. Then, patients were immediately given hot sitz bath, and were advised to continue it three times daily for two weeks. The follow-ups were done at the eighth, 15th, and 30th days. Final follow-up was at one year, with instructions to report if any unexpected event happened, especially recurrence and stenosis. Operative duration was calculated from the time of local infiltration (or incision) to the wound dressing. Verbal rating scale (VRS) was used to assess the severity of pain perception. The statistical analysis was performed with SPSS version 24. The one-way ANOVA test (Duncan's method) was used to analyze the variables, with P value < 0.05 as the level of significance.

3. Results

Figure 1 shows the flow of patients during phase I. Overall, gender distribution consisted of 326 (79.7%) males and 83 (20.3%) females. The patients' mean age in group A, B, and C was 47.22 ± 7.798 years (range 28 - 62), 42.63 (SD 7.083, range 31 - 59) and 47.52 years (SD 7.500, range 28 - 66), respectively. Overall, associated diseases were found in 28.6% of the patients including diabetes mellitus (n = 63), hypertension (n = 38), chronic pulmonary disease (n = 14), and stable angina (n = 2).

Table 1 shows the group statistics using ANOVA test. The patients in group B had significantly more intra-operative blood loss ($P \leq 0.001$), and also had more prolonged operation ($P \leq 0.001$). They also had significantly higher pain VRS score at eight and 24 hours as well as eighth, 15th, and 30th days. Further, it took them significantly longer time to have pain-free defecation, and had slightly longer mean hospital stay. They also had higher complication rate (Table 2).

4. Discussion

In the current study, the overall gender distribution consisted of 326 (79.7%) males and 83 (20.3%) females. This may be attributed to the social culture where females are not feeling comfortable to expose their anogenital area to the male surgeons. Nikooiyan et al., reported more female patients than males (32 vs. 23), and majority of the patients belonged to 40 - 60 years age group (1). The patients' mean age in groups A, B, and C were 47.22 ± 7.798 years (ranged: 28 - 62), 42.63 ± 7.083 years (ranged: 31 - 59), and 47.52 ± 7.500 years (ranged: 28 - 66), respectively. One study reported the mean ages of 34.1 and 33.7 years for the two study groups (16). Lim et al., reported the mean ages of 20.8 and 22.4 years in the conventional and the ultrasonic scalpel groups, respectively (7).

In the current study, traditional open hemorrhoidectomy cases (group B) were associated with significantly more operative blood loss as well as more prolonged operative time and hospital stay compared with triple hemostatic hemorrhoidectomy groups (A and C). Also, the severity of pain based on VRS score at eight and 24 hours as well as eighth, 15th, and 30th days were significantly higher in group B. The wider pain score gap at eight hours was attributed to the use of anal packs in traditional open hemorrhoidectomy cases. Bakhtiar et al., reported longer mean operative time (52.5 vs. 36.6 minutes), but less mean blood loss (51.9 vs. 70.3 mL) and lower pain scores in hemorrhoidectomy by LigaSure compared with those of Milligan-Morgan hemorrhoidectomy (6). Fazeli et al., compared the results of LigaSure hemorrhoidectomy with those of the open conventional method and found significantly shorter operative time (8.91 vs. 17.35 minutes, $P \leq 0.001$) and also less post-operative pain VAS scores ($P = 0.077$) (17). LigaSure hemorrhoidectomy is considered better than traditional open surgery due to its potential advantages in reducing operative time and postoperative pain, faster healing and minimal complications, and recurrence rates (18). Izadpanah and Hosseini reported comparative analysis of Ferguson hemorrhoidectomy with electrotherapy in which hemorrhoidal tissue was not excised. In electrotherapy using 30 mA, 35% of patients had severe pain for six hours and 15% had mild pain for two to seven days postoperatively, while the mean procedure time was 6.1 minutes (vs. 23 minutes in the current study) (4). Electrotherapy with a direct current of 30 mA significantly reduced the postoperative pain and the recovery period (1). Tsunoda et al., compared the results of hemorrhoidectomy using bipolar diathermy and ultrasonic scalpel; they found less per-operative blood loss (median 0.9 vs. 4.6 mL), short operative time (median 16 vs. 31 minutes), and less pain on the first postoperative day (median two vs. three days) with

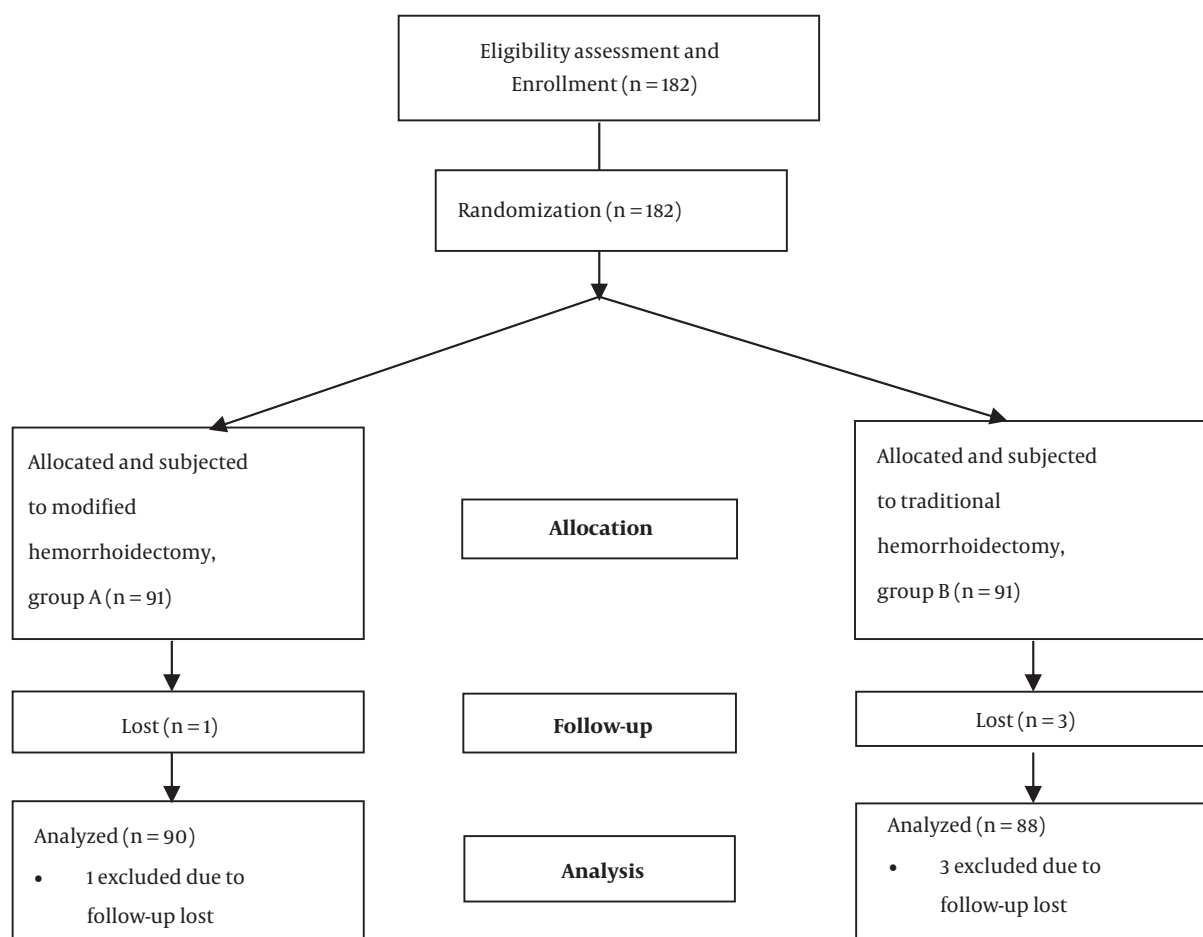


Figure 1. The phase I flow diagram showing patients' flow at different stages

bipolar diathermy hemorrhoidectomy (19). Another study reported advantages of Kshara Sutra ligation in comparison with those of hemorrhoidectomy in reduced hospital stay, no intra- or post-operative bleeding, no anal stenosis, and cost-effectiveness (20). Another study comparing harmonic scalpel and the Ferguson electrocautery hemorrhoidectomy reported average postoperative stay of 1.0 vs. 1.2 days, mean operating time of 16.8 minutes vs. 25.5 minutes, less blood loss, less postoperative pain, and fewer complications (16). Two studies reported less postoperative pain in dearterialization with mucopexy compared with hemorrhoidectomy (21, 22). Lin et al., reported efficacy of anal-cushion suspension clamp in combination with harmonic scalpel; duration of operation, intraoperative blood loss, postoperative pain, and hospital stay were significantly less compared with Milligan-Morgan hemorrhoidectomy (3). Maloku et al., reported hemorrhoid laser procedure in which hemorrhoidal arterial inflow was

stopped by laser coagulation, with procedure time of 15.94 vs. 26.76 minutes for open surgical hemorrhoidectomy (23). Armstrong et al., found significantly less postoperative pain with harmonic scalpel compared with electrocautery hemorrhoidectomy (24).

In the current study, groups A and C patients (modified hemorrhoidectomy) took significantly less time to have pain-free defecation. Basdanis et al., compared the results of open hemorrhoidectomy using LigaSure with stapled hemorrhoidectomy, and found shorter operative time (median 13 vs. 15 minutes), but higher postoperative pain VAS score (5 vs. 3 at eight and seven hours vs. five hours after first defecation); intraoperative bleeding occurred in 18 cases of stapled group vs. four cases of the LigaSure group (9). However, Palimento et al., reported shorter operative time for stapled hemorrhoidectomy (median 25 vs. 30 minutes), as well as less pain VAS (4 vs. 5 at four hours, 3 vs. 5 at 24 hours, and 5 vs. 7 after the first defe-

Table 1. The Analysis of Studied Variables^a

Variable	No.	Mean	SD	SE	95% Confidence Interval for Mean		Sig. (2-Tailed)
					Lower Bound	Upper Bound	
Per-operative blood loss, mL							< 0.001
Group A	90	9.369	2.4263	0.2558	8.861	9.877	
Group B	88	17.360	2.9050	0.3097	16.745	17.976	
Group C	231	7.774	1.8685	0.1229	7.531	8.016	
Operative time, min							< 0.001
Group A	90	15.0044	2.97041	0.31311	14.3823	15.6266	
Group B	88	20.8455	5.22219	0.55669	19.7390	21.9519	
Group C	231	16.7935	4.20066	0.27638	16.2489	17.3381	
Pain score at 8 hours							< 0.001
Group A	90	3.86	0.680	0.072	3.71	4.00	
Group B	88	6.80	1.019	0.109	6.58	7.01	
Group C	231	3.98	0.682	0.045	3.89	4.07	
Pain score at 24 hours							< 0.001
Group A	90	3.23	0.671	0.071	3.09	3.37	
Group B	88	4.15	0.653	0.070	4.01	4.29	
Group C	231	3.08	0.742	0.049	2.98	3.17	
Pain score at 8th day							< 0.001
Group A	90	1.86	0.572	0.060	1.74	1.98	
Group B	88	2.91	0.753	0.080	2.75	3.07	
Group C	231	1.50	0.697	0.046	1.41	1.59	
Pain score at 15th day							< 0.001
Group A	90	0.52	0.565	0.060	0.40	0.64	
Group B	88	1.77	0.673	0.072	1.63	1.92	
Group C	231	0.30	0.514	0.034	0.24	0.37	
Pain score at 30th day							0.001
Group A	90	0.00	0.000	0.000	0.00	0.00	
Group B	88	0.06	0.233	0.025	0.01	0.11	
Group C	231	0.00	0.066	0.004	0.00	0.01	
Pain-free defecation, days							< 0.001
Group A	90	16.85	3.494	0.368	16.12	17.59	
Group B	88	20.22	3.732	0.398	19.43	21.01	
Group C	231	16.76	3.233	0.213	16.34	17.18	
Hospital stay, days							< 0.001
Group A	90	1.00	0.000	0.000	1.00	1.00	
Group B	88	1.28	0.454	0.048	1.19	1.38	
Group C	231	1.00	0.000	0.000	1.00	1.00	

^aDuncan's method with equal variances was assumed.

cation) and faster resumption of pain-free defecation (10 vs. 12 days, $P = 0.001$); they found no postoperative com-

plications related to continence and defecation in either group (25). Though the short-term results of stapled hem-

Table 2. Comparative Analysis of Complications

Variable	Complication	Group A (N = 90)	Group B (N = 88)	Group C (N = 231)	P Value
Preoperative complication	Hemorrhage	0	4	0	< 0.001
	Anal sphincter injury	0	0	0	
	Loss of > 50% mucosal bridge	0	3	0	
	Hemorrhage	3	12	10	
Post-operative complication	Urinary retention	8	2	21	0.002
	Wound infection	2	2	0	
	Anal stenosis	0	0	0	
	Impacted feces	0	1	0	
	Flatus incontinence	0	1	0	

orrhoidopexy, being less painful, appeared better than the traditional excisional hemorrhoidectomy, but the latter gives better long-term results as many of the stapled cases were left with persistent symptoms of prolapse and itching in the fourth degree hemorrhoids (2, 26, 27). The current study found higher complication rate in traditional open hemorrhoidectomy cases. Wang et al., reported 55 (7.45%) cases of postoperative complications in their series of the modified Ferguson hemorrhoidectomy; this included postoperative bleeding (n = 16), fecal impaction (n = 11), wound complications (n = 6), and acute urinary retention (n = 32) (28).

Another study reported that ultrasonic scalpel in comparison with the conventional methods had a shorter operative time, less postoperative pain, and less postoperative bleeding; however, no significant differences were observed in postoperative complications (7). In another modification, ligation under vision, the pedicle of hemorrhoids was transfixed with absorbable sutures; this offers advantages in cases of large hemorrhoids when excision may result in larger mucosal defects, with consequent anal stenosis (29). Anal sphincter injury with consequent flatus/fecal incontinence is one of the known complications of hemorrhoidectomy. A study examined all resected materials histopathologically, which revealed muscle fibers in 15.8% cases (smooth 80.5%, striated 19.5%) (30). There was one case of flatus incontinence in group B patients, while none in groups A and C. This is mainly because of local adrenaline infiltration, which makes operative field virtually bloodless and clear; thus, avoids injury to muscle fibers. However, there were more cases of urinary retention in groups A and C; this may be due to the fact that these patients were on an average five years older than those of group B.

Anal sphincter spasm contributes to the appearance of postoperative pain following hemorrhoidectomy (31). Different studies reported pain perception with topical treat-

ment to reduce postoperative pain. One study comparing topical diltiazem and placebo found pain VRS mean score of 2.97 vs. 6.82 at 24 hours, 1.51 vs. 5.3 at 48 hours, and 0.84 vs. 4.32 at 72 hours (31). Sucralfate 10% ointment also was used to reduce the acute postoperative pain after hemorrhoidectomy. Similarly, cholestyramine 15% ointment found to reduce postoperative pain at rest and on defecation (32). The study did not use any of these therapies, as it may alter the comparative postoperative pain scores.

4.1. Conclusion

Triple hemostatic hemorrhoidectomy offers advantages over traditional open hemorrhoidectomy due to less operative and postoperative blood losses, shorter operative time, less postoperative pain, less postoperative complications, reduced hospital stay, and less time to pain-free defecation.

Footnotes

Conflict of Interest: Authors declared no conflict of interests.

Implication of the Study: The study reflected the current matching standards of one of the common general surgery procedures in a resource limited setting without the use of sophisticated costly instruments and modalities. A comparable satisfactory outcome for hemorrhoidectomy can be achieved with the simplest operating gadgets available in any general surgery operation theatre.

References

1. Nikooiyan P, Mohammadi Sardo H, Poursaeidi B, Zaherara M, Ahmadi B. Evaluating the safety, efficacy and complications of electrotherapy and its comparison with conventional method of hemorrhoidectomy. *Gastroenterol Hepatol Bed Bench.* 2016;9(4):259-67. [PubMed: 27895851]. [PubMed Central: PMC5118850].

2. Watson AJ, Hudson J, Wood J, Kilnzo M, Brown SR, McDonald A, et al. Comparison of stapled haemorrhoidopexy with traditional excisional surgery for haemorrhoidal disease (eTHoS): a pragmatic, multicentre, randomised controlled trial. *Lancet*. 2016;**388**(10058):2375–85. doi: [10.1016/S0140-6736\(16\)31803-7](https://doi.org/10.1016/S0140-6736(16)31803-7). [PubMed: [27726951](https://pubmed.ncbi.nlm.nih.gov/27726951/)]. [PubMed Central: [PMC5269572](https://pubmed.ncbi.nlm.nih.gov/PMC5269572/)].
3. Lin G, Ge Q, He X, Qi H, Xu L. A novel technique for the treatment of stages III to IV hemorrhoids: Homemade anal cushion suspension clamp combined with harmonic scalpel. *Medicine (Baltimore)*. 2017;**96**(26). e7309. doi: [10.1097/MD.00000000000007309](https://doi.org/10.1097/MD.00000000000007309). [PubMed: [28658138](https://pubmed.ncbi.nlm.nih.gov/28658138/)]. [PubMed Central: [PMC5500060](https://pubmed.ncbi.nlm.nih.gov/PMC5500060/)].
4. Izadpanah A, Hosseini SV. Comparison of electrotherapy of hemorrhoids and Ferguson hemorrhoidectomy in a randomized prospective study. *Int J Surg*. 2005;**3**(4):258–62. doi: [10.1016/j.ijvs.2005.09.002](https://doi.org/10.1016/j.ijvs.2005.09.002). [PubMed: [17462295](https://pubmed.ncbi.nlm.nih.gov/17462295/)].
5. Mott T, Latimer K, Edwards C. Hemorrhoids: Diagnosis and Treatment Options. *Am Fam Physician*. 2018;**97**(3):172–9. [PubMed: [29431977](https://pubmed.ncbi.nlm.nih.gov/29431977/)].
6. Bakhtiar N, Moosa FA, Jaleel F, Qureshi NA, Jawaid M. Comparison of hemorrhoidectomy by LigaSure with conventional Milligan Morgan's hemorrhoidectomy. *Pak J Med Sci*. 2016;**32**(3):657–61. doi: [10.12669/pjms.323.9976](https://doi.org/10.12669/pjms.323.9976). [PubMed: [27375709](https://pubmed.ncbi.nlm.nih.gov/27375709/)]. [PubMed Central: [PMC4928418](https://pubmed.ncbi.nlm.nih.gov/PMC4928418/)].
7. Lim DR, Cho DH, Lee JH, Moon JH. Comparison of a Hemorrhoidectomy With Ultrasonic Scalpel Versus a Conventional Hemorrhoidectomy. *Ann Coloproctol*. 2016;**32**(3):111–6. doi: [10.3393/ac.2016.32.3.111](https://doi.org/10.3393/ac.2016.32.3.111). [PubMed: [27437393](https://pubmed.ncbi.nlm.nih.gov/27437393/)]. [PubMed Central: [PMC4942526](https://pubmed.ncbi.nlm.nih.gov/PMC4942526/)].
8. Sayfan J, Becker A, Koltun L. Sutureless closed hemorrhoidectomy: a new technique. *Ann Surg*. 2001;**234**(1):21–4. doi: [10.1097/00000658-200107000-00004](https://doi.org/10.1097/00000658-200107000-00004). [PubMed: [11420479](https://pubmed.ncbi.nlm.nih.gov/11420479/)]. [PubMed Central: [PMC1421943](https://pubmed.ncbi.nlm.nih.gov/PMC1421943/)].
9. Basdanis G, Papadopoulos VN, Michalopoulos A, Apostolidis S, Harlaftis N. Randomized clinical trial of stapled hemorrhoidectomy vs open with Ligasure for prolapsed piles. *Surg Endosc*. 2005;**19**(2):235–9. doi: [10.1007/s00464-004-9098-0](https://doi.org/10.1007/s00464-004-9098-0). [PubMed: [15573239](https://pubmed.ncbi.nlm.nih.gov/15573239/)].
10. van Tol RR, Bruijnen MPA, Melenhorst J, van Kuijk SMJ, Stassen LPS, Breukink SO. A national evaluation of the management practices of hemorrhoidal disease in the Netherlands. *Int J Colorectal Dis*. 2018;**33**(5):577–88. doi: [10.1007/s00384-018-3019-5](https://doi.org/10.1007/s00384-018-3019-5). [PubMed: [29546558](https://pubmed.ncbi.nlm.nih.gov/29546558/)]. [PubMed Central: [PMC5899108](https://pubmed.ncbi.nlm.nih.gov/PMC5899108/)].
11. Kendirci M, Sahiner IT, Sahiner Y, Guney G. Comparison of Effects of Vessel-Sealing Devices and Conventional Hemorrhoidectomy on Postoperative Pain and Quality of Life. *Med Sci Monit*. 2018;**24**:2173–9. doi: [10.12659/MSM.909750](https://doi.org/10.12659/MSM.909750). [PubMed: [29643327](https://pubmed.ncbi.nlm.nih.gov/29643327/)]. [PubMed Central: [PMC5914273](https://pubmed.ncbi.nlm.nih.gov/PMC5914273/)].
12. Pagano C, Vergani C, Invernizzi C, Bussone M, Benegiamo G, Venturi M. Mucopexy-Recto Anal Lifting (Mu-RAL): a standardized minimally invasive method of managing symptomatic hemorrhoids, with an innovative suturing technique and the HemorPex System(R). *Minerva Chir*. 2018. doi: [10.23736/S0026-4733.18.07425-4](https://doi.org/10.23736/S0026-4733.18.07425-4). [PubMed: [29652112](https://pubmed.ncbi.nlm.nih.gov/29652112/)].
13. Gaj F, Trecca A, Garbarino M, Flati G. [Transfixed stitches for the treatment of haemorrhoids]. *Chir Ital*. 2004;**56**(5):699–703. [PubMed: [15553443](https://pubmed.ncbi.nlm.nih.gov/15553443/)].
14. Gemici K, Okus A, Yildiz M, Sahin M, Bilgi M. A surgeon's nightmare: Complications. *Ulus Cerrahi Derg*. 2015;**31**(2):90–1. doi: [10.5152/UCD.2015.2785](https://doi.org/10.5152/UCD.2015.2785). [PubMed: [26170757](https://pubmed.ncbi.nlm.nih.gov/26170757/)]. [PubMed Central: [PMC4485819](https://pubmed.ncbi.nlm.nih.gov/PMC4485819/)].
15. Giannini I, Pecorella G, Pennisi D, Santangelo G, Digennaro R, Latorre F, et al. Control of post-hemorrhoidectomy symptoms and wound healing by Triclosan: a randomized, double-blind, controlled trial. *Minerva Chir*. 2014;**69**(2):75–82. [PubMed: [24847894](https://pubmed.ncbi.nlm.nih.gov/24847894/)].
16. Bulus H, Tas A, Coskun A, Kucukazman M. Evaluation of two hemorrhoidectomy techniques: harmonic scalpel and Ferguson's with electrocautery. *Asian J Surg*. 2014;**37**(1):20–3. doi: [10.1016/j.asjsur.2013.04.002](https://doi.org/10.1016/j.asjsur.2013.04.002). [PubMed: [23726831](https://pubmed.ncbi.nlm.nih.gov/23726831/)].
17. Fazeli MS, Safari S, Kazemeini A, Larti F, Joneidi E, Rahimi M. A prospective study comparing ligasure and open hemorrhoidectomy. *Tehran Univ Med J*. 2011;**69**(8):495–501.
18. Sakr MF. LigaSure versus Milligan-Morgan hemorrhoidectomy: a prospective randomized clinical trial. *Tech Coloproctol*. 2010;**14**(1):13–7. doi: [10.1007/s10151-009-0549-4](https://doi.org/10.1007/s10151-009-0549-4). [PubMed: [19997953](https://pubmed.ncbi.nlm.nih.gov/19997953/)].
19. Tsunoda A, Sada H, Sugimoto T, Kano N, Kawana M, Sasaki T, et al. Randomized controlled trial of bipolar diathermy vs ultrasonic scalpel for closed hemorrhoidectomy. *World J Gastrointest Surg*. 2011;**3**(10):147–52. doi: [10.4240/wjgs.v3.i10.147](https://doi.org/10.4240/wjgs.v3.i10.147). [PubMed: [22110846](https://pubmed.ncbi.nlm.nih.gov/22110846/)]. [PubMed Central: [PMC3220727](https://pubmed.ncbi.nlm.nih.gov/PMC3220727/)].
20. Gupta ML, Gupta SK, Bhuyan C. Comparative clinical evaluation of Kshara Sutra ligation and hemorrhoidectomy in Arsha (hemorrhoids). *Ayu*. 2011;**32**(2):225–9. doi: [10.4103/0974-8520.92591](https://doi.org/10.4103/0974-8520.92591). [PubMed: [22408307](https://pubmed.ncbi.nlm.nih.gov/22408307/)]. [PubMed Central: [PMC3296345](https://pubmed.ncbi.nlm.nih.gov/PMC3296345/)].
21. Denoya P, Tam J, Bergamaschi R. Hemorrhoidal dearterialization with mucopexy versus hemorrhoidectomy: 3-year follow-up assessment of a randomized controlled trial. *Tech Coloproctol*. 2014;**18**(11):1081–5. doi: [10.1007/s10151-014-1219-8](https://doi.org/10.1007/s10151-014-1219-8). [PubMed: [25248418](https://pubmed.ncbi.nlm.nih.gov/25248418/)]. [PubMed Central: [PMC4246126](https://pubmed.ncbi.nlm.nih.gov/PMC4246126/)].
22. De Nardi P, Capretti G, Corsaro A, Staudacher C. A prospective, randomized trial comparing the short- and long-term results of doppler-guided transanal hemorrhoid dearterialization with mucopexy versus excision hemorrhoidectomy for grade III hemorrhoids. *Dis Colon Rectum*. 2014;**57**(3):348–53. doi: [10.1097/DCR.0000000000000085](https://doi.org/10.1097/DCR.0000000000000085). [PubMed: [24509458](https://pubmed.ncbi.nlm.nih.gov/24509458/)].
23. Maloku H, Gashi Z, Lazovic R, Islami H, Juniku-Shkololli A. Laser Hemorrhoidoplasty Procedure vs Open Surgical Hemorrhoidectomy: a Trial Comparing 2 Treatments for Hemorrhoids of Third and Fourth Degree. *Acta Inform Med*. 2014;**22**(6):365–7. doi: [10.5455/aim.2014.22.365-367](https://doi.org/10.5455/aim.2014.22.365-367). [PubMed: [25684841](https://pubmed.ncbi.nlm.nih.gov/25684841/)]. [PubMed Central: [PMC4315650](https://pubmed.ncbi.nlm.nih.gov/PMC4315650/)].
24. Armstrong DN, Ambrose WL, Schertzer ME, Orangio GR. Harmonic Scalpel vs. electrocautery hemorrhoidectomy: a prospective evaluation. *Dis Colon Rectum*. 2001;**44**(4):558–64. doi: [10.1007/BF02234329](https://doi.org/10.1007/BF02234329). [PubMed: [11330583](https://pubmed.ncbi.nlm.nih.gov/11330583/)].
25. Palimento D, Picchio M, Attanasio U, Lombardi A, Bambini C, Renda A. Stapled and open hemorrhoidectomy: randomized controlled trial of early results. *World J Surg*. 2003;**27**(2):203–7. doi: [10.1007/s00268-002-6459-5](https://doi.org/10.1007/s00268-002-6459-5). [PubMed: [12616437](https://pubmed.ncbi.nlm.nih.gov/12616437/)].
26. Lloyd D, Ho KS, Seow-Choen F. Modified Longo's hemorrhoidectomy. *Dis Colon Rectum*. 2002;**45**(3):416–7. doi: [10.1007/s10350-004-6193-1](https://doi.org/10.1007/s10350-004-6193-1). [PubMed: [12068205](https://pubmed.ncbi.nlm.nih.gov/12068205/)].
27. Ortiz H, Marzo J, Armendariz P, De Miguel M. Stapled hemorrhoidopexy vs. diathermy excision for fourth-degree hemorrhoids: a randomized, clinical trial and review of the literature. *Dis Colon Rectum*. 2005;**48**(4):809–15. doi: [10.1007/s10350-004-0861-z](https://doi.org/10.1007/s10350-004-0861-z). [PubMed: [15785901](https://pubmed.ncbi.nlm.nih.gov/15785901/)].
28. Wang LT, Wu CC, Hsiao CW, Feng CC, Jao SW. A modified Ferguson hemorrhoidectomy for circumferential prolapsed hemorrhoids with skin tags. *Dis Colon Rectum*. 2008;**51**(4):456–61. doi: [10.1007/s10350-007-9179-y](https://doi.org/10.1007/s10350-007-9179-y). [PubMed: [18213490](https://pubmed.ncbi.nlm.nih.gov/18213490/)].
29. Demir H, Karaman K, Ercan M, Kocer HB, Celebi F. Comparison of two procedures for symptomatic hemorrhoidal disease: Ligation under Vision and Ferguson Hemorrhoidectomy - a retrospective cohort study. *Pak J Med Sci*. 2017;**33**(1):90–5. doi: [10.12669/pjms.331.11266](https://doi.org/10.12669/pjms.331.11266). [PubMed: [28367179](https://pubmed.ncbi.nlm.nih.gov/28367179/)]. [PubMed Central: [PMC5368337](https://pubmed.ncbi.nlm.nih.gov/PMC5368337/)].
30. Mirzaei R, Mahjoubi B, Kadivar M, Azizi R, Zahedi-Shoolami L. Anal sphincter injuries during hemorrhoidectomy: a multi center study. *Acta Med Iran*. 2012;**50**(9):632–4. [PubMed: [23165814](https://pubmed.ncbi.nlm.nih.gov/23165814/)].
31. Rodriguez-Wong U, Ocharan-Hernandez ME, Toscano-Garibay J. Topical diltiazem for pain after closed hemorrhoidectomy. *Rev Gastroenterol Mex*. 2016;**81**(2):74–9. doi: [10.1016/j.rgmx.2016.02.001](https://doi.org/10.1016/j.rgmx.2016.02.001). [PubMed: [26980264](https://pubmed.ncbi.nlm.nih.gov/26980264/)].
32. Ala S, Eshghi F, Enayatifard R, Fazel P, Rezaei B, Hadianamrei R. Efficacy of cholestyramine ointment in reduction of postoperative pain and pain during defecation after open hemorrhoidectomy: results

of a prospective, single-center, randomized, double-blind, placebo-controlled trial. *World J Surg.* 2013;**37**(3):657-62. doi: [10.1007/s00268-](https://doi.org/10.1007/s00268-012-1895-3)

[012-1895-3](https://doi.org/10.1007/s00268-012-1895-3). [PubMed: [23229850](https://pubmed.ncbi.nlm.nih.gov/23229850/)].