



Eventration of Diaphragm with Chronic Constipation: An Unusual Presentation: A Case Report

Ashwin Porwal,^{1*} and Paresh Gandhi²

¹Designation - Consultant Colo Rectal Surgeon, Institution - Healing Hands Clinic, 105, Mangalmurti Complex, Near Hirabaug, Tilak Road, Pune

²Consulting Surgeon, Healing Hands Clinic

*Corresponding author: Ashwin Porwal, Designation - Consultant Colo Rectal Surgeon, Institution - Healing Hands Clinic, 105, Mangalmurti Complex, Near Hirabaug, Tilak Road, Pune. Tel: +91-982234777, E-mail: drashwinporwal@healinghandsclinic.co.in

Received 2017 April 02; Revised 2017 May 08; Accepted 2017 June 06.

Abstract

Diaphragmatic eventration (DE) or eventration of the diaphragm is characterized by a permanent high position of 1 or rarely both the leaflets of the diaphragm, providing a potential space for the displacement of abdominal viscera on the affected side(s). It is a relatively rare condition with unknown etiology in adults. Prevalence of DE is less than 0.05% of the population, both children and adults, and is more common in males. There is a various presentation for DE and patients are mostly asymptomatic. The diagnosis of DE is vital to avoid certain serious, though rare, complications such as gastric or colon volvulus. Here is the report of an unusual presentation of eventration of the diaphragm with sigmoid colon volvulus presented with complaint of chronic constipation and 'fear to eat'. Patient was diagnosed in the operating room despite multiple imaging modalities. Eventration of diaphragm and cachexia is a rare association and to the best of authors' knowledge, it is not reported in literature. It is hoped that the current case report sensitizes physicians to the unusual presentation of eventration of diaphragm.

Keywords: Chronic Constipation, Eventration of Diaphragm, Plication of Diaphragm, Mediastinal Shift, Sigmoid Volvulus

1. Introduction

Eventration of the diaphragm is a relatively rare condition with unknown etiology in adults. It is characterized by a permanent high position of 1 or rarely both the leaflets of the diaphragm, providing a potential space for the displacement of abdominal viscera on the affected side (s) (1). The etiology, diagnosis, and management of this condition remain a controversial issue. Here it is the report of a rare case of cachexia in a patient with eventration of the diaphragm and sigmoid colon volvulus presented with complaint of 'fear to eat' and chronic constipation. Even though most of the modern diagnostic techniques were used, the case was diagnosed on the operation table.

This unusual association was not reported in the literature, although similar findings with different presentation in a case of esophageal adenocarcinoma arising from the Barrett esophagus in association with eventration of the diaphragm were reported previously.

This case again highlighted the varied associations of an eventration of the diaphragm.

2. Case Presentation

A 39-year-old Muslim male from Yemen, studied up to the 12th standard referred to the outpatient department with complaints of heaviness in the abdomen after meals, scared to eat since 3 months and history of loss of appetite, as well as constipation since last year. He lost 50 kg weight in the last year. He was nonsmoker, nonalcoholic, known hypertensive since 3 years ago, and was on medication. There was no significant history. General physical examination was normal. The patient was afebrile at the time of presentation. Respiratory rate (RR), pulse rate (PR), and blood pressure (BP) were within normal limits.

Hematogram report showed increased monocyte count (12.3%); the absolute basophil count was 0. Serum potassium level was 2.8 mM/L. Liver function test (LFT), blood sugar level (BSL), and other parameters were within normal limits.

Chest X-ray (CXR) showed raised dome of left diaphragm due to the superior displacement of abdominal viscera (gut loops) into diaphragmatic out pouching (Figure 1).

The 2-D echocardiogram was unremarkable. Gastroscopy revealed that esophagus, stomach, and duodenum were normal. Plain and contrast computed tomogra-

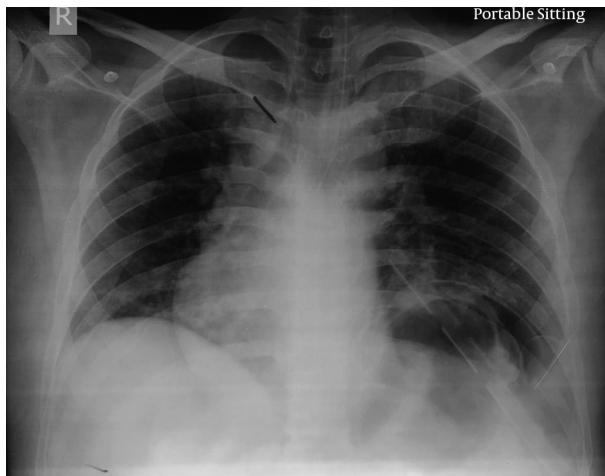


Figure 1. CXR Showing Abdominal Outpouching

phy (CT) scan of chest and whole abdomen showed shift of mediastinum toward right side with collapse of left lower lobe and fissural effusion in upper lobe (Figure 2). There was no evidence of pleural thickening or effusion. Cardiac chamber was normal.

Abdominal scan showed unclear left dome of diaphragm indicating left diaphragmatic hernia/eventration or herniation of colon, most probably through esophageal hiatus. There was evidence of volvulus, enlarged transverse colon, small umbilical hernia, and few enlarged lymph nodes.

Intraoperative colonoscopy to decompress dilated colon was done successfully. On diagnostic laparoscopy, there was evidence of eventration of left hemi diaphragm with migration of stomach fundus, spleen, and dilated left colon into the left thoracic cavity. Left subcostal incision deepened to open peritoneum (Figure 3). Diaphragmatic contents were reduced. Plication of left diaphragm with prolene 1-0 was done. Sigmoid colon was resected in view of long redundant mesentery with dilated colon (Figure 4). Staple colorectal anastomosis was done. Left side intercostal chest drainage tube was kept and closure was done.

Drain was placed and fixed, closure was done in layers, and the Lord dilatation was done. Umbilical hernia was repaired with sutures.

Patient had pain and discomfort for 3 days during the postoperative period. Oral feeding was started on the 3rd postoperative day (POD). Intercostal chest drainage tube and abdominal drain were removed on the 7th POD. CXR repeated on the days 3 and 7 and showed improved lung capacity and normal position of mediastinum.

Patient was discharged on the 8th POD. Prognosis after

1 month was good. Patient gained 18 kg weight in 3 months post operatively.

3. Discussion

Diaphragmatic eventration is an unusual elevation of 1 dome of diaphragm without any abnormality of continuity. Diaphragm has normal insertion of muscles, peritoneal and pleural layers, and the orifices are sealed normally. In eventration, either most part or whole diaphragm is composed of fibrous tissue with or without scattered fibers of muscles (2). Eventration in older children and in adults is usually caused by diaphragmatic palsy. It can be complete or partial. Complete eventration usually occurs on the left side, while right side eventration is rare (3).

Diaphragmatic eventration has a wide spectrum of clinical presentations. It mostly depends on the type of eventration, degree of elevation, and the elasticity and functioning of the diaphragmatic dome.

Elevation of diaphragm per se is usually found by chance during CXR done for other purposes and patients are usually asymptomatic (2, 4, 5). The cause of this elevation may be diaphragmatic paralysis or diaphragmatic eventration (6). Eventration of diaphragm is a congenital condition where there is absence or scarcity of muscle fibers in the diaphragm, but the muscle insertions and natural orifices are normal (7). Histologically, the specimen of diaphragm shows fibroelastic changes replacing the muscle tissue layer between pleural and peritoneal layers, while the 3-layered structure of diaphragm is maintained; this differentiates it from congenital diaphragmatic hernia and diaphragmatic paralysis (8).

The clinical presentation of diaphragmatic eventration varies widely from completely asymptomatic to dyspnea or orthopnea. Respiratory symptoms are due to difficulty in movement of affected diaphragm during respiration, which eventually leads to decreased ventilation and lack of oxygen. Gastrointestinal (GI) symptoms of diaphragmatic eventration may include nausea, heartburn, early satiety, postprandial vomiting, and epigastric discomfort (1).

The acute gastric volvulus presented with characteristic symptoms of retching, constant, and severe gastric pain, and difficulty in passing the nasogastric tube (as stated by Borchartd in 1904) (1, 9).

Carter et al. (10) suggested triad of findings of gastric volvulus viz. minimal abdominal findings when the stomach is in the thorax, and a gas-filled viscous in the lower chest or upper abdomen on chest radiograph and obstruction at the site of the volvulus shown by upper GI series. Pa-

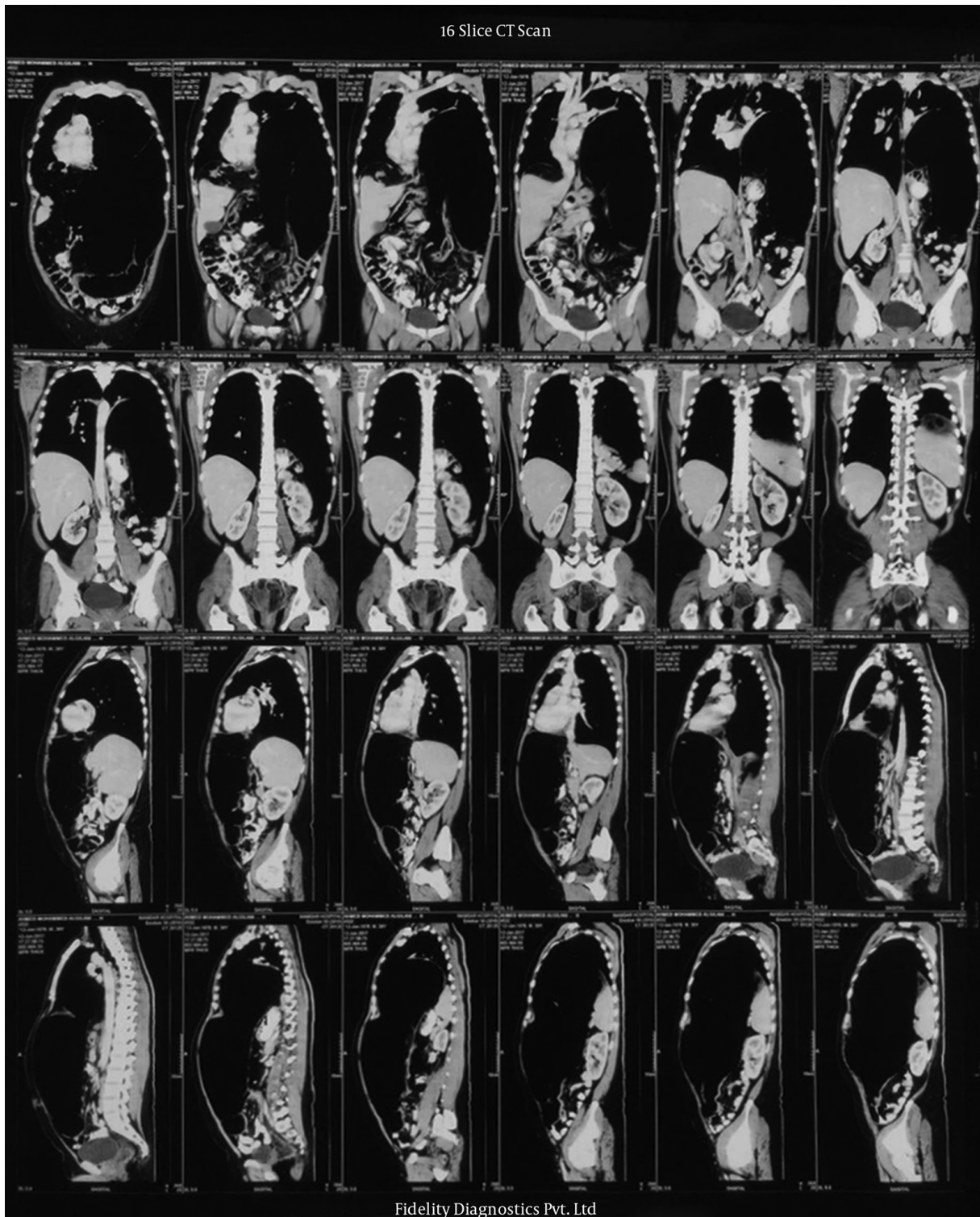


Figure 2. CT Scan Report

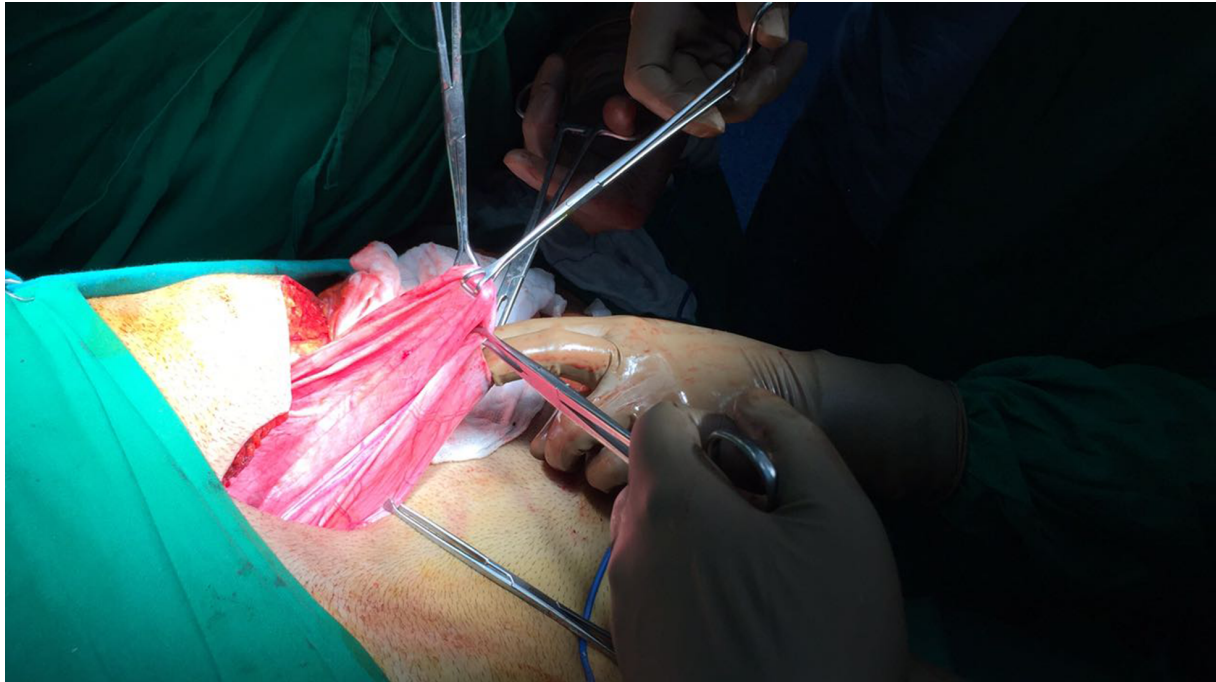

Figure 3. Left Subcostal Incision

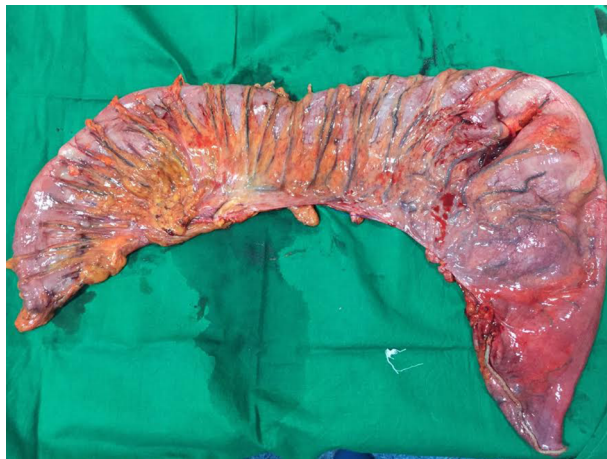

Figure 4. Resected Sigmoid Colon

tients may exhibit nonspecific GI symptoms including epigastric discomfort, belching, etc. (11).

Life-threatening complications such as stomach volvulus (12), rupture of eventrated diaphragm (13) with trivial trauma, and acute progressive respiratory distress (14) are also rarely reported.

For asymptomatic patients, an additional assessment is required, while in symptomatic patients surgical correction is necessary.

Cachexia (with Greek origin as kakos “bad” and hexis “condition”) or wasting syndrome is loss of weight, muscle atrophy, fatigue, weakness, and significant loss of appetite in the one who is not actively trying to lose weight (15). It is observed in patients with many communicable, non-communicable, and congenital complications. The most prevalent cause of cachexia is carcinoma.

In the current care report, cachexia and “fear to eat” were the presenting symptoms with the history of constipation and heaviness in abdomen after meals. Patient did not have any respiratory complaints. A shift of mediastinum and collapse of left lower lobe was observed in plain and contrast CT scan of the chest. The presence of a mediastinal shift, non-homogenous shadow in thoracic cavity (can be attributed to bowel shadow), and absence of respiratory complaints should have led the clinicians to consider other diagnoses.

Clinical presentation of eventration of diaphragm is usually vague and misleading. In spite of proper evaluation by multiple imaging modalities, the diagnosis is difficult. Differentiation of eventration from herniation of colon was difficult in the current case. Surgical assessment is necessary when the diagnosis is subtle or uncertain, as in the current case.

The current case again emphasized the varied associations as well as unusual presentation of an eventration of the diaphragm.

3.1. Conclusion

To the best of authors' knowledge, no case of unusual presentation of eventration of diaphragm with volvulus of sigmoid colon and chronic constipation was previously reported in the literature. Authors hope that the present communication sensitizes physicians to the unusual presentation of eventration of the diaphragm; the knowledge of which may be vital in diagnosis and avoiding certain serious, though rare, complications such as gastric or colon volvulus.

Acknowledgments

Authors would like to thank Dr. Manisha Jadhav, the director of healing hands clinical research, Pune, and Dr. Swapna S. Kadam, the consultant of healing hands clinical research, Pune, India, for the review and suggestions. Authors would also like to thank the team of healing hands clinic, Pune.

References

1. Shafiq S, Ramathilakam B. Eventration of diaphragm with a rare association. *J Dig Endosc.* 2014;5(1):30-2. doi: [10.4103/0976-5042.141934](https://doi.org/10.4103/0976-5042.141934).
2. Mouroux J, Venissac N, Leo F, Alifano M, Guillot F. Surgical treatment of diaphragmatic eventration using video-assisted thoracic surgery: a prospective study. *Ann Thorac Surg.* 2005;79(1):308-12. doi: [10.1016/j.athoracsur.2004.06.050](https://doi.org/10.1016/j.athoracsur.2004.06.050). [PubMed: [15620964](https://pubmed.ncbi.nlm.nih.gov/15620964/)].
3. Seaton A. Abnormalities and diseases of diaphragm. In: Seaton A, Seaton D, Leitch AG, editors. *Crofton and Douglas's Respiratory Diseases*. 5th ed. Blackwell Science, Oxford; 2000. 1234 p. doi: [10.1002/9780470695999.ch46](https://doi.org/10.1002/9780470695999.ch46).
4. Groth SS, Andrade RS. Diaphragm plication for eventration or paralysis: a review of the literature. *Ann Thorac Surg.* 2010;89(6):S2146-50. doi: [10.1016/j.athoracsur.2010.03.021](https://doi.org/10.1016/j.athoracsur.2010.03.021). [PubMed: [20493999](https://pubmed.ncbi.nlm.nih.gov/20493999/)].
5. Calvino P, Bastos C, Bernardo JE, Eugenio L, Antunes MJ. Diaphragmatic eventration: long-term follow-up and results of open-chest plication. *Eur J Cardiothorac Surg.* 2009;36(5):883-7. doi: [10.1016/j.ejcts.2009.05.037](https://doi.org/10.1016/j.ejcts.2009.05.037). [PubMed: [19632127](https://pubmed.ncbi.nlm.nih.gov/19632127/)].
6. Ribet M, Linder JL. Plication of the diaphragm for unilateral eventration or paralysis. *Eur J Cardiothorac Surg.* 1992;6(7):357-60. doi: [10.1016/1010-7940\(92\)90172-T](https://doi.org/10.1016/1010-7940(92)90172-T). [PubMed: [1497927](https://pubmed.ncbi.nlm.nih.gov/1497927/)].
7. Deslauriers J. Eventration of the diaphragm. *Chest Surg Clin N Am.* 1998;8(2):315-30. [PubMed: [9619307](https://pubmed.ncbi.nlm.nih.gov/9619307/)].
8. Obara H, Hoshina H, Iwai S, Ito H, Hisano K. Eventration of the diaphragm in infants and children. *Acta Paediatr Scand.* 1987;76(4):654-8. doi: [10.1111/j.1651-2227.1987.tb10536.x](https://doi.org/10.1111/j.1651-2227.1987.tb10536.x). [PubMed: [3630683](https://pubmed.ncbi.nlm.nih.gov/3630683/)].
9. Johnson J3, Thompson AR. Gastric volvulus and the upside-down stomach. *J Miss State Med Assoc.* 1994;35(1):1-4. [PubMed: [8164267](https://pubmed.ncbi.nlm.nih.gov/8164267/)].
10. Carter R, Brewer L3, Hinshaw DB. Acute gastric volvulus. A study of 25 cases. *Am J Surg.* 1980;140(1):99-106. doi: [10.1016/0002-9610\(80\)90424-9](https://doi.org/10.1016/0002-9610(80)90424-9). [PubMed: [7396092](https://pubmed.ncbi.nlm.nih.gov/7396092/)].
11. Shields TW. Diaphragmatic function, diaphragmatic paralysis, and eventration of the diaphragm. In: Shields TW, Locicero III J, Ponn RB, Rusch VW, editors. *General Thoracic Surgery*. Lippincott Williams Wilkins; 2005. p. 740-5.
12. Brara BS, Rossiter M, Moore KA. Eventration of diaphragm with volvulus of stomach and extralobar sequestration of the lung. *Proc R Soc Med.* 1977;70(10):725-6. [PubMed: [928383](https://pubmed.ncbi.nlm.nih.gov/928383/)].
13. Mitchell TE, Ridley PD, Forrester-Wood CP. Spontaneous rupture of a congenital diaphragmatic eventration. *Eur J Cardiothorac Surg.* 1994;8(5):281-2. doi: [10.1016/1010-7940\(94\)90161-9](https://doi.org/10.1016/1010-7940(94)90161-9). [PubMed: [8043293](https://pubmed.ncbi.nlm.nih.gov/8043293/)].
14. Watanabe S, Shimokawa S, Fukueda M, Kinjyo T, Taira A. Large eventration of diaphragm in an elderly patient treated with emergency plication. *Ann Thorac Surg.* 1998;65(6):1776-7. doi: [10.1016/S0003-4975\(98\)00210-0](https://doi.org/10.1016/S0003-4975(98)00210-0). [PubMed: [9647103](https://pubmed.ncbi.nlm.nih.gov/9647103/)].
15. *Wikipedia*. [2017 April 02]. Available from: <https://en.wikipedia.org/wiki/Cachexia>.