

Method for Management of Perianal Fistula with New Device: Progressive Curettage of the Tract and Sealing with Platelet-Rich Fibrin

Francisco Javier Perez Lara,^{1*} Arminda Ferrer Berges,¹ Jose Manuel Hernandez Gonzalez,¹ Elena Sanchis Cardenas,¹ Arturo del Rey Moreno,¹ and Horacio Oliva Munoz¹

¹Digestive Surgery Department, Antequera Hospital, Malaga, Spain

*Corresponding author: Francisco Javier Perez Lara, Digestive Surgery Department, Antequera Hospital, Malaga, Spain. Tel: +34-668830533, E-mail: javinewyork@hotmail.com

Received 2016 February 27; Revised 2016 August 11; Accepted 2016 August 17.

Abstract

Surgical treatment of high perianal fistulas, which affect a significant proportion of the sphincter apparatus, is difficult and associated with considerable risk of impaired anal continence. The diversity of approaches proposed for the treatment of complex perianal fistulas reflects the fact that no method has yet been shown to be fully satisfactory. We believe the successful treatment of this condition is directly proportional to the amount of fibrous tissue that can be removed. We used a kit of small curettes, of different thicknesses and sizes, incorporating spicules that enable the physician to remove fibrous tissue from the fistula tract. The small size and varying thicknesses of the curettes enable them to mold to the curves of the fistula tract and to remove tissue by de-roofing from the shallowest to the deepest layers, thus excising the entire fibrous tract. The tract is then sealed using autologous fibrin, applied through a catheter, with the help of a monitor indicating the amount of product remaining at all times. Finally, the internal orifice is closed by simple suturing.

Keywords: Anal Fistula, Sealant, Curettage, Platelet Rich Fibrin

1. Background

Perianal fistulas have an incidence of 1.1 to 2.2 per 10000 individuals per year (1). Many different approaches have been postulated to treat perianal fistulas, yet none is ideal, and so determining the optimum method remains a challenge for surgeons today.

Functional studies of patients before and after fistulotomy have shown that any section of the anal sphincter has peak and trough contraction values and is associated with changes in continence in 50% of patients (2). Subsequent rates of incontinence vary widely (reported levels range from 0% to 82% (3, 4)), while success rates range from 79% to 100% (3-9). The importance attached by patients to the possibility of having incontinence after treatment for a perianal fistula is reflected in an interesting article published in 2010 by Ellis (10), who concluded that most patients opt for sphincter-preserving techniques even though they are known to produce poorer results. This finding means that patients place a higher priority on reducing the risk of incontinence than on achieving better rates of healing.

We report on a conservative technique that combines intensive curettage of the fistula tract and sealing with

Platelet-Rich Fibrin (PRF).

The purpose of this technique is to seal fistula tracts that are complex, due to their location or to a prior condition affecting the sphincter.

2. Surgical Technique

We have produced a kit of three small curettes, which due to their suitable dimensions, when tensioned by two sutures, can be passed through the entire fistula tract (Figure 1). These curettes are 9-11 mm long (Figure 2), to follow the curvatures of the fistulous tract, and present a number of spiculated areas, so that their movement scrapes away the fibrous tissue from within the fistula. In addition, they are of various diameters, in order to scrape from the shallowest surface to the deepest part of the fibrous wall of the tract (the larger the diameter, the deeper the scraping action). The instrument (2 mm) with the smallest diameter has irregular abrasive zones on its surface; the intermediate one (3 mm) has spicules extending 0.6 mm, and the largest one (5 mm) has spicules of 1.2 mm.

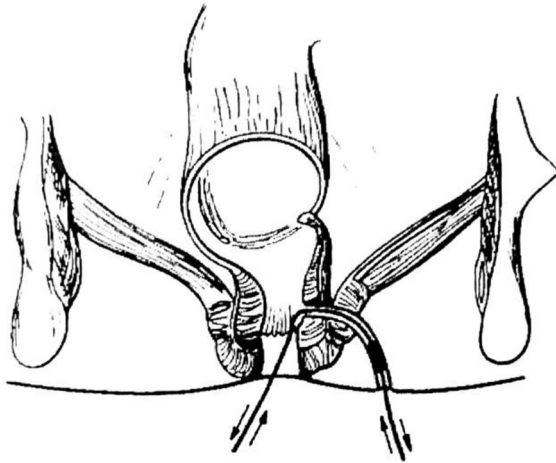


Figure 1. Curettage of the Fistula Tract Using Traction Applied to the Curette by the Two Sutures

On the day scheduled for surgery, patients are admitted to the hospital at least two hours prior to the removal of 120 mL of blood, to which citrate is added. This is then processed for 23 minutes to obtain the autologous fibrin sealant (Vivostat® PRF solution, Vivostat AS, Denmark). Finally, the fibrin is loaded on the applicator, which is fitted with a fine probe to allow the fibrin to be applied to the entire tract.

The first step in the surgical technique is to channel the fistula tract with a guide-wire, to which a 2-0 prolene suture is attached. The guide wire is then used to draw the suture through the tract. The suture is then passed through one of the eyelets in the smallest curette, another prolene suture is passed through the eyelet at the other end and thus the curette can be moved within the tract, backwards and forwards repeatedly until no further resistance is encountered (Figure 3). At this stage, the innermost part of the fibrous tract has been curetted. In performing these suture movements, it is very important to insert a finger near the inner orifice in order to guide the curette-guide wire assembly through the tract, to keep it as longitudinal as possible, and thus avoid pressure on the sphincters below the tract, which might otherwise be partially sectioned. This manoeuvre is then repeated with the intermediate-diameter curette, and finally with the largest one, in order to gradually remove all the fibrous layers from the fistula tract, and ultimately create a tunnel of 5 mm diameter. Then, resection of the fibrous zone of the inner and outer orifices can be performed, followed by washing of the tract with hydrogen peroxide (because active bleeding impedes

the action of growth factors). The tract is then sealed using autologous fibrin, applied through a catheter, with the help of a monitor indicating the amount of product remaining at all times. Finally, the internal orifice is closed by simple suturing.

With this technique, all patients receive preoperative antibiotic prophylaxis (intravenous amoxicillin-clavulanate: 2g). The surplus fibrin is refrigerated (-18°C) for use in a second application, as outpatient treatment, if necessary.

3. Discussion

High fistulas require a complex treatment, normally with partial division of the sphincter. This technique is associated with an increased risk of incontinence and achieves rates of success that are variable, yet significantly lower than with low fistulas.

In this respect, there are two main groups of surgical techniques: those involving laying open and those which preserve the sphincter. The first treatment achieves higher rates of healing, but it also leads to higher rates of fecal incontinence. In the second case, regardless of the technique used, it is very important to perform curettage and resection of the greatest possible amount of fibrous tissue from the tract. However, the surgical instruments currently available for this task do not include any curette that is ideally suited, as the instruments used are not able to closely follow the fistula tracts (which are usually curvilinear). Nevertheless, the results obtained by high-fistula treatment may be directly proportional to the amount of fibrous tissue removed from the tract. For this reason we have made our own curettes (11), enabling us to remove all the fibrous layers from the fistula tract, and ultimately to create a 5-mm tunnel.

A colorectal surgeon should become familiar with various new techniques for treating an anal fistula. In particular, the advancement flap is still the gold standard of treatment for complex anal fistulas, but two complications are frequently associated with this intervention: the recurrence of the fistula (10-60%) and anal incontinence (10-35%) (12, 13).

Fibrin glue was the first biological material used for fistula repair (14), and this has been followed by other non-invasive techniques such as plugging (15), stem cells (16) and Nitinol clips (17). However, only mixed results have been achieved.

Fibrin glue has been used for surgical sealants since the 1940s, and since then has been applied for the treatment of anal fistulas (18). Success rates vary widely; this variation may have arisen because studies were too small or involved multiple centers. Nevertheless, there is general agreement

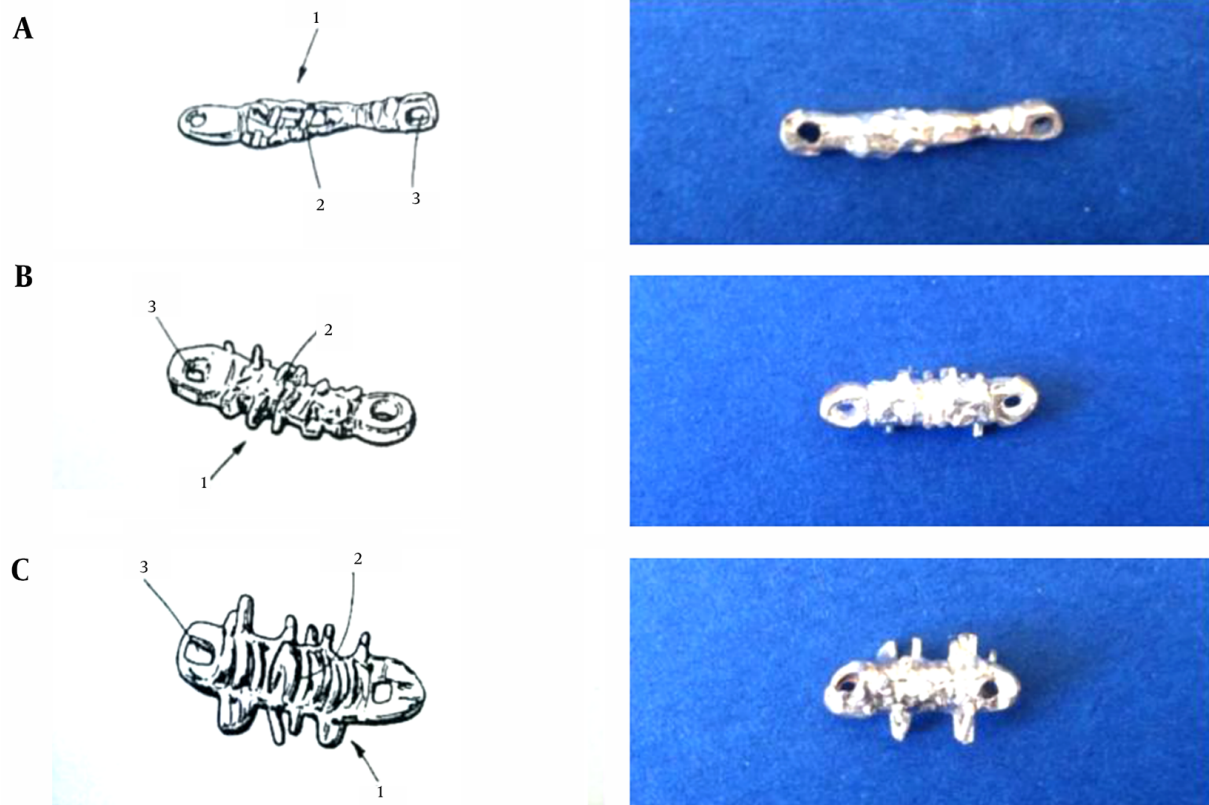


Figure 2. Set of Cylindrical Curettes, in Three Different Sizes (1a-Small, 1b-Medium, 1c-Large), 2-Spiculated Area, 3-Eyelet

that the main benefit of this approach is that it does not provoke incontinence.

In 1974, the regenerative potentiality of platelets was reported, and Ross et al. (19) described a growth factor derived from platelets. The growth factors present in platelets are important to guide the regenerating cells to the area of healing. Platelet-Rich Fibrin (PRF) retains the growth factors enmeshed in the fibrin network, and enables their sustained release over a period of time, which can accelerate healing. In the recent years, better understanding of the physiologic properties of platelets in the healing process has led to their increased use in therapeutic applications, such as the treatment of vascular ulcers (20), bone regeneration (21), periodontal regeneration (22) and wound closure procedures (23). In view of these applications, we began to treat complex perianal fistulas by sealing them with PRF. Our multi-center study reported a success rate of 66% with this approach (24).

Our study of the results obtained in the anatomic-pathologic tract after sealing with PRF (Figure 4) revealed scar tissue with a striking degree of reactive vascular proliferation, in comparison with the usual scar tissue, which

we assume resulted from the accelerated tissue growth.

Experimental models in pigs have suggested that curettage prior to the application of fibrin glue may improve the obtained results (25). Methods that have been used to debride the fistula tract, include the injection of hydrogen peroxide, the application of saline solution and curettage with a brush or curette, but none of these removes all of the granulation tissue from the tract.

With the experience gained from our multi-center study, we believe that the results could be improved if a complete curettage could be performed for the fistula tract. The standard surgical technique would then be reinforced by the curettage of the fistula tract to remove granulation tissue from the entire tract and thus enhance the presence of healthy tissue and blood flow.

By using these curettes in conjunction with the standard technique, we obtained encouraging preliminary results with 15 patients, and the success rate rose from 66% to 87%.

This technique is easily reproducible and safe, with minimal side effects and with no negative impact on continence. We believe it could play an important role in the

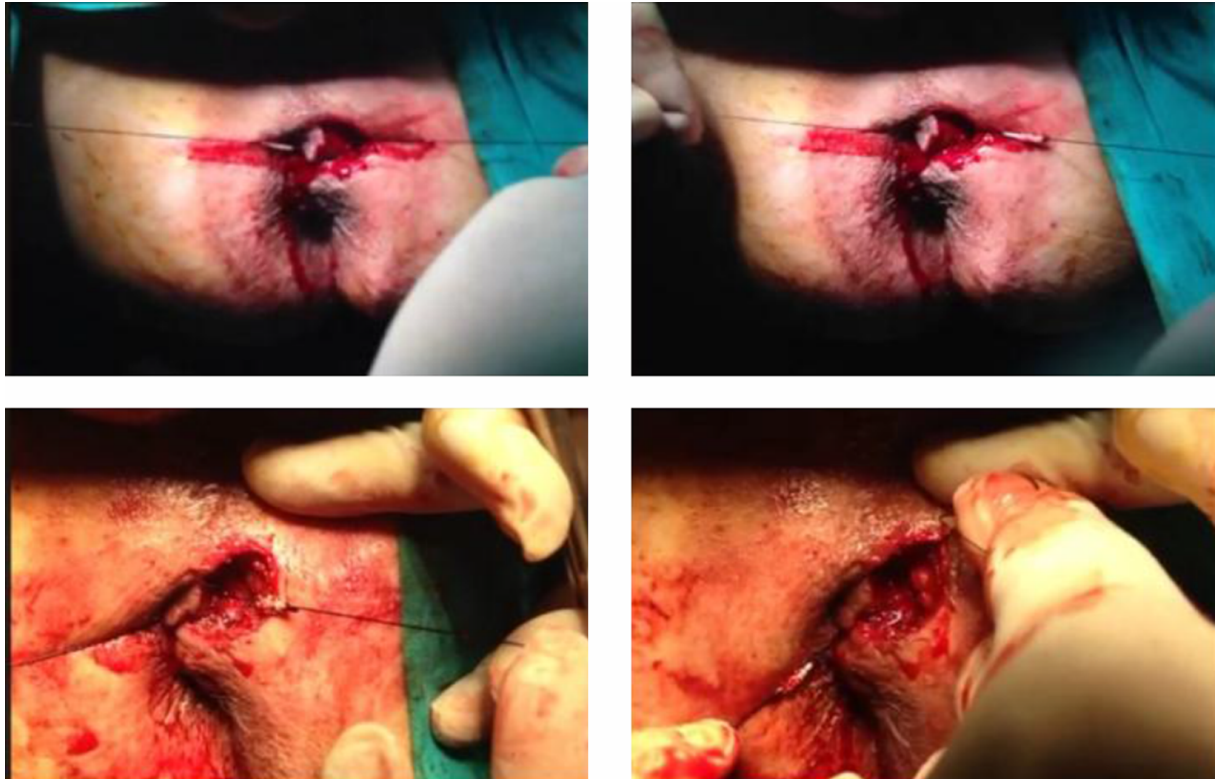


Figure 3. Illustration of Curettage With the Cylindrical Curettes During a Surgical Intervention (Top: Smallest Curette. Bottom: Largest Curette)

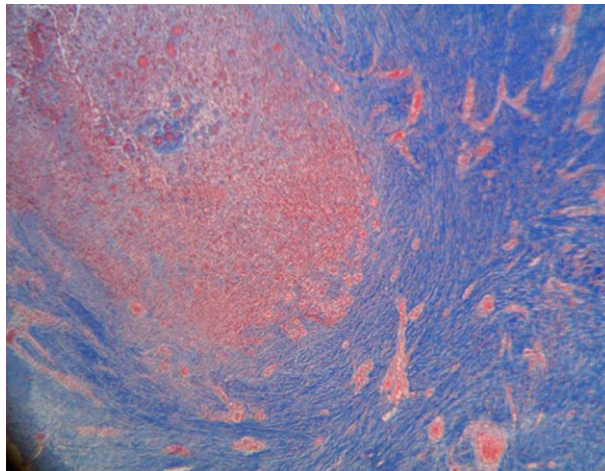


Figure 4. Pathologic Anatomy of the Resected Tract After the Failed Application of Platelet-Rich Fibrin (Connective Tissue - Blue, Granulation Tissue with Striking Vascular Proliferation - Red) (Masson Trichrome Technique)

treatment of fistulas that have moderate or extensive impact on the sphincter, and for patients with low fistulas to-

gether with sphincter dysfunction.

Footnote

Authors' Contribution: Francisco Javier Perez Lara, made a substantial contribution to the concept and design, drafted the article and revised it critically for important intellectual content, and approved the version to be published; Arminda Ferrer Berges, approved the version to be published; Jose Manuel Hernandez Gonzalez, approved the version to be published; Elena Sanchis Cardenas, approved the version to be published; Arturo del Rey Moreno, approved the version to be published; Horacio Oliva Munoz, approved the version to be published.

References

1. Zanotti C, Martinez-Puente C, Pascual I, Pascual M, Herreros D, Garcia-Olmo D. An assessment of the incidence of fistula-in-ano in four countries of the European Union. *Int J Colorectal Dis.* 2007;22(12):1459-62. doi:10.1007/s00384-007-0334-7. [PubMed: 17554546].
2. Lunniss PJ, Kamm MA, Phillips RK. Factors affecting continence after surgery for anal fistula. *Br J Surg.* 1994;81(9):1382-5. [PubMed: 7953425].

3. Hammond TM, Knowles CH, Porrett T, Lunniss PJ. The Snug Seton: short and medium term results of slow fistulotomy for idiopathic anal fistulae. *Colorectal Dis.* 2006;**8**(4):328-37. doi:10.1111/j.1463-1318.2005.00926.x. [PubMed: 16630239].
4. Dziki A, Bartos M. Seton treatment of anal fistula: experience with a new modification. *Eur J Surg.* 1998;**164**(7):543-8. doi: 10.1080/110241598750005930. [PubMed: 9696978].
5. Ho YH, Tan M, Chui CH, Leong A, Eu KW, Seow-Choen F. Randomized controlled trial of primary fistulotomy with drainage alone for perianal abscesses. *Dis Colon Rectum.* 1997;**40**(12):1435-8. [PubMed: 9407981].
6. Byrne CM, Solomon MJ. The Use of Setons in Fistula-in-Ano. *Semin Colon Rectal Surg.* 2009;**20**(1):10-7. doi: 10.1053/j.scrs.2008.10.003.
7. van Koperen PJ, Wind J, Bemelman WA, Bakx R, Reitsma JB, Slors JF. Long-term functional outcome and risk factors for recurrence after surgical treatment for low and high perianal fistulas of cryptoglandular origin. *Dis Colon Rectum.* 2008;**51**(10):1475-81. doi: 10.1007/s10350-008-9354-9. [PubMed: 18626715].
8. Cox SW, Senagore AJ, Luchtefeld MA, Mazier WP. Outcome after incision and drainage with fistulotomy for ischioanal abscess. *Am Surg.* 1997;**63**(8):686-9. [PubMed: 9247434].
9. Vaizey CJ, Carapeti E, Cahill JA, Kamm MA. Prospective comparison of faecal incontinence grading systems. *Gut.* 1999;**44**(1):77-80. [PubMed: 9862829].
10. Ellis CN. Sphincter-preserving fistula management: what patients want. *Dis Colon Rectum.* 2010;**53**(12):1652-5. doi: 10.1007/DCR.0b013e3181f2e9cd. [PubMed: 21178860].
11. Perez Lara FJ, Hernandez Carmona JM, Del Rey Moreno A, Oliva Munoz H. Cylindrical currettes for the treatment of complex perianal fistulas. *Dis Colon Rectum.* 2014;**57**(9):1140. doi: 10.1097/DCR.0000000000000185. [PubMed: 25101611].
12. Sonoda T, Hull T, Piedmonte MR, Fazio VW. Outcomes of primary repair of anorectal and rectovaginal fistulas using the endorectal advancement flap. *Dis Colon Rectum.* 2002;**45**(12):1622-8. doi: 10.1097/01.DCR.0000037653.68665.E8. [PubMed: 12473885].
13. van der Hagen SJ, Baeten CG, Soeters PB, Beets-Tan RG, Russel MG, van Gemert WG. Staged mucosal advancement flap for the treatment of complex anal fistulas: pretreatment with noncutting Setons and in case of recurrent multiple abscesses a diverting stoma. *Colorectal Dis.* 2005;**7**(5):513-8. doi: 10.1111/j.1463-1318.2005.00850.x. [PubMed: 16108891].
14. Hjortrup A, Moesgaard F, Kjaergard J. Fibrin adhesive in the treatment of perineal fistulas. *Dis Colon Rectum.* 1991;**34**(9):752-4. [PubMed: 1914738].
15. Champagne BJ, O'Connor LM, Ferguson M, Orangio GR, Schertzer ME, Armstrong DN. Efficacy of anal fistula plug in closure of cryptoglandular fistulas: long-term follow-up. *Dis Colon Rectum.* 2006;**49**(12):1817-21. doi: 10.1007/s10350-006-0755-3. [PubMed: 17082891].
16. Herreros MD, Garcia-Arranz M, Guadalajara H, De-La-Quintana P, Garcia-Olmo D, Fatt Collaborative Group. Autologous expanded adipose-derived stem cells for the treatment of complex cryptoglandular perianal fistulas: a phase III randomized clinical trial (FATT 1: fistula Advanced Therapy Trial 1) and long-term evaluation. *Dis Colon Rectum.* 2012;**55**(7):762-72. doi: 10.1097/DCR.0b013e318255364a. [PubMed: 22706128].
17. Prosst RL, Herold A, Joos AK, Bussen D, Wehrmann M, Gottwald T, et al. The anal fistula claw: the OTSC clip for anal fistula closure. *Colorectal Dis.* 2012;**14**(9):1112-7. doi: 10.1111/j.1463-1318.2011.02902.x. [PubMed: 22122680].
18. Maralcan G, Baskonus I, Aybasti N, Gokalp A. The use of fibrin glue in the treatment of fistula-in-ano: a prospective study. *Surg Today.* 2006;**36**(2):166-70. doi: 10.1007/s00595-005-3121-5. [PubMed: 16440165].
19. Ross R, Glomset J, Kariya B, Harker L. A platelet-dependent serum factor that stimulates the proliferation of arterial smooth muscle cells in vitro. *Proc Natl Acad Sci U S A.* 1974;**71**(4):1207-10. [PubMed: 4208546].
20. Eppley BL, Woodell JE, Higgins J. Platelet quantification and growth factor analysis from platelet-rich plasma: implications for wound healing. *Plast Reconstr Surg.* 2004;**114**(6):1502-8. [PubMed: 15509939].
21. Li Q, Pan S, Dangaria SJ. Platelet-rich fibrin promotes periodontal regeneration and enhances alveolar bone augmentation. *Biomed Res Int.* 2013;**2013**:1-13.
22. Singh A, Kohli M, Gupta N. Platelet rich fibrin: a novel approach for osseous regeneration. *J Maxillofac Oral Surg.* 2012;**11**(4):430-4. doi: 10.1007/s12663-012-0351-0. [PubMed: 24293936].
23. O'Connell SM, Impeduglia T, Hessler K, Wang XJ, Carroll RJ, Dardik H. Autologous platelet-rich fibrin matrix as cell therapy in the healing of chronic lower-extremity ulcers. *Wound Repair Regen.* 2008;**16**(6):749-56. doi: 10.1111/j.1524-475X.2008.00426.x. [PubMed: 19128245].
24. Lara FJ, Serrano AM, Moreno JU, Carmona JH, Marquez MF, Perez LR, et al. Platelet-rich fibrin sealant as a treatment for complex perianal fistulas: a multicentre study. *J Gastrointest Surg.* 2015;**19**(2):360-8. doi: 10.1007/s11605-014-2698-7. [PubMed: 25421358].
25. Buchanan GN, Sibbons P, Osborn M, Bartram CI, Ansari T, Halligan S, et al. Pilot study: fibrin sealant in anal fistula model. *Dis Colon Rectum.* 2005;**48**(3):532-9. doi: 10.1007/s10350-004-0815-5. [PubMed: 15711858].