

## Assessment of the Relationship between Human Papilloma Virus Infections and Cutaneous Squamous Cell Carcinoma

Mohammad Javad Yazdanpanah\*, Noorieh Sharifi Sistani\*\*, Elnaz Hosseini\*, Elham Vosoughi\*, Seyed Saeid Hosseini\*\*\*, Mohammad Khajedaluee\*\*\*\*, Saeid Amel Jamehdar\*\*\*\*\*

\*Cutaneous Leishmaniasis Research Center, Mashhad University of Medical Sciences, Mashhad, Iran

\*\*Department of Pathology, Ghaem Hospital, School of Medicine, Mashhad University of Medical Sciences, Mashhad, Iran

\*\*\*Department of Otorhinolaryngology, Ghaem Hospital, School of Medicine, Mashhad University of Medical Sciences, Mashhad, Iran

\*\*\*\*Department of Biostatistics and Epidemiology, School of Health, Mashhad University of Medical Sciences, Mashhad, Iran

\*\*\*\*\*Cancer Molecular Pathology Research Center, Mashhad University of Medical Sciences, Mashhad, Iran

### Abstract

**Background:** The relationship between HPV infection and skin squamous cell carcinoma (SCC) development in immunocompetent individuals is unclear. Therefore, the purpose of this study was to assess the association between HPV infection and skin SCC.

**Methods:** HPV DNA prevalence was evaluated in the paraffin embedded specimens of 70 immunocompetent patients, of which 35 patients had skin SCC and 35 had normal skin. PCR technique and GP6/5 primers were utilized for HPV DNA detection.

**Result:** Based on this study, 14.3% of the cases (5 of 35, 2 with low risk and 3 with high risk viruses) and 2.9% of the controls (1 of 35 with low risk virus) had papilloma viruses. However, there was no significant statistical relationship between the HPV DNA presence and the SCC development in skin.

**Conclusion:** The direct effect of HPV on skin cancerogenesis remains questionable.

**Keyword:** Human papilloma virus, Non-melanoma skin cancers, Squamous cell carcinoma

#### \*Corresponding Author:

Saeid Amel Jamehdar, PhD  
Cancer Molecular Pathology  
Research Center, Mashhad  
University of Medical Sciences,  
Mashhad, Iran  
Tel: +98-9155220380  
Fax: +98-5138022206  
Email: ameljs@mums.ac.ir

### Introduction

Non-melanoma skin cancers (NMSCs) are the most common malignancy among the white population.<sup>1-3</sup> It has two histologic

types, basal cell carcinoma (BCC) and squamous cell carcinoma (SCC). Compared to BCC, SCC has more malignant behavior and more metastasis.<sup>1,4</sup>

**Table 1.** Case and control groups' information

	Case group	Control group	P value
<b>Sex</b>			
Male	23(65.7%)	23(65.7%)	P=1
Female	12(34.3%)	12(34.3%)	
<b>Age</b>			
Mean $\pm$ SD	62.9 $\pm$ 16.5	63 $\pm$ 17.13	P=0.07
<b>Biopsy site</b>			
Head and neck	31(88.5%)	1(88.5%)	
Upper limb	3(8.5%)	3(8.5%)	
Lower limb	1(3%)	1(3%)	
<b>Pathologic grading</b>			
Grade 1	13(37.2%)		
Grade 2	11(31.4%)		
Grade 3	11(31.4%)		

Squamous cell carcinoma is the second most common malignancy of skin, comprising 20% of all skin malignancies.<sup>5</sup> The prevalence of this disease has significantly increased over the recent decades (10-30% per year).<sup>6</sup> Several factors are involved in the development of skin squamous cell carcinoma such as exposure to UV radiation,<sup>5</sup> chemical carcinogens,<sup>7</sup> X ray,<sup>8</sup> skin burning, and human papilloma viruses (HPVs).<sup>9</sup> This malignancy originates from suprabasal keratinocytes of the epidermis and has a broad spectrum of manifestations, ranging from a curable, superficial cancer to a malignancy with distant metastasis and a high rate of mortality, particularly if diagnosis and treatment are delayed.<sup>6</sup>

Human papilloma viruses are a group of small, non-enveloped viruses with double strand DNA,<sup>10</sup> infecting mucosal and skin epithelial cells.<sup>11,12</sup> More than 200 different genotypes of viruses have been reported to lead to different clinical manifestations of the disease.<sup>6</sup> HPV is known as a carcinogen factor in the pathogenesis of cervical and anogenital cancers; however, its role in the development of skin cancer was demonstrated first in patients with Epidermodysplasia Verruciformis, a rare hereditary disease.<sup>2,3,13</sup> Although HPVs is frequently detected in healthy skins, the relationship between HPVs infection and skin SCC development in immunocompetent individuals is yet to be elucidated.

According to several studies, HPVs DNA has been detected in more than 80% of NMSC lesions

in immunocompromised patients compared with less than 40% in immunocompetents. In the study by Quinn et al,<sup>14</sup> the HPVs DNA was observed in the normal skin biopsies of 87% of the patients with kidney transplantation, while it was found in 35% of the healthy individuals with intact immune system.<sup>14</sup>

In the present study, the relationship between HPV infection and skin SCC development was assessed through detecting high-risk and low-risk HPVs DNA in skin biopsy specimens of a group of patients with SCC and a group of healthy individuals.

## Methods

### Patient selection

This is a cross-sectional study performed on 35 histological biopsy specimens from patients with SCC and on 35 specimens as controls, selected among patients with unrelated dermatologic conditions (dermatitis). All cancers and control samples were confirmed histologically by an expert pathologist. The patient demographic data was collected based on the checklist.

The paraffin embedded skin SCC samples were obtained from the archive of the pathology department in Ghaem hospital during 2006-2010. All controls had skin biopsy specimens with normal pathology reports. The two groups were completely matched regarding age, sex and, biopsy sites. Subjects were excluded if they had immunosuppressive conditions, HPV related lesions (such as warts and condilomas), any skin lesions with

**Table 2.** HPV DNA positive samples in the case group

HPV serotype	Sex	Age	Biopsy site	Grade	HPV type
16 & 18	Female	40	Head & neck	3	high risk
11	Male	62	Head & neck	1	low risk
18	Female	64	Head & neck	1	high risk
16	Male	41	Head & neck	1	high risk
11	Male	60	Head & neck	3	low risk

UV light treatment (psoriasis and vitiligo), and/or past history of mucosal SCC (cervix, head, and neck).

### DNA extraction

In the first step, appropriate tissue samples were prepared by a pathologist in 1.5 mL microtubes. DNA extraction kit (AmpliSense) was used for genomic DNA isolation according to the manufacturer's instructions. In summary, paraffin was resolved with 1 mL Oktane. Lysis buffer and Proteinase K were added to lyse the virus cell wall. After washing the DNA to remove proteins, salts, and other detergents, it was dissolved in 50 mL nuclease-free water to become ready for PCR.

### PCR

We used GP5/GP6 primers for detecting HPV DNA. Polymerase chain reaction was done via 5 PRIME Master Mix. For the integrity of the PCR, we used human B-globin gene as internal control. Following PCR, electrophoresis was done by 1.5% agarose gel. In the next step, for HPV typing, an HPV gene fragment was amplified by use of Detection and Differentiation of Human Papilloma Virus kits, as instructed by the manufacturer (GenID, GmbH, Germany). The high risk HPV (HPV16, HPV18, HPV45, HPV30's, HPV50's) and low risk HPV (HPV6, HPV11) can also be detected by this kit. Briefly, two PCR reactions were performed on isolated DNA. In these reactions, a fragment of the HPV-genome was amplified with each specific biotin-labeled primer. The amplified gene fragments were subsequently characterized by a hybridization reaction with sequence-specific oligonucleotide probes (SSOP) which represent particular HPV-genotypes and are immobilized on nitrocellulose membrane.

### Statistical analysis

Data were analyzed by SPSS 11.5. Descriptive statistics was used to describe the data. To compare the variables in two groups, chi-squared test and student t-test were used for qualitative and quantitative variables, respectively. Prior to each test, the normal distribution of data was checked. If data were not normally distributed, equal non-parametric tests were used instead.  $P < 0.05$  was considered significant for statistical tests.

### Results

After matching, 35 skin tissue samples of patients with SCC and 35 samples of normal skins were selected according to inclusion and exclusion criteria. The mean age of the SCC group was  $62.5 \pm 16.5$  years (max=86 y, min=36 y) and that of the controls was  $63 \pm 17.13$  years (max=90, min=34). Moreover, 65.7% (23) of the cases in both groups were male and 34.3% (12) were female. There was no significant statistical difference in age and sex between the two groups ( $P$  value= 0.07 and 1). Table 1 shows the biopsy locations and pathologic grading of the SCC specimens.

Following viral DNA extraction, the PCR was done, via the explained specific and universal primers, on the extracted DNA and the negative and positive controls. Figure 1 shows the 150 base pairs developed by the viral genome amplification.

After HPV DNA was detected in the tissue samples, virus DNA genotyping was done through the use of the commercial kits. As seen in figure 2, high and low risk HPVs were detected.

As listed in table 2, HPV DNA was positive in five (14.3%) of 35 cases in the case group. Two of the patients had low-risk viruses and three

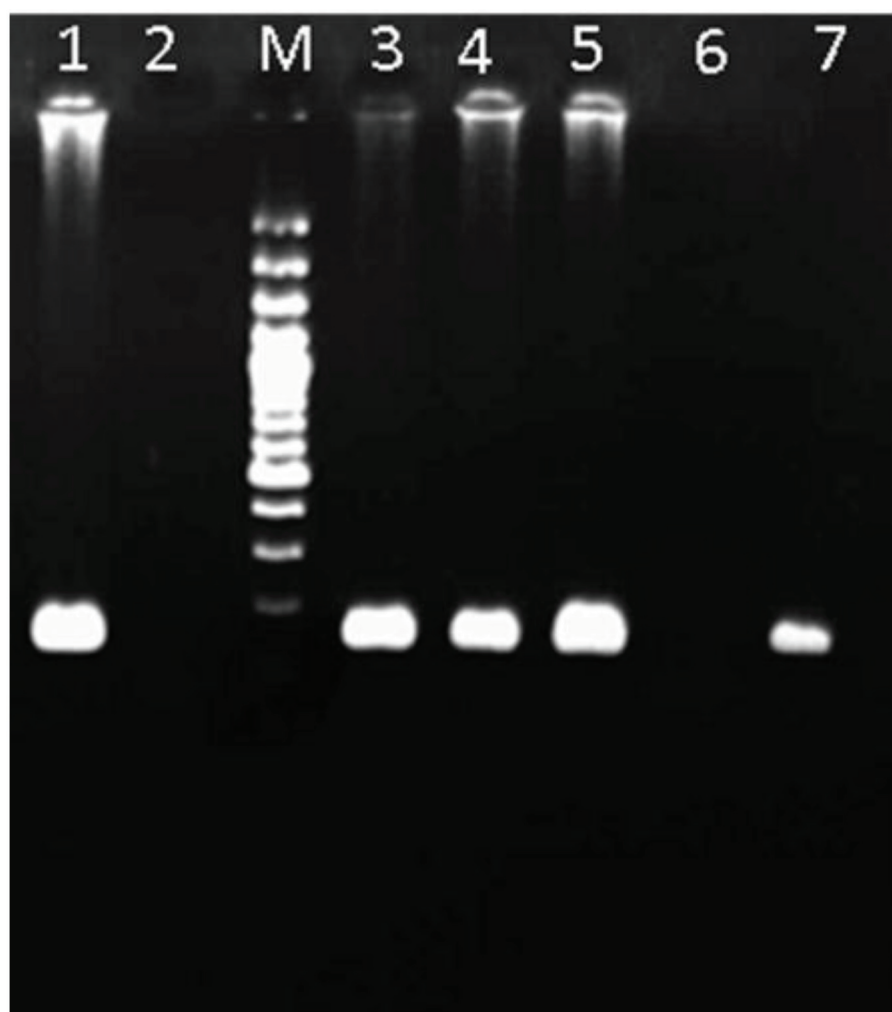
had high-risk viruses. One of these three cases had two high-risk viruses. All of the positive biopsy specimens were obtained from the head and neck of patients with a mean age of 53.4 years. Three of these specimens were male and two were female. There was only one HPV DNA positive sample (2.9%) in the control group obtained from the head of a 53-year-old woman.

Based on Fisher's exact test, there was no significant difference between the case group and the control group ( $P$  value= 0.09). No difference regarding sex, age, biopsy site, and pathologic grading was observed between the positive and negative HPV DNA specimens in the case group ( $P$  value= 0.7, 0.2, 0.6, and 0.2, respectively).

## Discussion

This study was conducted to assess the role of HPVs in skin SCC development in immunocompetent individuals. The evaluations of 35 skin SCC tissue samples were compared with 35 healthy skin samples, where no significant relationship was found between skin infection with HPV and skin cancer development.

A broad spectrum of human papilloma viruses have been found in healthy skins as well as in skins with non-melanoma skin cancers.<sup>3</sup> Although these viruses play a role in the pathogenesis of NMSCs in epidermodysplasia verruciformis patients, no specific type of HPV has been associated with such lesions in normal populations. Moreover, the role of HPV DNA in the pathogenesis of skin cancers is yet to be



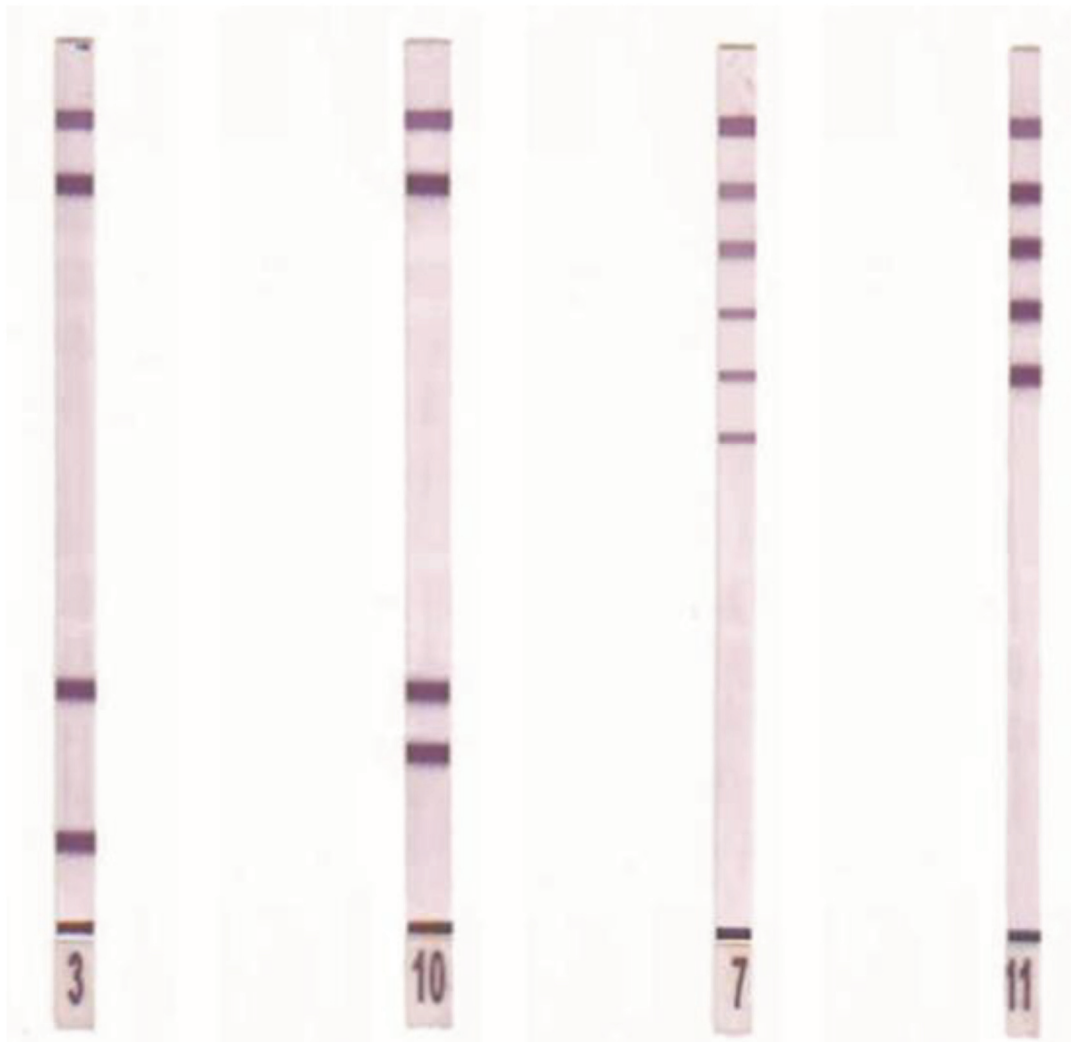
**Figure 1.** HPV PCR performed on paraffin embedded tissue samples, Lane 1: positive control, 150bp pieces due to viral genome amplification, Lane 2: negative control, Lane M: DNA 100bp marker, Lane 3-7: tissue samples.

clarified.<sup>8</sup>

Several studies have been done to discover the relationship between HPV infections and skin cancers; however, different results have been reported and the role of HPV DNA in skin cancers pathogenesis of immunocompetent individuals requires further elucidation. For instance, in the study done by Shahmahmudi et al.<sup>15</sup> in Iran (2007), high risk HPV was identified as a significant risk factor for non-melanoma skin cancers. They further obtained 288 paraffin embedded biopsies from benign and malignant skin lesions. Using Nested PCR with MY 09/11 and GP 6/5 primers, mucosal HPV were detected in 25.7% of malignant and 0.7% of benign lesions.<sup>15</sup> They evaluated the presence of mucosal HPV in the skin lesions, as was done in the present

study. However, they did not perform any sex, age, and biopsy location matching between the groups with benign and malignant lesions; however, recent studies have shown that long sun exposure of the biopsy site is the most potent risk factor for skin infection with HPV.<sup>3</sup>

Certain studies have shown significant results as regards identifying the role of epidermodysplasia verruciformis-related HPV types in the development of skin cancers. In a case-control study by Masini et al. in Italy (2003),<sup>16</sup> serologic (virus like particle enzyme-linked immunosorbent assay) testing was done on serum samples obtained from 46 immunocompetent patients with skin SCC and 84 healthy individuals as control. This study showed that SCC development was associated with the positive serologic finding of



**Figure 2.** Band 3: low risk HPV (HPV-11), Band 10: low risk HPV (HPV-6), Band 7: high risk HPV (HPV-16/18), Band 11: high risk HPV (HPV-16).



HPV type 8, while HPV-15 seropositivity was negatively associated with the SCC development.<sup>16</sup>

In the present study, 14.3% of the case group (5 of 35) and 2.9% of the controls (1 of 35) had papilloma viruses, while there was no significant statistical relationship between HPV DNA presence and SCC development. This is in agreement with Meyer's study in Germany<sup>17</sup> and Asgari's in California.<sup>18</sup> In the former study (2001), HPV DNA was detected in different skin lesions and normal skins, using a PCR system designed to detect all HPV types. HPV was found in 69% of squamous cell carcinomas, 52% of basal cell carcinomas, and 16% of normal skin tissues. Although HPV prevalence found in their study was much higher than the present (69% versus 14.3%), there was no specific HPV type predominance in any of the skin lesions and no clear relationship between HPV presence and malignant skin lesions,<sup>17</sup> in line with the current research. In another case-control study done in 2007 by Asgari et al. in California,<sup>18</sup> papilloma viruses prevalence in normal skins was observed to be even more than that in malignant lesions (59% of the 95 normal skin cases versus 54% of the 85 malignant lesions), which is probably due to skin superficial contaminations. They used three different PCR protocols to detect all HPV serotypes. Overall, there was no difference concerning HPV prevalence between immunocompetent patients with skin SCC and normal individuals.<sup>18</sup>

These results indicate that the direct role of HPV in skin cancerogenesis remains questionable and there exist probably other risk factors such as solar radiation and genetic predisposition, which play essential roles in the pathogenesis of NMSCs. These risk factors may lead to inconsistent conclusions on HPV role, as reported in various studies.

### Acknowledgment

This study was supported by a grant from the Vice Chancellor for Research of Mashhad University of Medical Sciences (grant number 87253).

### Conflict of Interest

None declared.

### References

1. Fahradyan A, Howell AC, Wolfswinkel EM, Tsuha M, Sheth P, Wong AK. Updates on the management of non-melanoma skin cancer (NMSC). *Healthcare (Basel)*. 2017;5(4). pii: E82. doi: 10.3390/healthcare5040082.
2. Aldabagh B, Angeles JG, Cardones AR, Arron ST. Cutaneous squamous cell carcinoma and human papillomavirus: is there an association? *Dermatol Surg*. 2013;39(1 Pt 1):1-23. doi: 10.1111/j.1524-4725.2012.02558.x.
3. Nichols AJ, Allen AH, Shareef S, Badiavas EV, Kirsner RS, Ioannides T. Association of human papillomavirus vaccine with the development of keratinocyte carcinomas. *JAMA Dermatol*. 2017; 153(6):571-4. doi:10.1001/jamadermatol.2016.5703.
4. Grace K, Kim, James Q, Del Rosso, Susun Bellew. Skin cancer in Asians: Part 1: Nonmelanoma skin cancer. *J Clin Aesthet Dermatol*. 2009; 2(8): 39-42.
5. Kanitakis J, Petruzzo P, Gazarian A, Testelin S, Devauchelle B, Badet L, et al. Premalignant and malignant skin lesions in two recipients of vascularized composite tissue allografts (Face, Hands). *Case Rep Transplant*. 2015; 2015: 356459. doi: 10.1155/2015/356459.
6. Russo GG. Actinic keratoses, basal cell carcinoma, and squamous cell carcinoma: uncommon treatments. *Clin Dermatol*. 2005; 23(6): 581-6. doi: 10.1016/j.clindermatol.2005.01.002.
7. Gheit T. Mucosal and cutaneous human papillomavirus infections and cancer biology. *Front Oncol*. 2019; 9: 355. doi: 10.3389/fonc.2019.00355.
8. Li J, Pan Y, Deng Q, Cai H, Ke Y. Identification and characterization of eleven novel human gamma-papillomavirus isolates from healthy skin, found at low frequency in a normal population. *PLoS One*. 2013; 8(10): e77116. doi:10.1371/journal.pone.0077116.
9. Zakrzewska K, Regalbuto E, Pierucci F, Arvia R, Mazzoli S, Gori A, et al. Pattern of HPV infection in basal cell carcinoma and in perilesional skin biopsies from immunocompetent patients. *Viol J*. 2012; 9: 309. doi: 10.1186/1743-422X-9-309.
10. Tommasino M. HPV and skin carcinogenesis. *Papillomavirus Res*. 2019; 7: 129-31. doi: 10.1016/j.pvr.2019.04.003.
11. Boscolo-rizzo P, Del mistro A, Bussu F, Lupato V, Baboci L, Almadori G, et al. New insights into human papillomavirus-associated head and neck squamous cell carcinoma. *Acta Otorhinolaryngol Ital*. 2013; 33(2): 77-87.

12. Wittekindt C, Wagner S, Sharma SJ, Würdemann N, Knuth J, Reder H, et al. HPV- A different view on head and neck cancer. *Laryngorhinootologie*. 2018; 97(Suppl 1): S48-S113. doi: 10.1055/s-0043-121596.
13. Akgul B, Cooke JC, Storey A. HPV-associated skin disease. *J Pathol*. 2006; 208(2):165-75. doi: 10.1002/path.1893.
14. Paolino G, Donati M, Didona D, Mercuri SF, Cantisani C. Histology of non-melanoma skin cancers: An update. *Biomedicines*. 2017; 5(4): 71. doi: 10.3390/biomedicines5040071.
15. Shahmahmoudi S, Mahmoodi M, Azad TM, Rad KS, Tabatabaie H, Savijlou M, et al. Prevalence of mucosal types of human papillomavirus in skin lesions in north part of Iran. *Cancer Lett*. 2007; 247(1):72-6. doi: 10.1016/j.canlet.2006.03.023
16. Masini C, Fuchs PG, Gabrielli F, Stark S, Sera F, Ploner M, et al. Evidence for the association of human papillomavirus infection and cutaneous squamous cell carcinoma in immunocompetent individuals. *Arch Dermatol*. 2003; 139(7):890-4. doi: 10.1001/archderm.139.7.890.
17. Egawa N, Egawa K, Griffin H, Doorbar J. Human papillomaviruses; epithelial tropisms, and the development of neoplasia. *Viruses*. 2015; 7(7): 3863-90. doi: 10.3390/v7072802.
18. Asgari MM, Kiviat NB, Critchlow CW, Stern JE, Argenyi ZB, Raugi GJ, et al. Detection of human papillomavirus DNA in cutaneous squamous cell carcinoma among immunocompetent individuals. *J Invest Dermatol*. 2008; 128(6):1409-17. doi: 10.1038/sj.jid.5701227.