

Sclerotherapy Using Aluminum Potassium Sulfate and Tannic Acid (ALTA) for Haemorrhoids in Patients With Liver Cirrhosis

Hidenori Miyamoto,^{1,2,*} Tateo Nakagawa,³ Hideyuki Miyamoto,¹ and Atsushi Takata²

¹Department of Surgery and Proctologic Surgery, Miyamoto Hospital, Anan, Japan

²Department of Digestive and Pediatric Surgery, Institute of Health Biosciences, University of Tokushima Graduate School, Tokushima, Japan

³Department of Surgery, Mizunomiyako Memorial Hospital, Tokushima, Japan

*Corresponding author: Hidenori Miyamoto, Department of Digestive and Pediatric Surgery, Institute of Health Biosciences, University of Tokushima Graduate School, Tokushima, Japan. Tel: +81-886337137, Fax: +81-886319698, E-mail: hnna@diamond.nmt.ne.jp

Received 2015 September 8; Accepted 2015 October 27.

Abstract

Background: Symptomatic haemorrhoids in liver cirrhosis are difficult to handle due to rich collateral circulation and possible concomitant coagulo-therapy.

Objectives: The purpose of this study was to investigate the efficacy and safety of ALTA sclerotherapy in treating symptomatic haemorrhoids in patients with liver cirrhosis and to demonstrate the differences of blood flow in hemorrhoidal tissue in patients with liver cirrhosis *in vivo*, using transanal ultrasonography.

Patients and Methods: Eleven patients with liver cirrhosis and haemorrhoidal disease were included in this study. The blood flow in the haemorrhoids was identified using three-dimensional power Doppler angiography (3D-PDA). All patients performed ALTA sclerotherapy.

Results: All patients' symptoms (prolapse and/or bleeding) improved. However, two cases re-prolapsed during five years. Although two patients experienced slight bleeding after treatment and three patients experienced retention of ascites, there were no serious complications. 3D-PDA showed higher or lower vascularization in haemorrhoidal tissue in patients with liver cirrhosis. The prevalence of anorectal varices and haemorrhoids in cirrhotic patients had no association to Child-Pugh's grading. Two patients with hyper-vascularity in haemorrhoidal tissue experienced slight bleeding after treatment.

Conclusions: ALTA sclerotherapy could bring an acceptable outcome for haemorrhoidal patients concurrent with liver cirrhosis. Using transanal ultrasonography, we could visualize the difference of blood flow in the haemorrhoid plexus and anorectal varices *in vivo*. This might be useful for treatment of haemorrhoids for patients with liver cirrhosis. We confirmed the efficacy and safety of ALTA sclerotherapy for haemorrhoidal patients with liver cirrhosis. Using 3D-PDA, we could visualize three-dimensionally the hemorrhoid plexus in patients with liver cirrhosis.

Keywords: Haemorrhoids, Liver Cirrhosis, ALTA, Transanal Ultrasonography

1. Background

The prevalence of hemorrhoids in patients with liver cirrhosis ranges between 21% and 79% and does not differ from that in those without liver cirrhosis (1-5). Their development seems to be independent of the severity of liver disease and portal hypertension (1-5). Symptomatic haemorrhoids in liver cirrhosis have a prevalence of approximately 5% similar to that in the general population (6) and are difficult to handle due to rich collateral circulation and possible concomitant coagulo-therapy (5).

We reported that transanal ultrasonography could visualize the hemorrhoid plexus and the course of haemorrhoidal artery *in vivo* (7, 8).

2. Objectives

The purpose of this research was to investigate the efficacy and safety of ALTA sclerotherapy in treating symptomatic haemorrhoids in patients with liver cirrhosis

and to identify the blood flow of internal haemorrhoids in patients with liver cirrhosis, using 3D-PDA.

3. Patients and Methods

All patients were diagnosed with hemorrhoids on clinical evaluation and anorectal examination including digital examination and anoscopy. Between July 2009 and December 2014, 11 patients including four male patients with a median age of 75 (67 - 81) years who had liver cirrhosis were diagnosed to have hemorrhoids. They included seven with third and four with fourth degree hemorrhoids, according to the Goligher classification.

The severity of liver cirrhosis was classified according to Child-Pugh's grading (9). They included two with grade A, eight with grade B and one with grade C liver cirrhosis. Patients' characteristics are shown in Table 1. All patients performed ALTA sclerotherapy (10, 11).

Enrolled patients underwent endoanal-endorectal ultrasonography and power Doppler imaging performed by a single operator. An ultrasound system (Xario™; Toshiba, Tokyo, Japan) fitted with endoanal-endorectal probes (PVT-770RT; Toshiba) was used.

A 2D ultrasound exploration of the haemorrhoidal tissue was initially performed. The 3D volume was then activated to obtain a 3D box from the anal canal. A single examiner performed all volume analysis. Using a 3D creation program (Fusion 3D software, Toshiba), the pelvic viscera were outlined manually in the transitional plane.

4. Results

Results of treatment are shown in Table 1, all cases could be treated using ALTA sclerotherapy and their symptoms (prolapse and/or bleeding) improved. However, two cas-

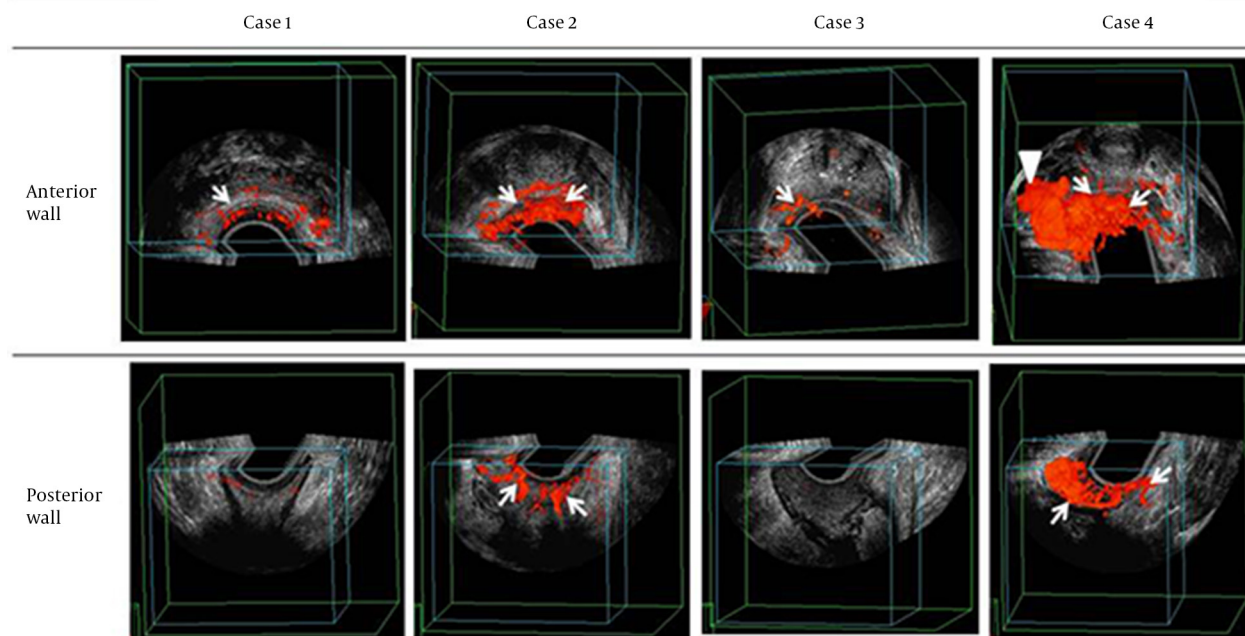
es re-prolapsed during five years. Although two patients experienced slight bleeding after treatment and three patients experienced retention of ascites, there were no serious complications.

It is possible to produce a 3D image of haemorrhoidal tissues using transanal ultrasonography to create a 3D-PDA image. The haemorrhoidal plexuses were shown in the submucosal layer of the anal canal. The 3D-PDA showed vascularization in the hemorrhoidal plexus of patients with liver cirrhosis in vivo (Figure 1). Although Cases 1, 2 and 4 had Child-Pugh's grade B, the patterns of blood flow in the hemorrhoidal tissue were different. On the one hand, Cases 1 and 3 had little blood flow in the haemorrhoidal tissue, while Cases 2 and 4 had a much greater blood flow in the haemorrhoidal tissue. Furthermore, Case 4 had anorectal varices.

Table 1. Patients' Characteristics and Results of ALTA Sclerotherapy^a

Case No.	Gender	Age, Y	Leading Symptom	Goligher Classification	Child-Pugh Classification		Dose of ALTA, mL	Symptom Relapse	Complication
					Pre	Post			
1	F	80	Prolapse	III	A	B	15	No	
2	F	81	Bleeding	IV	B	C	9	No	Slight bleeding, ascites
3	F	67	Bleeding	III	B	C	9	No	Ascites
4	M	70	Prolapse and bleeding	III	C	C	10	No	Slight bleeding, ascites
5	F	68	Bleeding	III	B	B	26	No	Serum bilirubin elevation
6	F	67	Prolapse and bleeding	IV	B	B	13	No	
7	F	79	Prolapse	III	B	B	26	No	
8	M	70	Prolapse	III	B	B	26	Slight prolapse	
9	M	76	Bleeding	III	B	B	20	No	
10	M	76	Prolapse and bleeding	IV	A	A	20	Slight prolapse	
11	F	75	Prolapse	IV	B	A	15	No	

^aAbbreviations: F, female; M, male.

Figure 1. A 3D-PDA Image of the Internal Hemorrhoid With Liver Cirrhosis

White arrows show the blood flow in the hemorrhoid plexus, Cases 1 and 3 had little blood flow in the hemorrhoidal tissue; Cases 2 and 4 had a much greater blood flow in the hemorrhoidal tissue; In case 4, white arrow head shows the blood flow in the anorectal varices.

5. Discussion

The prevalence of anorectal varices and haemorrhoids in cirrhotic patients had no relation to Child-Pugh's grading, esophageal varices with and without sclerotherapy and/or ascites. Haemorrhoids are not related to the degree of portal pressure (1-5). However, the blood flow in the haemorrhoidal tissue of patients with liver cirrhosis had not been unknown in vivo. We reported that transanal ultrasonography could visualize haemorrhoid plexus in vivo (7, 8). In this research, we could show and clarify for the first time the blood flow in haemorrhoidal tissue and anorectal varices of patients with liver cirrhosis using 3D-PDA.

Symptomatic haemorrhoids in patients with liver cirrhosis are difficult to handle due to rich collateral circulation and possible concomitant coagulopathy. There are no guidelines for the treatment of bleeding and/or prolapsed haemorrhoids in patients with liver cirrhosis. A few reports have proposed stapled hemorrhoidopexy as an effective and safe technique for symptomatic hemorrhoids in advanced liver disease (12-14). In this study, all cases could be treated using ALTA sclerotherapy (10, 11), which has been accepted in Japan as the preferred first line treatment for Goligher grade 2 or 3 internal haemorrhoids (11). We could safely perform this treatment, because there were no serious complications. Although two patients re-prolapsed, nine patients have good results. Two patients with hyper-vascularity in haemorrhoidal tissue, using 3D-PDA, experienced slight bleeding after treatment. We could predict bleeding after treatment, because we could get information

in the pre-operation phase about the blood flow of haemorrhoidal tissue in patients with liver cirrhosis using 3D-PDA.

In conclusion, ALTA sclerotherapy could bring an acceptable outcome for haemorrhoidal patients concurrent with liver cirrhosis. We could visualize the haemorrhoid plexus in patients with liver cirrhosis in vivo, using 3D-PDA. It might be useful to perform 3D-PDA to predict bleeding after treatment of haemorrhoid in patients with liver cirrhosis.

Acknowledgments

We would like to thank Professor Mitsuo Shimada, Department of Digestive and Pediatric Surgery, University of Tokushima, Tokushima, Japan for his careful advice regarding the analysis.

Footnotes

Authors' Contribution: Each author substantially contributed to take part in conception and design, acquiring, analyzing and interpreting data and all agreed to accept equal responsibility for accuracy of the contents of this paper. Hidenori Miyamoto, Tateo Nakagawa, Hideyuki Miyamoto and Atsushi Takata designed and performed research; Hidenori Miyamoto analyzed data and wrote the paper.

Funding/Support: No financial support or affiliations are associated with this study.

References

- Misra SP, Dwivedi M, Misra V. Prevalence and factors influencing hemorrhoids, anorectal varices, and colopathy in patients with portal hypertension. *Endoscopy*. 1996;**28**(4):340-5. doi: 10.1055/s-2007-1005477. [PubMed: 8813499]
- Wang TF, Lee FY, Tsai YT, Lee SD, Wang SS, Hsia HC, et al. Relationship of portal pressure, anorectal varices and hemorrhoids in cirrhotic patients. *J Hepatol*. 1992;**15**(1-2):170-3. [PubMed: 1506636]
- Jacobs DM, Bubrick MP, Onstad GR, Hitchcock CR. The relationship of hemorrhoids to portal hypertension. *Dis Colon Rectum*. 1980;**23**(8):567-9. [PubMed: 6970115]
- Bernstein WC. What are hemorrhoids and what is their relationship to the portal venous system? *Dis Colon Rectum*. 1983;**26**(12):829-34. [PubMed: 6605842]
- Kalafateli M, Triantos CK, Nikolopoulou V, Burroughs A. Non-variceal gastrointestinal bleeding in patients with liver cirrhosis: a review. *Dig Dis Sci*. 2012;**57**(11):2743-54. doi: 10.1007/s10620-012-2229-x. [PubMed: 22661272]
- Johanson JF, Sonnenberg A. The prevalence of hemorrhoids and chronic constipation. An epidemiologic study. *Gastroenterology*. 1990;**98**(2):380-6. [PubMed: 2295392]
- Miyamoto H, Asanoma M, Miyamoto H, Takasu C, Shimada M. Three-dimensional power Doppler transanal ultrasonography, to monitor haemorrhoidal blood flow after Doppler-guided ALTA sclerosing therapy. *Colorectal Dis*. 2013;**15**(2):e84-8. doi: 10.1111/codi.12024. [PubMed: 22966905]
- Miyamoto H, Asanoma M, Miyamoto H, Takasu C, Masamune K, Shimada M. Visualization and hypervascularization of the haemorrhoidal plexus in vivo using power Doppler imaging transanal ultrasonography and three-dimensional power Doppler angiography. *Colorectal Dis*. 2013;**15**(11):e686-91. doi: 10.1111/codi.12406. [PubMed: 24034699]
- Pugh RN, Murray-Lyon IM, Dawson JL, Pietroni MC, Williams R. Transection of the oesophagus for bleeding oesophageal varices. *Br J Surg*. 1973;**60**(8):646-9. [PubMed: 4541913]
- Altomare DF, Giuratrabocchetta S. Conservative and surgical treatment of haemorrhoids. *Nat Rev Gastroenterol Hepatol*. 2013;**10**(9):513-21. doi: 10.1038/nrgastro.2013.91. [PubMed: 23752820]
- Miyamoto H. Sclerotherapy: Procedures, Potential Complications and Clinical Outcomes. In: Brown ER, editor. *ALTA sclerotherapy: the new sclerotherapy for curing advanced internal hemorrhoids*. New York: Nova Science Publishers, Inc; 2014. pp. 149-64.
- Huang WS, Lin PY, Chin CC, Yeh CH, Hsieh CC, Chang TS, et al. Stapled hemorrhoidopexy for prolapsed hemorrhoids in patients with liver cirrhosis; a preliminary outcome for 8-case experience. *Int J Colorectal Dis*. 2007;**22**(9):1083-9. doi: 10.1007/s00384-007-0271-5. [PubMed: 17334772]
- Zaher T, Ibrahim I, Ibrahim A. Endoscopic band ligation of internal haemorrhoids versus stapled haemorrhoidopexy in patients with portal hypertension. *Arab J Gastroenterol*. 2011;**12**(1):11-4. doi: 10.1016/j.ajg.2011.01.009. [PubMed: 21429448]
- Awad AE, Soliman HH, Saif SA, Darwish AM, Mosaad S, Elfert AA. A prospective randomised comparative study of endoscopic band ligation versus injection sclerotherapy of bleeding internal haemorrhoids in patients with liver cirrhosis. *Arab J Gastroenterol*. 2012;**13**(2):77-81. doi: 10.1016/j.ajg.2012.03.008. [PubMed: 22980596]