

Perianal Paget's Disease in a Forty-Five-Year-Old Man and Review of the Literature

Yavar Shams Hojjati,¹ Abbas Abdollahi,^{2*} Ghodrattollah Maddah,³ and Asieh Sadat Fattahi³

¹Department of Surgery, Mashhad University of Medical Sciences, Mashhad, IR Iran

²Surgical Oncology Research Center, Mashhad University of Medical Sciences, Mashhad, IR Iran

³Endoscopic and Minimally Invasive Surgery Research Center, Mashhad University of Medical Sciences, Mashhad, IR Iran

*Corresponding author: Abbas Abdollahi, Surgical Oncology Research Center, Mashhad University of Medical Sciences, Mashhad, IR Iran. Tel: +98-5138022677, Fax: +98-5138525255, E-mail: abdollahia@mums.ac.ir

Received 2015 April 07; Revised 2015 May 06; Accepted 2015 May 19.

Abstract

Introduction: Extramammary Paget's disease is a rare neoplasm of the skin that might develop in perianal region. Although different management options are available, wide local excision is still the method of choice.

Case Presentation: A 45-year-old man presented with perianal itchy lesions for one year with no response to local treatments. Perianal Paget's disease was diagnosed by performing a surgical biopsy. Wide excision and flap reconstruction was done, while loop sigmoid colostomy was performed for fecal diversion. Re-excision of the involved margins was performed during the second operation.

Conclusions: A good outcome and no recurrence or complications was noticed in a follow-up period of 24 months. It is important to consider this uncommon disease as a probable diagnosis when evaluating a perianal lesion.

Keywords: Paget Disease Extramammary, Perianal Glands, Local Excision

1. Introduction

Extramammary Paget's disease is one of the rare skin malignancies that mainly involves the areas of the body with apocrine glands, eg, the vulva, scrotum, and perianal region (1). The first report of perianal Paget's disease was published in 1893, cited in Vergati et al. (2). The disease mainly occurs in white women, usually in the sixth to eighth decades of life (3).

The most common complaint of the patients is itching, reported in more than two-thirds of patients. Some patients have complaints from tingling, pain, bleeding, and swelling, while about 10% of cases are asymptomatic. Interestingly, perianal Paget's disease is even rarely diagnosed accidentally following hemorrhoidectomy or fissurectomy (4-6).

In a study, it is reported that the median time from symptom onset to diagnosis of the disease was 27.3 months (5).

The main differential diagnoses of perianal Paget's disease are candidiasis, seborrheic dermatitis, psoriasis, Bowen's disease, and pruritus ani. Histologically, this disease is consisted of large cells with clear cytoplasm in the basal layer; mostly they are single, and sometimes as cell nests and glandular structures. This tissue contains some degree of mucin, which helps differentiate Paget's disease from melanoma and Bowen's disease (7, 8).

Various methods such as abdominal perineal resection, Mohs micrographic, radiotherapy, chemotherapy, photodynamic therapy, and anti-androgen therapy have been proposed for the treatment of the disease, but wide local excision is still considered as the best treatment method in most studies (9).

Here, we introduced a patient with perianal Paget's disease presented as perianal itchy lesions and underwent surgical treatment.

2. Case Presentation

A 45-year-old man presented with perianal itchy lesions for one year and had used different local treatments (topical antifungal and local corticosteroid drugs) without curative effect. The patient had a family history of diabetes and hypertension. Examinations showed an erythematous lesion with mild tenderness that affects almost all perianal regions with 1 to 4 cm from the anus. No abnormal findings were detected in digital rectal examination. The evaluation of other parts of the body showed no pathologic findings.

Surgical biopsy and histopathologic evaluation of the lesions demonstrated islands of Pagetoid cells and some duct-like structures composed of cells with clear cytoplasm and large atypical nuclei, some with signet ring feature in the basal layer of the squamous epithelium (Figure 1).

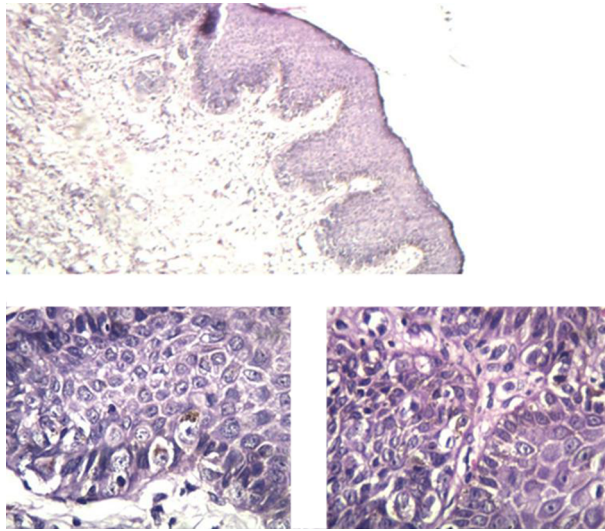


Figure 1. Microscopic Views of the Perianal Lesion

Colonoscopy was also performed for complete evaluation and found no other lesions. Finally, the patient became candidate for surgical treatment with the diagnosis of perianal Paget's disease. Therefore, perianal lesion was removed with wide excision and margin of at least 20 mm. Bilateral posterior gluteal thigh flap was used for the reconstruction for the created defect. Due to the use of wide flaps in perianal region, loop sigmoid colostomy was performed for fecal diversion. Considering to the marginal involvement of the excised region reported by pathologist, re-excision of involved part was performed in the second operation (Figure 2). He had no recurrence or complications in a follow-up period of 24 months.

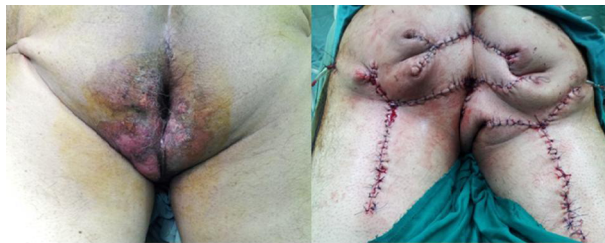

Figure 2. Perianal Lesion Before and After Surgical Removal

3. Discussion

Paget's disease of the breast was first introduced by Paget. He introduced 15 patients with underlying intraductal carcinoma (10). In 1889, Crocker introduced the first

case of extramammary Paget's with scrotal and penile involvement (11). In 1893, Darier and Couillaud reported the first case of perianal Paget's disease; cited in Vergati et al. (2). In 1901, the first report of vulvar Paget's disease was reported by Dubreuilh (12).

Extramammary Paget's disease is a rare neoplasm of the skin and its exact incidence is unknown. Patients are mostly white women of 50 to 80 years of age (3). Familial incidence of the disease has been rarely reported (13). Most common areas affected in extramammary Paget's are consecutively vulva, perineal regions, perianal region, scrotum and penis, and occasionally axilla, buttock, thigh, eyelid, and external auditory canal (1). Paget's disease is even possible to simultaneously occur in two distinct anatomical regions (14).

Unlike the Paget's disease of the breast, which is almost always associated with an underlying malignancy in the breast, extramammary Paget's may not accompany or associate with other malignancies. However, if there is any associated internal malignancy, the location of extramammary Paget's can be a sign of the underlying malignancy. For example, perianal Paget's disease can be associated with gastrointestinal adenocarcinoma and the Paget's involving the scrotum, penis, and groin can be associated with malignancy of the genitourinary system (15).

Perianal Paget's disease is mainly an intraepithelial carcinoma placed at a distance of 6 cm from the anus below the dentate line. The most common symptom is itching with the prevalence of approximately 70%. Other patients' complaints include feeling of irritation, pain, bleeding, and swelling. The disease is asymptomatic in 10% of patients (4). Initially, the lesion is typically dry, erythematous, and raised; later, it may turn into a crusted, eczematoid, ulcerated, or papillary lesion. The lesions have sharply defined margins with plaques and also distinct erythema (1).

Various differential diagnoses are suggested for extramammary Paget's disease including lichen sclerosis, seborrheic dermatitis, fungal infection, psoriasis, contact dermatitis, melanoma, anogenital intraepithelial neoplasia, mycosis fungoides, and histiocytosis (16). Perianal and vulvar Paget's disease may be mistaken for leukoplakia, hidradenitis suppurativa, Crohn's disease, condylomata accuminata, squamous cell carcinoma, and basal cell carcinoma (17).

Most patients experience long-term use of anti-fungal treatments and local corticosteroid. Skin biopsy should be performed for such lesions that have received standard local treatment for four to six weeks without response (3, 4, 17).

Definitive diagnosis is established by histopathologic and immunohistochemical examination of the specimen. Histopathologically, the Paget's disease is characterized in

the basal layer of the skin. Most cells are placed as single in the basal layer, which are pale, large, and vacuolated and are scattered throughout the epidermis. However, sometimes they are as glandular structures and cell-nests. The cells of extramammary Paget's disease are large containing clear cytoplasm and sometimes with a signet ring appearance (18).

Immunohistochemically, extramammary Paget's disease is positive for keratin, carcinoembryonic antigen (CEA) and epithelial membrane antigen (EMA) (19). In addition, it is positive for CK7 and CDGFP15 and negative for CK20. However, colorectal Paget's disease is sometimes positive for CK7, CK20, B72.3, and CD15, and is negative for CDGFP15 (18). Interestingly, extramammary Paget's disease does not have estrogen and progesterone receptors, but commonly expresses androgen receptor. Histopathologic feature of extramammary Paget's disease is being mucin-rich, although, rare variants of extramammary Paget's disease including Bowenoid and Pigmented do not have such feature (20).

In the diagnosis of extramammary Paget's disease, complete evaluation of underlying malignancy should be done. It seems that perianal Paget's disease has stronger association with underlying malignancy than vulvar Paget's disease does. Appropriate investigations include pelvic ultrasound scan, hysteroscopy, pelvic magnetic resonance imaging, laparoscopy, colonoscopy, cystoscopy, barium enema, mammography, intravenous pyelogram, and chest X-ray (4).

Various treatment methods are proposed for perianal Paget's disease including surgical and nonsurgical treatments and these methods are used either alone or in combination with another method. These methods are wide local excision and abdominoperineal resection (21), Mohs microscopic surgery (22), radiotherapy (23), chemoradiotherapy (24), photodynamic therapy, and laser therapy (25, 26). Shutze and Gleysteen offered a management classification for perianal Paget's disease (Table 1) (27). According to this classification, our patient was also candidate for wide local excision.

Anyway, surgical treatments are the main treatment methods in these patients and according to the follow-up period in different studies, best prognosis and low recurrence rates are related to the cases undergone surgical treatment (5, 23, 27).

In conclusion, surgical treatment is still the method of choice in the treatment of this disease. Here, we reported a patient with perianal Paget's disease who underwent wide local excision to draw attention to this uncommon disease. We recommend considering Paget's disease as a probable diagnosis when evaluating a perianal lesion. However, further studies are needed for better understanding and man-

Table 1. Management classification for perianal Paget's disease offered by Shutze and Gleysteen^a

Stage	Description	Management
I	Paget's cells found in perianal epidermis and adnexae without primary carcinoma	WLE
IIA	Cutaneous Paget's disease with associated adnexal carcinoma	WLE
IIB	Cutaneous Paget's disease with associated anorectal carcinoma	APR
III	Paget's disease in which associated carcinoma has spread to regional nodes	ILND + WLE/APR
IV	Paget's disease with distant metastases of associated carcinoma	CT + RT + LPM

^a Abbreviations: APR, Abdominoperineal resection; CT, Chemotherapy; ILND, Inguinal lymph node dissection; LPM, Local palliative management; RT, Radiotherapy; and WLE, Wide local excision.

agement of this disease.

Acknowledgments

The authors gratefully acknowledge Ms. M. Hassanpour for editing the manuscript.

Footnote

Authors' Contributions: Study conception and design: Yavar Shams Hojjati and Abbas Abdollahi. Acquisition of data: Abbas Abdollahi and Ghodrattollah Maddah. Analysis and interpretation of data: Abbas Abdollahi and Asieh Sadat Fattahi. Writing the manuscript: Yavar Shams Hojjati, Abbas Abdollahi, Ghodrattollah Maddah, and Asieh Sadat Fattahi.

References

- Rao VR, Henry DH. Extramammary Paget's disease. *Commun Oncol*. 2004;**1**(2):109-14.
- Vergati M, Filingeri V, Palmieri G, Roselli M. Perianal Paget's disease: a case report and literature review. *Anticancer Res*. 2012;**32**(10):4461-5. [PubMed: 23060573].
- Zollo JD, Zeitouni NC. The Roswell Park Cancer Institute experience with extramammary Paget's disease. *Br J Dermatol*. 2000;**142**(1):59-65. [PubMed: 10651695].
- Shepherd V, Davidson EJ, Davies-Humphreys J. Extramammary Paget's disease. *BJOG*. 2005;**112**(3):273-9. [PubMed: 15713139].
- Lian P, Gu WL, Zhang Z, Cai GX, Wang MH, Xu Y, et al. Retrospective analysis of perianal Paget's disease with underlying anorectal carcinoma. *World J Gastroenterol*. 2010;**16**(23):2943-8. [PubMed: 20556842].
- Beck DE, Fazio VW. Perianal Paget's disease. *Dis Colon Rectum*. 1987;**30**(4):263-6.
- Wood WS, Culling CF. Perianal Paget disease. Histochemical differentiation utilizing the borohydride-KOH-PAS reaction. *Arch Pathol*. 1975;**99**(8):442-5. [PubMed: 50063].

8. Yoshii N, Kitajima S, Yonezawa S, Matsukita S, Setoyama M, Kanzaki T. Expression of mucin core proteins in extramammary Paget's disease. *Pathol Int*. 2002;**52**(5-6):390-9. [PubMed: [12100522](#)].
9. Mengjun B, Zheng-Qiang W, Tasleem MM. Extramammary Paget's disease of the perianal region: a review of the literature emphasizing management. *Dermatol Surg*. 2013;**39**(1 Pt 1):69-75. doi: [10.1111/dsu.12019](#). [PubMed: [23127181](#)].
10. Paget J. On disease of the mammary areola preceding cancer of the mammary gland. *Cancer J Clin*. 1971;**21**(5):303-4.
11. Crocker HR. Paget's disease, affecting the scrotum and penis. *Trans Pathol Soc (London) 1888-1889*. 1889;**40**:87-191.
12. Dubreuilh W. Paget's disease of the vulva. *Br J Dermatology*. 1901;**13**(11):407-13.
13. Demitsu T, Gonda K, Tanita M, Takahira K, Inoue T, Okada O, et al. Extramammary Paget's disease in two siblings. *Br J Dermatol*. 1999;**141**(5):951-3. [PubMed: [10583201](#)].
14. Popiolek DA, Hajdu SI, Gal D. Synchronous Paget's disease of the vulva and breast. *Gynecol Oncol*. 1998;**71**(1):137-40. doi: [10.1006/gyno.1998.5136](#). [PubMed: [9784335](#)].
15. Chanda JJ. Extramammary Paget's disease: prognosis and relationship to internal malignancy. *J Am Acad Dermatol*. 1985;**13**(6):1009-14.
16. Balducci L, Crawford ED, Smith GF, Lambuth B, McGehee R, Hardy C. Extramammary Paget's disease: an annotated review. *Cancer Invest*. 1988;**6**(3):293-303. [PubMed: [2844363](#)].
17. Lloyd J, Flanagan AM. Mammary and extramammary Paget's disease. *J Clin Pathol*. 2000;**53**(10):742-9. [PubMed: [11064666](#)].
18. Goldblum JR, Hart WR. Perianal Paget's disease: a histologic and immunohistochemical study of 11 cases with and without associated rectal adenocarcinoma. *Am J Surg Pathol*. 1998;**22**(2):170-9.
19. Helm KF, Goellner JR, Peters MS. Immunohistochemical stains in extramammary Paget's disease. *Am J Dermatopathol*. 1992;**14**(5):402-7. [PubMed: [1384380](#)].
20. Fujimoto A, Takata M, Hatta N, Takehara K. Expression of structurally unaltered androgen receptor in extramammary Paget's disease. *Lab Invest*. 2000;**80**(9):1465-71. [PubMed: [11005214](#)].
21. McCarter MD, Quan SHQ, Busam K, Paty PP, Wong D, Guillem JG. Long-term outcome of perianal Paget's disease. *Dis Colon Rectum*. 2003;**46**(5):612-6.
22. Mohs FE, Blanchard L. Microscopically controlled surgery for extramammary Paget's disease. *Arch Dermatol*. 1979;**115**(6):706-8. [PubMed: [222218](#)].
23. Brown RS, Lankester KJ, McCormack M, Power DA, Spittle MF. Radiotherapy for perianal Paget's disease. *Clin Oncol (R Coll Radiol)*. 2002;**14**(4):272-84. [PubMed: [12206637](#)].
24. Balducci L, Athar M, Smith GF, Khansur T, McKenzie D, Crawford ED. Metastatic extramammary Paget's disease: dramatic response to combined modality treatment. *J Surg Oncol*. 1988;**38**(1):38-44. [PubMed: [2836660](#)].
25. Runfola MA, Weber TK, Rodriguez-Bigas MA, Dougherty TJ, Petrelli NJ. Photodynamic therapy for residual neoplasms of the perianal skin. *Dis Colon Rectum*. 2000;**43**(4):499-502. [PubMed: [10789745](#)].
26. Becker-Wegerich PM, Fritsch C, Schulte KW, Megahed M, Neuse W, Goerz G, et al. Carbon dioxide laser treatment of extramammary Paget's disease guided by photodynamic diagnosis. *Br J Dermatol*. 1998;**138**(1):169-72. [PubMed: [9536242](#)].
27. Shutze WP, Gleysteen JJ. Perianal Paget's disease. Classification and review of management: report of two cases. *Dis Colon Rectum*. 1990;**33**(6):502-7. [PubMed: [2161727](#)].