

Successfully Treated Pediatric Patient With Megarectum by Vertical Reduction Rectoplasty

Ibrahim Akkoyun^{1,*}

¹Department of Pediatric Surgery, Konya Education and Research Hospital, Konya, Turkey

*Corresponding author: Ibrahim Akkoyun, Department of Pediatric Surgery, Konya Education and Research Hospital, Konya, Turkey. Tel: +90-5324742886, Fax: +90-3323236723, E-mail: ibrahimakkoyun@yahoo.com

Received: September 11, 2014; Accepted: September 15, 2014

This report represents successful treatment of a seven-year-old boy with megarectum, who complained of intractable constipation and encopresis, by vertical reduction rectoplasty.

Keywords: Megacolon; Child; Constipation

1. Introduction

Megarectum can develop in some patients with intractable constipation. Because of excessive laxity and hypomotility of the rectum, the threshold of sensation in the rectum is increased and leads to rectal fullness in presence of poor perception (1). Finally, more stool accumulates in megarectum and encopresis occurs. This problem is an extremely annoying status for the child and family. Many surgical procedures have been recommended for megarectum including anterior resection, proctectomy, endorectal pull-through, and Duhamel operation with highly variable success and morbidity rates. The novel technique for the treatment of megarectum is vertical reduction rectoplasty (VRR), which is reported to be performed only in 16 adult patients (1, 2). Here we presented a child with megarectum and concomitant intractable constipation and encopresis, who was successfully treated. This case was the first pediatric patient case in the English language literature.

2. Case Presentation

A seven-year old boy, who had been admitted to the different treatment centers due to constipation starting from the age of 18 months, was attempted to be treated with dietary recommendations, high-dose oral laxatives, rectal liquid enemas, and repetitive manual evacuation. The patient was enrolled in bowel management program upon no response to treatment and the onset of encopresis; however, no recovery occurred. The patient could defecate spontaneously only once or twice a month and had encopresis several times a day in last two years. In our evaluations, there were no dysfunctional voiding symptoms. The patient had a shy, introverted, anxious mood in physi-

cal examination; therefore, consultation with Child Psychiatry Department was made and anxiety was diagnosed.

On physical examination, localization of the anus was normal. Normal anal sphincter tone was found on the rectal digital examination. The rectum was dilated and fully filled with hard stool. The diameter of the rectum was 6 cm in Barium enema studies. In anorectal manometry, anal canal resting and squeeze pressures were normal; delay in the sense of the first and urgent bowel movements were seen while rectoanal inhibitor reflex was normal. Rectal fullness perception was at 60 mL (normal, 17-23 mL). Colonic transit studies and evacuation proctography were not performed due to the concerns of continuous fecal incontinence, no contribution to the diagnosis, and possibility of delay in treatment. Findings of urinary system ultrasonography and spinal magnetic resonance were normal.

After the decision of surgical treatment, the patient was operated and right transverse loop colostomy and full-thickness rectal biopsy were performed at the same session. Antegrade irrigations were started on postoperative day five and education regarding irrigation and colostomy care was given to the parents. Hirschsprung's disease, neuronal intestinal dysplasia, dysganglionosis, or hypoganglionosis were not detected in rectal biopsy specimens. Five months later, dilated sigmoid colon segment resection (about 3 cm) and VRR were performed as described by Williams et al. (2) (Figures 1 and 2). His colostomy was closed upon normal distal colostogram performed after two months. There was no complication in operations. After colostomy closure, the patient had watery stools five to six times a day and sometimes, fecal incontinence, which were recovered without treatment in one month. at the time of reporting this case, our patient was in postoperative month five, constipation diet was not applied, he was

not receiving oral laxative or rectal enema treatment, and defecated once a day painlessly and the stool had normal consistency. He gained 5 kg in the last five months and he was happy with healthy appearance.

3. Discussion

Constipation is a common chronic disorder in children. The treatment of patients with intractable constipation who fail to respond to conventional modalities is challenging because dilatation of the rectum because of intractable constipation and encopresis makes the treatment harder, and causes psychologic and social problems for the child and family. Even dysfunctional voiding can be seen in these patients. Several surgical procedures are recommended for megarectum including anterior resection, proctectomy, endorectal pull-through, and Duhamel operation. Their success and morbidity rates are highly variable and even death has been reported (1).

VRR is a novel technique described in the surgical treatment of megarectum. In this technique, reduction of rectum capacity is achieved by linear plan excision of the antimesenteric section of the enlarged rectum and thus, restores perception of rectal fullness and improves sensation and bowel function. According to the available literature, only 16 adult patients in two case series were operated via this technique; Williams et al. who are the first to describe this technique, reported 83% success rate, 33% morbidity, and no mortality in these patients (2, 3).

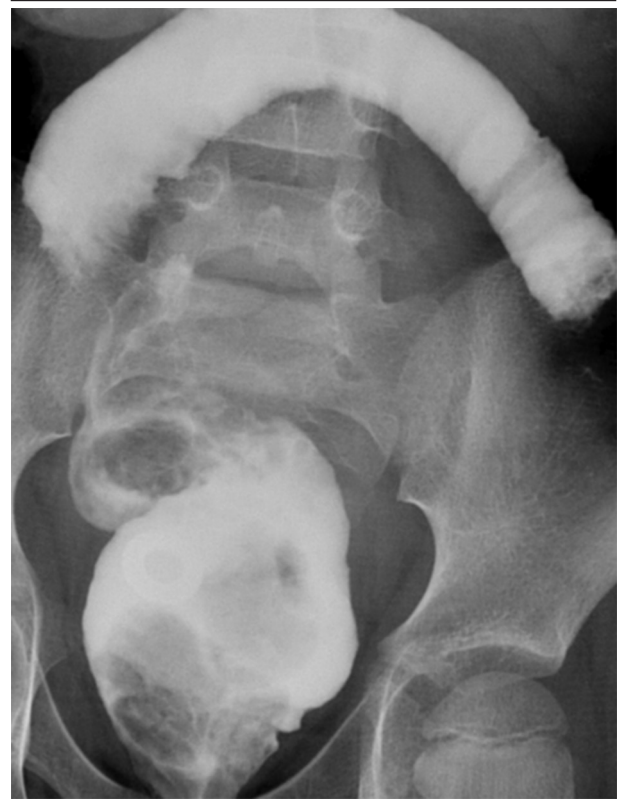
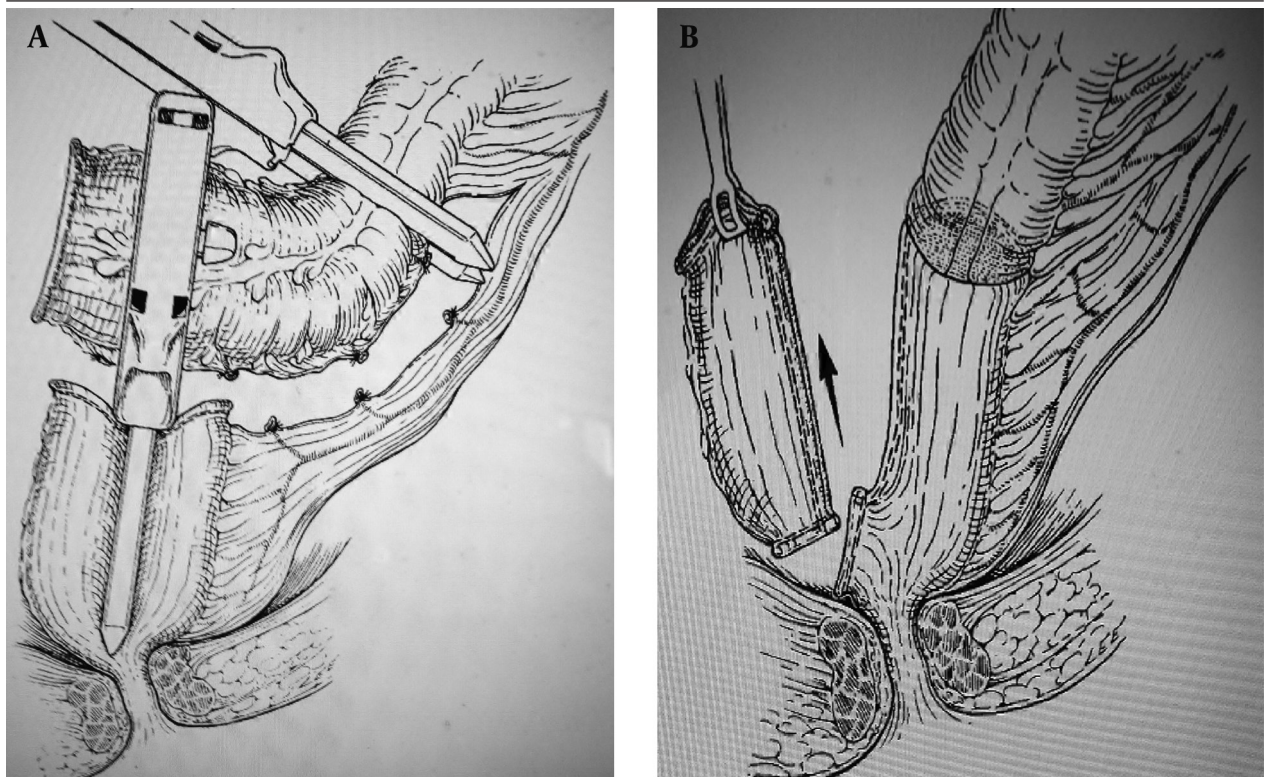


Figure 1. Vertical Reduction of Megarectum and Excision of Dilated Segment of Sigmoid Colon

Figure 2. Anterior Half of Rectum is Removed After Resection of its Distal Connection With the Anorectum



The Reduced Rectum Was Then Anastomosed With the Proximal Descending Colon

The average diameter of the rectum is 2.1 cm in normal children (4). It was 6 cm in our patient and was reduced to 3 cm via a linear stapler device (TCT 60 mm; Ethicon Cincinnati, Ohio, the United States) from antimesenteric border. After resecting dilated sigmoid colon segment up to the peritoneal reflection level, anastomosis of distal end of the descending colon in diameter of 3 cm to proximal end of the rectum was performed by using a 31 mm circular stapler device (Figures 1 and 2).

Not complication was observed in our patient by the postoperative month five; restoring the habit of normal defecation without receiving any treatment and lack of encopresis was a very pleasing result for the child and parents. In addition, complete success and ease of this new technique can also show its applicability on children with megarectum and concomitant intractable constipation and encopresis. Currently, there is no experience of performing VRR without protective colostomy and this can be considered as a disadvantage. However, other

techniques for treatment of megarectum are generally required for creating protective colostomy/ileostomy. Our patient was the first pediatric case who was successfully treated by VRR for megarectum. Case reports from other centers would show the applicability and success of this technique in children in the future.

References

1. Gladman MA, Williams NS, Scott SM, Ogunbiyi OA, Lunniss PJ. Medium-term results of vertical reduction rectoplasty and sigmoid colectomy for idiopathic megarectum. *Br J Surg.* 2005;**92**(5):624-30.
2. Williams NS, Fajobi OA, Lunniss PJ, Scott SM, Eccersley AJ, Ogunbiyi OA. Vertical reduction rectoplasty: a new treatment for idiopathic megarectum. *Br J Surg.* 2000;**87**(9):1203-8.
3. Gladman MA, Scott SM, Lunniss PJ, Williams NS. Systematic review of surgical options for idiopathic megarectum and megacolon. *Ann Surg.* 2005;**241**(4):562-74.
4. Klijn AJ, Asselman M, Vijverberg MA, Dik P, de Jong TP. The diameter of the rectum on ultrasonography as a diagnostic tool for constipation in children with dysfunctional voiding. *J Urol.* 2004;**172**(5 Pt 1):1986-8.