

## Malignant Neoplasms of the Anal Canal

Shapour Omidvari<sup>1</sup>, Sayed Hasan Hamedi<sup>2</sup>, Mohammad Mohammadianpanah<sup>3,\*</sup>, Samira Razzaghi<sup>2</sup>, Hamid Nasrolahi<sup>1</sup>, Ahmad Mosalaei<sup>4</sup>, Niloofar Ahmadloo<sup>1</sup>, Mansour Ansari<sup>1</sup>

<sup>1</sup>Department of Radiation Oncology, Namazi Hospital, Shiraz University of Medical Sciences, Shiraz, IR Iran

<sup>2</sup>Student Research Committee, Resident of Radiation Oncology, Namazi Hospital, Shiraz University of Medical Sciences, Shiraz, IR Iran

<sup>3</sup>Colorectal Research Center, Shiraz University of Medical Sciences, Shiraz, IR Iran

<sup>4</sup>Shiraz Institute for Cancer Research, Shiraz University of Medical Sciences, Shiraz, IR Iran

\*Corresponding author: Mohammad Mohammadianpanah, Colorectal Research Center, Shiraz University of Medical Sciences, Shiraz, IR Iran, Tel.: +98-7116125170, Fax: +98-7116474320, Email: mohpanah@sums.ac.ir

Received: May 05, 2013; Revised: Jun 08, 2013; Accepted: Jun 17, 2013

**Background:** Malignant neoplasms of the anal canal are rare accounting for approximately 4% of all colorectal malignancies.

**Objectives:** The present study aimed to report the clinicopathological characteristics and treatment outcomes of 41 cases with malignant neoplasms of the anal canal.

**Patients and Methods:** Between 1999 and 2012, 41 consecutive patients were diagnosed with primary malignant neoplasm of the anal canal which were treated and followed up at Namazi hospital. Only primary malignant tumors arising from the anal canal were included. Patients with secondary anal canal involvement from rectal or perianal skin cancers and metastatic tumors were excluded.

**Results:** There were 22 women and 19 men, age ranging from 33 to 83 years, with a median age of 57 years at diagnosis. Sixteen patients (39%) had localized disease, 21 (51%) had regional disease, and 4 (10%) had metastatic disease at diagnosis. Squamous cell carcinoma (61%) was the most frequent histologic subtype, followed by adenocarcinoma (27%), malignant melanoma (10%), and gastrointestinal stromal tumor (2%). After a median follow-up of 51 (11-169) months for surviving patients, 22 patients were alive and without disease, three were alive with disease, and 19 patients died due to the disease. Histological subtype ( $P=0.001$ ), and stage of disease ( $P=0.002$ ) were prognostic factors for overall survival. The 5-year local control, disease-free, and overall survival rates for all patients were 63.9%, 53%, and 59.4% respectively.

**Conclusions:** This study indicated that squamous cell carcinoma, adenocarcinoma, and malignant melanoma are the most frequent malignant neoplasms in the anal canal. Histological subtype and disease stage are the most important prognostic factors for overall survival in this region.

**Keywords:** Malignant Neoplasms; Anal canal Carcinoma Squamous Cell; Adenocarcinoma; Melanoma; Gastrointestinal Stromal Tumor

### 1. Background

The anal canal anatomically extends from the anorectal ring to the anal verge. It is the distal end of the large bowel and has 3-5 cm length. This region is covered by columnar epithelium at upper portion which transitions into squamous epithelium at the dentate line (1). Malignant neoplasms of the anal canal are relatively rare accounting for approximately 4% of all colorectal malignancies and 2.2% of digestive system cancers. In the United States, 6230 new cases and 780 deaths from anal canal cancer occurred in 2012. In contrast to the rapid decline in colorectal cancer incidence and mortality rates in the recent decade, the incidence and mortality rates of anal canal cancers have increased significantly over the past three decades (2). The incidence of the anal canal cancers

showed a rapid increase by approximately 6% per year from 2007 to 2012. This increase has been more prominent in men than women (2-4). These neoplasms usually occur in the sixth and seventh decades of life and the median age at diagnosis is 61 years (4). Male patients are relatively younger than female ones (58 versus 65 years). Anal canal malignancies are more frequent among women than men with a female/male ratio of 1.5-3.5 in reported series (5, 6).

The pathogenesis of anal canal cancers is multifactorial. Human papilloma virus (HPV) infection, immunosuppression, particularly due to human immunodeficiency virus (HIV), cigarette smoking, and receptive anal intercourse are the most important risk factors for anal canal cancers. Accordingly, anal canal cancers are more similar to genital malignancies rather than those of colorectal origin (7, 8).

#### Implication for health policy/practice/research/medical education:

Anal canal cancers include a diverse group of tumors. A significant portion of these neoplasms may mimic the signs and the symptoms of nonmalignant lesions such as anal fissure, hemorrhoids, eczema or fistula. Therefore, a biopsy is suggested for avoiding misdiagnosis in any patients with nonresponding anal lesion to conservative therapy.

Copyright © 2013, Colorectal Research Center and Health Policy Research Center of Shiraz University of Medical Sciences. This is an Open Access article distributed under the terms of the Creative Commons Attribution License (<http://creativecommons.org/licenses/by/3.0>), which permits unrestricted use, distribution, and reproduction in any medium, provided the original work is properly cited.

Anal bleeding and pain are the most common presentation in these patients; however, pruritus, anal discharge, and the sensation of an anal mass are other frequent signs and symptoms. A remarkable portion of these neoplasms may mimic the signs and the symptoms of nonmalignant lesions such as anal fissure, hemorrhoids, eczema or fistula. Therefore, a biopsy is suggested for avoiding misdiagnosis in any patients with nonresponding anal lesion to conservative therapy (6, 8, 9). Anal canal cancers include a diverse group of tumors. Squamous cell carcinoma is the most common histologic type followed by adenocarcinoma, malignant melanoma, neuroendocrine tumors, basal cell carcinoma, small cell carcinoma, sarcoma, and lymphoma (7-9).

## 2. Objectives

The present study aimed to report the clinicopathological characteristics, and treatment outcomes of 41 cases with malignant neoplasms of the anal canal.

## 3. Patients and Methods

### 3.1. Population study and patient evaluation

Between 1999 and 2012, 41 consecutive patients diagnosed with primary malignant neoplasm of the anal canal treated and followed up at Namazi hospital were selected for the present study. Only primary malignant tumors arising from the anal canal were included. Patients with secondary anal canal involvement from the rectal or perianal skin cancers and metastatic tumors were excluded. The tumors were pathologically staged according to the 7th edition of the American Joint Committee on Cancer (AJCC) staging system (10). Clinical staging was performed using imaging studies in patients treated with nonsurgical therapies. Preliminary evaluation included comprehensive history and physical examination, digital rectal examination, gynecologic exam and screening of cervical cancer for women, chest x-ray, anoscopy, colonoscopy, abdominal and pelvic ultrasonography and computed tomography (CT) scans and/or pelvic MRI and/or endorectal ultrasonography.

### 3.2. Treatment Modalities

Definitive chemoradiation was considered as primary treatment for most patients with squamous cell carcinoma and adequate sphincter function. However, patients with involvement of external anal sphincter and poor sphincter function were managed by abdominoperineal resection with or without adjuvant (or neoadjuvant) chemoradiation. In addition, nonresponding tumors and recurrent cases following initial chemoradiation were treated with abdominoperineal resection. On the other hand, combined treatment modalities including abdominoperineal resection and chemoradiation were

applied for all patients but two with anal canal adenocarcinoma. Two remaining patients were treated by surgery alone or no any therapy due to patient's refusal. Metastatic malignant melanomas were treated with systemic therapy (chemotherapy with dacarbazine and/or alpha interferon) alone; however, locoregional cases were managed by combined local treatment modalities including abdominoperineal resection and radiation. A patient with gastrointestinal stromal tumor was treated with neoadjuvant imatinib followed by submucosal sphincter conserving surgery (Table 1).

**Table 1.** Distribution of Treatment Modalities and Histologic type in 41 Patients with Anal Canal Malignancies

Treatment modalities	Histologic type				Total
	SCC*	ADC*	MM*	GIST*	
<b>Chemoradiation alone</b>	12	0	2	0	14
<b>Chemoradiation, surgery</b>	0	1	0	0	1
<b>Surgery, adjuvant chemoradiation</b>	11	5	2	0	18
<b>Surgery, adjuvant radiotherapy</b>	1	0	0	0	1
<b>Chemoradiation surgery chemotherapy</b>	0	3	0	0	3
<b>Imatinib therapy followed by surgery</b>	0	0	0	1	1
<b>Surgery alone</b>	1	1	0	0	2
<b>No treatment</b>	0	1	0	0	1
<b>Total</b>	25	11	4	1	41

\* Abbreviations: SCC, squamous cell carcinoma; ADC, adenocarcinoma; MM, malignant melanoma; GIST, gastrointestinal stromal tumor

### 3.3. Chemoradiation

Neoadjuvant or definitive chemoradiation included conventional external beam radiotherapy using megavoltage linear accelerator photons. Radiation portals included the whole pelvis, anus, perineum, and inguinal nodes. A median dose of 50 (range 45-50.4) Gy external beam radiotherapy was delivered via a daily fraction of 1.8-2 Gy, with five fractions per week. Five patients received a median additional boost of 14 (range 10-24) Gy using a perineal external beam field or intracavitary low-dose rate brachytherapy. Concurrent chemotherapy consisted of intravenous bolus 5-FU 425 mg/m<sup>2</sup> on days one to five and days 29 to 33 with mitomycin C 10 mg/m<sup>2</sup> on days one and 29; or oral capecitabine 825 mg/m<sup>2</sup> twice daily during the whole period of radiotherapy with week-end breaks; or intravenous bolus 5-FU 425 mg/m<sup>2</sup> every on days one to five and days 29 to 33 with cisplatin 70 mg/m<sup>2</sup> on days one and 29.

In patients with anal canal adenocarcinoma, adjuvant chemotherapy consisted of capecitabine 1000 mg/m<sup>2</sup>

twice daily for 14 of every three weeks cycle plus oxaliplatin 130 mg/m<sup>2</sup> intravenously on day 1 (CAPEOX regimen); or 5-fluorouracil 200 mg/m<sup>2</sup> bolus day 1, followed by bolus 5-FU 400 mg/m<sup>2</sup> and then 5-FU 600 mg/m<sup>2</sup> over 22-hour infusion days 1 and 2, (FOLFOX regimen).

### 3.4. Statistics

Clinical and pathological variables were analyzed using the SPSS for Windows version 17 statistical software (SPSS, Chicago, IL). Univariate analysis for disease free and overall survival rates were performed using the Kaplan-Meier method, and prognostic factors were compared using the log-rank test. Multiple-covariate analysis was performed using the stepwise regression hazards regression model. The hazard ratio (HR) for death, with 95% confidence interval (CI) was calculated for the variable groups. The stratified log-rank test was used to compare treatment results in each variable group. All P values were 2-tailed, and P values less than 0.05 were considered statistically significant.

## 4. Results

There were 22 women and 19 men age ranging from 33 to 83 years, with a median age of 57 years at diagnosis (Table 2). Sixteen patients (39%) had localized (stage I-II) disease, 21 (51%) had regional (stage III) disease, and 4 (10%) had metastatic (stage IV) disease at diagnosis. Squamous cell carcinoma (61%) was the most frequent histologic type, followed by adenocarcinoma (27%), malignant melanoma (10%), and gastrointestinal stromal tumor (2%). (Tables 3 and 4) After a median follow-up of 51 (11-169) months for surviving patients, 22 patients were alive and without disease, three were alive with disease, and 19 patients died due to disease. The 5-year local control, disease-free, and overall survival rates for all patients were 63.9%, 53%, and 59.4%, respectively (Figures 1, 2 and 3). The 5-year local control, disease-free, and overall survival rates for patients with squamous cell carcinoma were 88%, 74.6%, and 77%, respectively.

**Table 2.** Distribution of Patients' Demographics and Histologic Type in 41 Patients with Anal Canal Malignancies.

Characteristics	Histologic type				P value
	SCC*	ADC*	MM*	GIST*	
Mean age	60.9	60.3	53	33	0.099
Sex					0.295
Male	10	4	3	1	
Female	15	7	1	0	

\* Abbreviations: SCC, squamous cell carcinoma; ADC, adenocarcinoma; MM, malignant melanoma; GIST, gastrointestinal stromal tumor

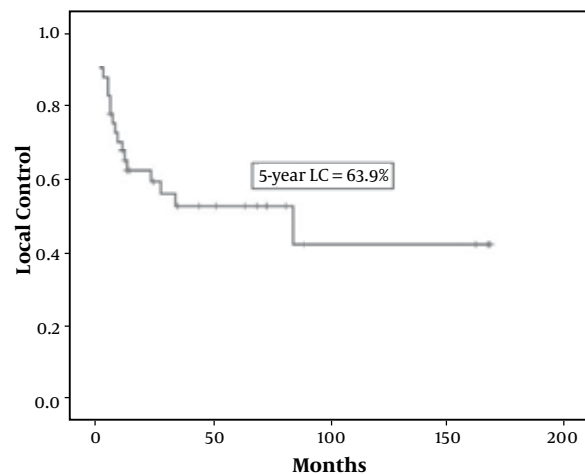
**Table 3.** Distribution of Disease Stage and Histologic Type in 41 Patients with Anal Canal Malignancies

Stage	Histologic type				Total
	SCC*	ADC*	MM*	GIST*	
Localized disease	10	5	0	1	16
Regional disease	14	5	2	0	21
Metastatic disease	1	1	2	0	4
Total	25	11	4	1	41

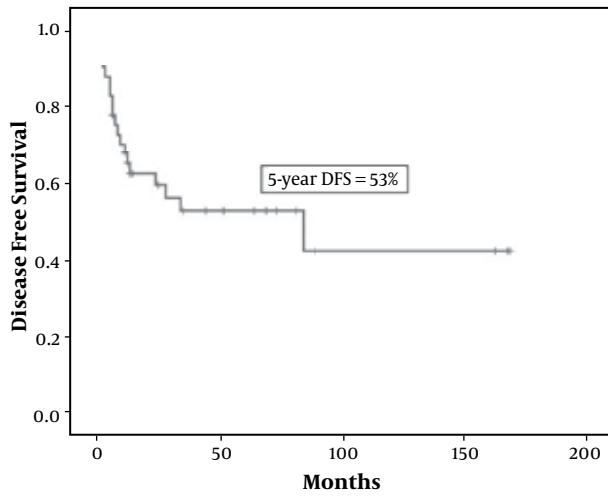
\* Abbreviations: SCC, squamous cell carcinoma; ADC, adenocarcinoma; MM, malignant melanoma; GIST, gastrointestinal stromal tumor

**Table 4.** Distribution of Treatment Modalities and Disease Stage in 41 Patients with anal Canal Malignancies

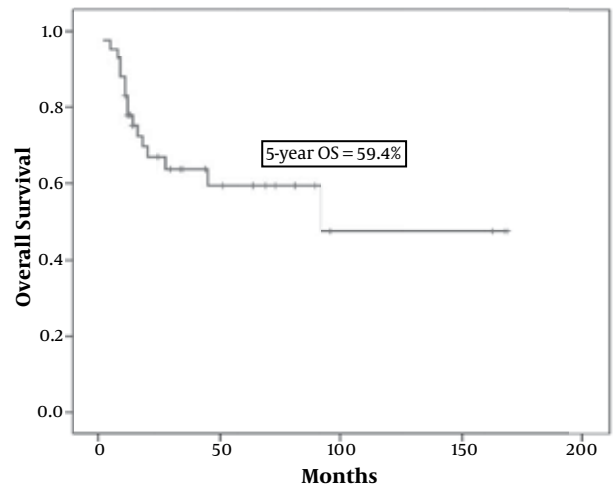
Treatment modalities	Stage			Total
	Localized	Regional	Metastatic	
Chemoradiation alone	2	9	3	14
Chemoradiation, surgery	1	0	0	1
Surgery adjuvant chemoradiation	7	10	1	18
Surgery adjuvant radiotherapy	1	0	0	1
Chemoradiation surgery chemotherapy	2	1	0	3
Imatinib therapy, surgery	1	0	0	1
Surgery alone	2	0	0	2
No treatment	0	1	0	1
Total	16	21	4	41



**Figure 1.** Kaplan-Meier Survival Curves of 5-year Local Control in 41 Patients with Anal Canal Cancer



**Figure 2.** Kaplan-Meier survival curves of 5-year disease-free survival in 41 patients with anal canal cancer



**Figure 3.** Kaplan-Meier survival curves of 5-year overall survival in 41 patients with anal canal cancer

**Table 5.** Prognostic Factors for 5-year Disease Free- and Overall Survival in 41 Patients with Anal Canal Cancer

Variables	No.	5-year DFS *, %	P value	5-year OS *, %	P value
<b>Age, y</b>			0.426		0.276
< 60	25	57.6		66.3	
≥ 60	16	45.6		46.8	
<b>Sex</b>			0.511		0.095
Male	17	49.6		46.4	
Female	22	56.4		69.9	
<b>Stage</b>			<0.001		0.001
Localized, stage I-II	16	68.1		82.0	
Regional, stage III	21	52.4		56.3	
Metastatic, stage IV	4	00.0		00.0	
<b>Histologic type</b>			<0.001		0.002
Squamous cell carcinoma	25	72.2		77.0	
Adenocarcinoma	11	27.3		43.6	
Malignant melanoma	4	00.0		00.0	
<b>Tumor grade</b>			0.044		0.246
Well differentiated	16	72.2		71.3	
Moderately differentiated	12	47.6		49.2	
Poorly differentiated	13	36.9		51.9	
<b>Treatment modality</b>			0.233		0.793
Chemoradiation alone	14	62.9		69.6	
Combined therapy	23	54.1		55.7	
Other treatments	4	00.0		50.0	

\* Abbreviations: DFS, Disease Free Survival; OS, Overall Survival

**Table 6.** Prognostic Factors for 5-year Disease Free- and Overall Survival in 25 Patients with Squamous Cell Carcinoma of Anal Canal Cancer

Variables	No.	5-year DFS *, %	P value	5-year OS *, %	P value
<b>Age, y</b>			0.730		0.385
< 60	14	77.9		83.3	
≥ 60	11	70.1		68.2	
<b>Sex</b>			0.254		0.118
Male	10	70.0		64.3	
Female	15	78.3		84.0	
<b>Stage</b>			0.248		0.491
Stage I-II	10	90.0		90.0	
Stage III-IV	15	66.7		72.0	
<b>Tumor grade</b>			0.232		0.442
Well differentiated	9	88.9		85.7	
Moderately differentiated	8	72.9		65.6	
Poorly differentiated	8	62.5		72.9	
<b>Treatment modality</b>			0.098		0.001
Chemoradiation alone	12	73.3		81.8	
Combined therapy	12	83.3		81.5	
Other treatments	1	00.0		00.0	

\* Abbreviations: DFS, Disease Free Survival; OS, Overall Survival

**Table 7.** Patient Characteristics and Clinicopathologic Features of anal Canal Cancer in the Literature and the Present Study

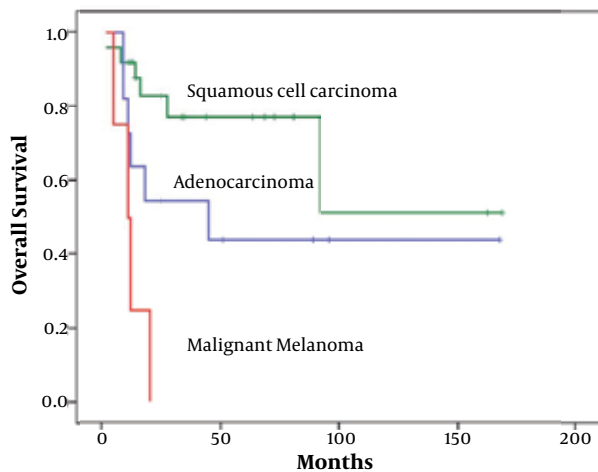
Author	Country	Patients' No.	Median age, y	F/M ratio	Histologic type, %				5y DFS *, %	5y OS *, %
					SCC *	ADC *	MM *	Other		
<b>Jin (21)</b>	Australia	4615	NS	1.3	3216	1276	NS	123	NSa	63.7
<b>Myerson (11)</b>	USA	2339	62.2	1.7	1800	442	NS	97	NS	53.9
<b>Klas (9)</b>	USA	192	58	1.6	143	36	7	6	34	53
<b>Garcia Olmo (22)</b>	Spain	136	-	-	9	117	9	1	NS	NS
<b>Vietharsdottir (15)</b>	Iceland	38	63	2.8	30	1	3	4	NS	75
<b>Devon (23)</b>	Canada	14	49	1.3	3	11	0	0	NS	NS
<b>Present study</b>	Iran	41	57	1.5	25	11	4	1	53	59.4

\* Abbreviations: F/M, female/male; SCC, squamous cell carcinoma; ADC, adenocarcinoma; MM, malignant melanoma; 5y, 5-year; NS, not stated

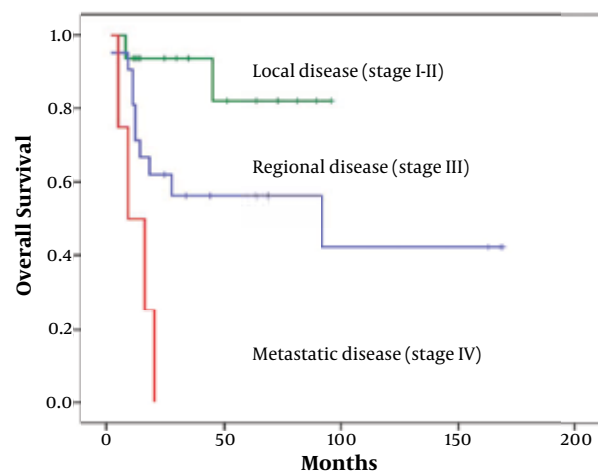
On univariate analysis of prognostic factors for disease free survival, histologic type ( $P < 0.001$ ), stage ( $P < 0.018$ ), and tumor grade ( $P = 0.044$ ) were prognostic factors. In addition, on univariate analysis of prognostic factors for overall survival, histological subtype ( $P = 0.001$ ), and disease stage ( $P = 0.002$ ) were prognostic factors for overall survival (Table 5), (Figures 4 and 5). However, on univariate subgroup analysis of prognostic factors among

patients with squamous cell carcinoma, we found only treatment modality as prognostic factor for overall survival (Table 6).

On multivariate analysis, only disease stage [Hazard ratio (HR) = 8.583, 95% confidence interval (CI) = 2.998-24.576,  $P \leq 0.001$ ] and treatment modality [HR = 3.732, 95% confidence interval (CI) = 1.476-9.433,  $P = 0.005$ ] were independent prognostic factors for overall survival.



**Figure 4.** Kaplan-Meier Survival Analysis of Overall Survival Categorized According to the Histologic type in 41 Patients with Anal Canal Cancer ( $P=0.001$ )



**Figure 5.** Kaplan-Meier survival Analysis of Overall Survival Categorized According to the Disease Stage in 41 Patients with Anal Canal Cancer ( $P=0.002$ )

## 5. Discussion

Malignant neoplasms of the anal canal are relatively rare tumors encompassing a diverse group of malignancies with broad spectrum of biological activity and clinical behavior with many underlying prognostic factors that make them different therapeutic and challenging approaches. There is a considerable difference for patient and the tumor characteristics, stage, treatment, and prognosis among various histologic types of the anal canal cancers.

As found in our study, squamous cell carcinoma, adenocarcinoma and malignant melanoma tend to present in the sixth and seventh decades of life and rarely before the second decade. In almost all reported series in the

literature review, women represent a higher proportion of anal canal malignant neoplasms than men, with a female/male ratio of 1.5 to 3.5. Squamous cell carcinoma and malignant melanoma occur more frequently in women than men; however, anal canal adenocarcinoma is more frequent among men than women (5, 6, 11) (Table 7). In our series, the median age of all patients was 57 years which is consistent with the literature. Likewise, the female/male ratio of all patients, as well as patients with squamous cell carcinoma were comparable to the literature. However, the female/male ratio in patients with adenocarcinoma and malignant melanoma were not consistent with the literature (5, 6, 11).

Malignant neoplasms of the anal canal usually present early and approximately two thirds of patients being diagnosed with stages I and II disease (9, 11-13). This fact is more accurate regarding the histologic types of squamous cell carcinoma and adenocarcinoma rather than malignant melanoma. Malignant melanoma tends to present at locally advanced or metastatic diseases (13, 14). In contrary to the literature, we found most of our patients with anal canal cancer presented with locally advanced disease, and 61% had stage III or IV disease. However, in agreement with most reported series, 50% of our patients with malignant melanoma were stage IV at presentation.

Epithelial tumors, particularly squamous cell carcinoma and adenocarcinoma constitute the vast majority (80-95%) of anal canal neoplasms. Squamous cell carcinoma is the most common histologic type and accounts for 70-85% of all anal canal cancers (9, 11, 15). Squamous cell carcinoma of the anal canal was typically divided into large keratinizing, large nonkeratinizing or transitional carcinoma, and basaloid variant. However, the current classification of the World Health Organization (WHO) suggests that the term of squamous cell carcinoma be used for all histological variants of anal canal squamous cell carcinoma (7, 9, 16). In the present study, epithelial tumors account for 88% and squamous cell carcinoma constitutes 61% of all study population which is consistent with the results of the literature review. Traditionally, squamous cell carcinoma of the anal canal was treated with abdominoperineal resection alone. This surgical technique was associated with considerable morbidity and poor locoregional control of the disease. Sato et al in a literature review found a local recurrence rate varying from 18% to 45% and the 5-year survival rates ranged from 30% to 71% for radical surgery alone (17). Concomitant chemoradiation using 5-Fu and mitomycin is currently considered as the first-line therapy for all but small early stage anal canal squamous cell carcinoma. Abdominoperineal resection should be reserved to salvage the patients with locally persistent or progressive disease. (18). This treatment approach results in complete response rates, more than 90%, and local control rates more than 85% in patients with anal canal squamous cell carcinoma

(19). In the intergroup trial (RTOG 98-11), combined modality therapy resulted in 5-year disease free and overall survival rates of 56% and 69% respectively in patients with anal canal squamous cell carcinoma (20). In our series, the 5-year disease free and overall survival rates of these patients were 72.2% and 77% respectively.

Anal canal adenocarcinoma is less common and accounts for 5-19% of all anal canal cancers. This histologic type of anal canal represents a pathologic and therapeutic challenge. Differentiation of these tumors from rectal adenocarcinoma extending to the anal canal is essential and difficult. It is the main cause of significant different contribution (3-86%) of adenocarcinoma among anal canal cancers in reported series (11, 15, 21-23). In the current study, adenocarcinoma constitutes 27% of all anal canal cancers which is consistent with the large reported series of Myerson et al., and Klas et al. in which adenocarcinoma accounted for 24.5% and 25% of all anal canal cancers respectively (9, 11). However, this portion was 40% in the report of Jin et al., and 86% in the report of Garcia Olmo et al. (21, 22) (Table 7). Surgical resection alone, definitive chemoradiation or combined modality therapy may be considered as treatment options in patients with anal canal adenocarcinoma (7, 24). In our series, most patients with anal canal adenocarcinoma were treated with combined modality therapy.

Primary anal canal melanomas are highly aggressive rare neoplasms accounting for 0-8% of all anal canal tumors in reported series (9, 15, 22, 23). Anal canal malignant melanomas are typically characterized by regional or distant disease at diagnosis. The optimal treatment for this neoplasm remains to be defined. Treatment approach depends on several variables and the treatment goals such as patient's survival and quality of life. Wide local excision or radical surgery is the treatment of choice for patients with localized disease; however, systemic therapy including immunotherapy and targeted therapy should be considered for advanced diseases. Treatment outcome and survival of anal canal melanomas were generally poor after surgery alone, with only 16.8-33% 5-year survival in most reported series (9, 14, 25). In this study, anal canal melanomas accounted for 10% of all patients which is somewhat higher than that of most series. Two patients presented with metastatic disease and two remaining patients with regional disease. In consistent with most reported series in the literature, outcome and survival of our patients with anal canal melanoma was decimal and no patients survived after five years.

Non-epithelial tumors of the anal canal such mesenchymal tumors are very rare. Gastrointestinal stromal tumor of the anal canal is exceedingly rare and accounts for only 3% of all anorectal mesenchymal tumors (26, 27). These neoplasms occur in the submucosal space and intersphincteric plane. They usually present in early stage

and as localized tumor. Primary surgical resection is the standard of care for resectable lesions; however, in unresectable large tumors, neoadjuvant imatinib mesylate, a tyrosine kinase inhibitor can produce significant tumor shrinkage. Most (> 80%) of these neoplasms successfully respond to imatinib (27, 28). Therefore, in patients with large anal canal gastrointestinal stromal tumor, imatinib can convert an abdominoperineal resection to local excision (26, 28). In our series, a patient with large anal canal gastrointestinal stromal tumor was successfully treated with four months neoadjuvant imatinib followed by sphincter conserving surgery.

This study indicates that anal canal region comprises a diverse group of malignant neoplasms with wide range of biological activity and clinical behavior with many underlying prognostic factors that make them different therapeutic and challenging approaches. Squamous cell carcinoma, adenocarcinoma, and malignant melanoma are the most frequent malignant neoplasms in the anal canal. Histologic subtype and disease stage are the most important prognostic factors for overall survival in this region. A multidisciplinary approach is currently recommended for treating most patients with anal canal cancer.

### Acknowledgements

The authors would like to thank the clinical research development of Namazi Hospital for statistical consulting; and the Research Improvement Center of Shiraz University of Medical Sciences, Shiraz, Iran.

### Authors' Contribution

Shapour Omidvari, Sayed Hasan Hamedi, and Samira Razzaghi, involved in conception, design, data collection, writing, revising the manuscript, and approval of final version. Hamid Nasrolahi, Ahmad Mosalaei, Niloufar Ahmadloo, and Mansour Ansari, involved in data collection, literature review, writing the manuscript and approval of final version. Mohammad Mohammadianpanah, involved in conception, design, data collection, data analyzing, interpretation, literature review, writing the manuscript and approval of final version.

### Financial Disclosure

None of the authors has any conflict of interest, financial or otherwise.

### Funding/Support

This study was supported by Shiraz University of Medical Sciences.

### References

1. Wendell-Smith CP. Anorectal nomenclature: fundamental terms

- nology. *Dis Colon Rectum*. 2000;**43**(10):349-58.
2. Siegel R, Naishadham D, Jemal A. Cancer statistics, 2012. *CA Cancer J Clin*. 2012;**62**(1):10-29.
  3. Jemal A, Siegel R, Ward E, Murray T, Xu J, Thun MJ. Cancer statistics, 2007. *CA Cancer J Clin*. 2007;**57**(1):43-66.
  4. Johnson LG, Madeleine MM, Newcomer LM, Schwartz SM, Darling JR. Anal cancer incidence and survival: the surveillance, epidemiology, and end results experience, 1973-2000. *Cancer*. 2004;**101**(2):281-8.
  5. Ortholan C, Resbeut M, Hannoun-Levi JM, Teissier E, Gerard JP, Ronchin P, et al. Anal canal cancer: management of inguinal nodes and benefit of prophylactic inguinal irradiation (CORS-03 Study). *Int J Radiat Oncol Biol Phys*. 2012;**82**(5):1988-95.
  6. Maggard MA, Beanes SR, Ko CY. Anal canal cancer: a population-based reappraisal. *Dis Colon Rectum*. 2003;**46**(11):1517-23.
  7. Shia J. An update on tumors of the anal canal. *Arch Pathol Lab Med*. 2010;**134**(11):1601-11.
  8. Leonard D, Beddy D, Dozois EJ. Neoplasms of anal canal and perianal skin. *Clin Colon Rectal Surg*. 2011;**24**(1):54-63.
  9. Klas JV, Rothenberger DA, Wong WD, Madoff RD. Malignant tumors of the anal canal: the spectrum of disease, treatment, and outcomes. *Cancer*. 1999;**85**(8):1686-93.
  10. Anus. In: Byrd DR, Compton CC, Fritz AG, Greene FL, Trotti A, editors. *American Joint Committee on Cancer, AJCC Cancer Staging Manual*. New York: Springer; 2010. p. 165-173.
  11. Myerson RJ, Karnell LH, Menck HR. The National Cancer Data Base report on carcinoma of the anus. *Cancer*. 1997;**80**(4):805-15.
  12. Tomaszewski JM, Link E, Leong T, Heriot A, Vazquez M, Chander S, et al. Twenty-five-year experience with radical chemoradiation for anal cancer. *Int J Radiat Oncol Biol Phys*. 2012;**83**(2):552-8.
  13. Amirian ES, Fickey PA, Jr, Scheurer ME, Chiao EY. Anal cancer incidence and survival: comparing the greater San-Francisco bay area to other SEER cancer registries. *PLoS One*. 2013;**8**(3).
  14. Belbaraka R, Elharroudi T, Ismaili N, Fetohi M, Tijami F, Jalil A, et al. Management of anorectal melanoma: report of 17 cases and literature review. *J Gastrointest Cancer*. 2012;**43**(1):31-5.
  15. Vietharsdottir H, Moeller PH, Johannsson J, Jonasson JG. [Anal cancer in Iceland 1987-2003. A population based study]. *Laeknabladid*. 2006;**92**(5):365-72.
  16. Salmo E, Haboubi N. Anal cancer: pathology, staging and evidence-based minimum data set. *Colorectal Dis*. 2011;**13** Suppl 1:11-20.
  17. Sato H, Koh PK, Bartolo DC. Management of anal canal cancer. *Dis Colon Rectum*. 2005;**48**(6):1301-15.
  18. Glynne-Jones R, Northover JM, Cervantes A, Esmo Guidelines Working Group. Anal cancer: ESMO Clinical Practice Guidelines for diagnosis, treatment and follow-up. *Ann Oncol*. 2010;**21** Suppl 5:v87-92.
  19. Maurel J, Fernandez-Martos C, Feliu J, Isla D. SEOM clinical guidelines for the treatment of anal cancer. *Clin Transl Oncol*. 2011;**13**(8):525-7.
  20. Ajani JA, Winter KA, Gunderson LL, Pedersen J, Benson AB, 3rd, Thomas CR, Jr, et al. Prognostic factors derived from a prospective database dictate clinical biology of anal cancer: the intergroup trial (RTOG 98-11). *Cancer*. 2010;**116**(17):4007-13.
  21. Jin F, Stein AN, Conway EL, Regan DG, Law M, Brotherton JM, et al. Trends in anal cancer in Australia, 1982-2005. *Vaccine*. 2011;**29**(12):2322-7.
  22. Garcia Olmo D, Pellicer Franco E, Morales Cuenca G, Bermejo Lopez J, Soriano Girona H, Parrilla Paricio P. [Cancer of the anus: incidence and behavior of melanoma in our series]. *Rev Esp Enferm Dig*. 1990;**77**(4):269-73.
  23. Devon KM, Brown CJ, Burnstein M, McLeod RS. Cancer of the anus complicating perianal Crohn's disease. *Dis Colon Rectum*. 2009;**52**(2):211-6.
  24. Belkacemi Y, Berger C, Poortmans P, Piel G, Zouhair A, Meric JB, et al. Management of primary anal canal adenocarcinoma: a large retrospective study from the Rare Cancer Network. *Int J Radiat Oncol Biol Phys*. 2003;**56**(5):1274-83.
  25. Iddings DM, Fleisig AJ, Chen SL, Faries MB, Morton DL. Practice patterns and outcomes for anorectal melanoma in the USA, reviewing three decades of treatment: is more extensive surgical resection beneficial in all patients? *Ann Surg Oncol*. 2010;**17**(1):40-4.
  26. Singhal S, Singhal A, Tugnait R, Varghese V, Tiwari B, Arora PK, et al. Anorectal gastrointestinal stromal tumor: a case report and literature review. *Case Rep Gastrointest Med*. 2013;**2013**:934875.
  27. Nigri GR, Dente M, Valabrega S, Aurello P, D'Angelo F, Montrone G, et al. Gastrointestinal stromal tumor of the anal canal: an unusual presentation. *World J Surg Oncol*. 2007;**5**:20.
  28. Wang JP, Wang T, Huang M, Wang L, Kang L, Wu XJ. The role of neoadjuvant imatinib mesylate therapy in sphincter-preserving procedures for anorectal gastrointestinal stromal tumor. *Am J Clin Oncol*. 2011;**34**(3):314-6.