



Curcumin and Nanocurcumin Oral Supplementation Improve Muscle Healing in a Rat Model of Surgical Muscle Laceration

Siamak Kazemi-Darabadi^{1*}, Ramin Nayebyzadeh¹, Amir Ali Shahbazfar², Faranak Kazemi-Darabadi³, Ezzatollah Fathi¹

¹Department of Clinical Sciences, Faculty of Veterinary Medicine, University of Tabriz, Tabriz, Iran

²Department of Pathobiology, Faculty of Veterinary Medicine, University of Tabriz, Tabriz, Iran

³Emergency Department, Fatemi Hospital, Ardabil University of Medical Sciences, Ardabil, Iran

*Corresponding author: Siamak Kazemi-Darabadi

Address: Department of Clinical Sciences, Faculty of Veterinary Medicine, University of Tabriz, Tabriz, Iran. Tel: + 98- 413-6378743
e-mail: s.kazemi@tabrizu.ac.ir

Received: January 13, 2019

Revised: June 16, 2019

Accepted: June 20, 2019

ABSTRACT

Objective: To compare the effects of curcumin and nanocurcumin oral supplementation on the muscle healing rate of an animal model of surgical muscle laceration.

Methods: Thirty-two male adult rats were randomly divided into sham, control, curcumin, and nanocurcumin groups. Partial transection of the gastrocnemius muscle was made in the right limb of the control and treatment groups. The sham and control groups received normal saline, curcumin group received 500 mg/kg of curcumin and nanocurcumin group received 100 mg curcumin-loaded nanomicelles orally every day. They euthanized two weeks later and the specimens were stained by hematoxylin-eosin (H&E) and Masson's trichrome methods. Aspartate transaminase (AST) and creatine phosphokinase (CPK) were measured in blood samples.

Results: The percentage of collagen fibers in the nanocurcumin group was significantly lesser than the control and curcumin groups ($p < 0.001$). Muscle fiber regeneration in the treatment groups was significantly higher than the control group ($p < 0.001$). The blood vessels of the nanocurcumin group were significantly more than other groups ($p < 0.001$). Plasma AST had a significant difference in the control group compared to the sham and nanocurcumin groups ($p = 0.026$). The plasma CPK level of the control group was also significantly higher than other groups ($p < 0.001$).

Conclusion: In conclusion, although oral curcumin supplementation has little effects because of its poor bioavailability, embedding it in nanoparticles could enhance its systemic effects in promoting the muscle healing process.

Keywords: Muscle laceration; Curcumin; Nano particles; Rat.

Please cite this paper as:

Kazemi-Darabadi S, Nayebyzadeh R, Shahbazfar AA, Kazemi-Darabadi F, Fathi E. Curcumin and Nanocurcumin Oral Supplementation Improve Muscle Healing in a Rat Model of Surgical Muscle Laceration. *Bull Emerg Trauma*. 2019;7(3):292-299. doi: 10.29252/beat-0703013.

Introduction

Skeletal muscle injuries commonly occur during sport practices and often are a treatment

challenge [1]. These injuries are also among the most common injuries experienced during military combat [2]. About 10 to 55% of all sustained injuries during sports are muscle injuries. In shearing type

injuries, including laceration, the muscle fibers, basal lamina, myofibrils, and the nearby capillaries rupture [3]. Lacerated muscle often undergoes degeneration and regeneration process. After necrosis of the muscle fibers and their elimination by macrophages, new fibers are formed within a scaffold of connective tissue. However, the healing process is very slow and the regenerated muscle fibers do not gain their complete functional ability [4]. The impaired healing of traumatic muscle injuries is likely due to a disruption in blood supply and subsequent ischemia and development of fibrosis [5]. Fibrosis which appears during the second week after muscle laceration delays complete recovery [4]. Mature muscle stem cells, inflammatory or perivascular cells, myostatin, and fibroblasts activate myofibroblasts and cause fibrosis [6]. It is reported that over synthesis of transforming growth factor- β (TGF- β) in response to muscle injury is the main cause of fibrosis formation [7].

Current therapies include anti-inflammatory strategies and physical therapy. However, blocking components of the inflammatory response can lead to impaired muscle healing and reduced muscle growth [5]. Although nonsteroidal anti-inflammatory drugs (NSAIDs) reduce inflammation by suppressing prostaglandin production, cyclooxygenase-2 activity is necessary for natural growth of the muscle fibers [8]. So, their short-term use in the acute phase of healing may have some benefits, but they have negative long-term effects [9]. Physical rehabilitation has resulted in little functional improvements and increases in muscle mass associated with the upregulation of markers of fibrosis, but no hypertrophy or hyperplasia of muscle fibers after eight weeks [10]. Treating with growth factors cannot prevent muscle fibrosis development [4]. Use of muscle-derived stem cells, adipose-derived stem cells, human muscle myogenic factor, brain-derived neurotrophic factor, and β -agonists are also practiced to encourage muscle fiber regeneration. Others focused on the application of fibrinolytic agents such as suramin, relaxin, decorin, and gamma interferon which are TGF- β antagonists. However, no reliable formulation exists for the administration of these therapies, alongside their potential adverse effects. For instance, relaxin reduces myofibroblasts proliferation [1, 7].

Fibrinolytic properties of curcumin by expression of urokinase plasminogen activator (uPA) has already been reported [11]. Curcumin has blocked several places in the signaling cascade of TGF- β in renal cells in previous studies [12, 13]. It also had been effective in the treatment of mouth submucosal fibrosis because of its fibrinolytic and anti-inflammatory properties [14]. Another study concluded that curcumin can reduce oxidative stress and inflammatory response in gastrocnemius muscle overuse injury of mice through suppression of hydrogen peroxide and NADPH-oxidase expression

in muscles [15]. In addition, the protective effects of curcumin against muscle ischemia-reperfusion injury through free radical's elimination has been reported [16]. It has been shown that muscle fibers regeneration accelerates by intraperitoneal injection of curcumin [17].

Considering fibrinolytic, anti-inflammatory, and free radicals scavenging properties of the curcumin, we assumed in this study that its oral supplementation may reduce scar tissue formation and promote muscle fiber regeneration during the healing process of lacerated muscle. Since the majority of oral curcumin eliminates by feces, several methods are used to increase its bioavailability such as piperine adjoin, liposomal curcumin formulating, curcumin nanoparticles, and curcumin phospholipid complexes [18]. In this regard, curcumin-loaded nanomicelles were also used in this study to compare its effects with curcumin.

Materials and Methods

Animals

Thirty-two male adult (8 weeks old) Sprague-Dawley rats weighing 200-250 g were used in this study. They were kept in separate cages a week before surgery for acclimatizing. Environmental conditions were set in 22° C and 12 h light/darkness cycles. The rats had free access to semisynthetic pellets 24 h, and tap water 12 h before surgery. All procedures were in accordance with WMA statement on animal use in biomedical research (adopted by the 41st World Medical Assembly, Hong Kong, September 1989) and ethical standards recommended by the Helsinki Declaration and any unnecessary stimulating of the animals were avoided.

Surgery and Treatments

A single dose of gentamicin 5% (80 mg/kg, Nasr Pharmaceutical Co., Iran) was injected intraperitoneally to all animals one day before surgery. They were randomly divided into four equal groups, including sham, control, curcumin, and nanocurcumin. The rats were anesthetized by intraperitoneal injection of ketamine 10% (100 mg/kg, Alfasan, Woerden, the Netherlands) and xylazine 2% (20 mg/kg, Alfasan, Woerden, the Netherlands) combination. The hairs of right hind limb in the crus region were shaved and the area was prepared aseptically. Muscle laceration was made by routine procedure [19]. Briefly, the skin of the laterocaudal aspect of the crus was incised longitudinally and retracted. Subcutaneous dissection was continued until exposure of the gastrocnemius muscle. The surgery was ended at this time in the sham group and the skin and subcutaneous tissues were closed. In the next three groups, proper location for laceration was determined and a partial transection of the muscle was made by a scalpel blade about 2.5 cm proximal to the calcaneus, while the tarsus was flexed in 90° angle

and the stifle was extended (Figure 1). The laceration had about 1 cm width (75% of muscle width) and 0.3 cm depth (50% of muscle thickness) and was made lateral to the vessel-nervous bundle (popliteal artery and tibialis nerve). The subcutaneous tissue was closed using 4-0 polyglycolic acid suture material (Dexon II, USS DG) and the skin was closed by 4-0 polyamide suture material (Monofil Polyamide, SUPA, Iran) in a simple continuous pattern. One dose of intramuscular ketoprofen 10% (3 mg/kg, Nasr Pharmaceutical Co., Iran) was injected post-surgery to control pain.

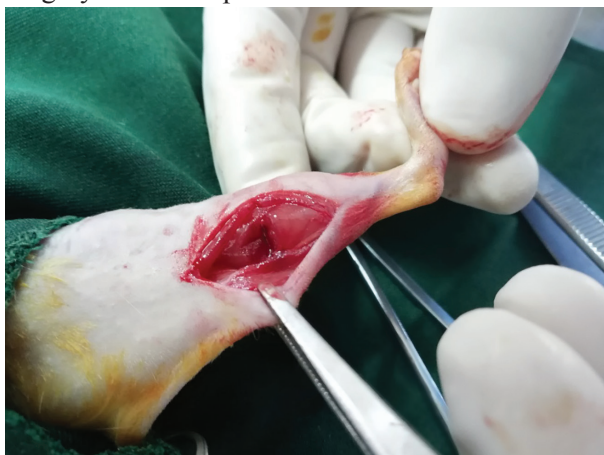

Fig. 1. Partial transection of the rat's right gastrocnemius muscle about 2.5 cm proximal to the calcaneus, while the tarsus was flexed in 90° angle and the stifle was extended.

The rats of sham and control groups received daily oral gavage of normal saline, after surgery. Curcumin group received daily oral gavage of 500 mg/kg curcumin (Merck, Darmstadt, Germany) [20, 21] and nanocurcumin group received daily oral gavage of 100 mg/kg commercially available curcumin-loaded nanomicelles (SinaCurcumin, Exir Nano Sina, Tehran, Iran). The nanomicelles were mixed with normal saline to obtain 15 mg/ml concentration [15]. The transmission electron microscope (TEM) images of nanoparticles were obtained (LEO 200, Germany) operating at 80 KV accelerating voltage. The nanoparticles were also characterized with Fourier-transform infrared (FTIR) spectroscopy in the wave number range of 400-4000 cm^{-1} and wave number accuracy of 1.0 cm^{-1} (Tensor 27, Bruker, Germany).

Biopsy and Histopathologic Evaluation

Two-week period was considered for oral supplementation and muscle healing [4]. After that, the rats were anesthetized by intraperitoneal injection of ketamine 10% and xylazine 2% combination and biopsy was taken from right gastrocnemius muscle. They euthanized by intracardiac overdose injection of sodium thiopental (VUAB Pharma Inc., Czech Republic) after the biopsy. The specimens were fixed in 10% buffered formalin solution and 5 μm thick sections were made by a microtome. The slides were stained with hematoxylin-eosin (H&E) and

Masson's trichrome methods. Muscle regeneration within the injured site was evaluated in H&E stained slides. The total number of regenerating myofibers was measured in 5 random fields of each slide [7, 22]. Extramuscular connective tissue was avoided. In addition, blood vessels percentage within the healed area was calculated. Collagen accumulation which indicates fibrosis was evaluated in Masson's trichrome stained sections and was presented as the percentage of the blue area in the field. Muscle fibers are red, nuclei are black, and collagen is blue in this staining [10].

Biochemical Evaluations

Just before euthanizing, 1 ml of blood was taken from the left cardiac ventricle of each animal and transferred into heparinized microtubes. The samples were centrifuged and the blood plasma was extracted. Aspartate transaminase (AST) and creatine phosphokinase (CPK) were measured using GOT/AST and CK-NAC liquid test enzymatic assay kits (Pars Azmun, Karaj, Iran) and a spectrophotometer as per manufacturer's instructions.

Statistical Analysis

The histopathologic results are presented as mean and the biochemical results as mean \pm standard deviation (SD). SPSS software (BM SPSS Statistics for Windows, Version 22, Armonk, NY: IBM Corp.) was used and one-way analysis of variance (ANOVA) was chosen for statistical analysis followed by Tukey's post hoc test. Statistical significance was defined as two-sided p-value of less than 0.05.

Results

Nanoparticles Characterization

TEM image of the curcumin-loaded nanomicelles confirmed their nanoscale and revealed that particle size was less than 50 nm (Figure 2). The FTIR spectrum of nanomicelles showed various absorption bands indicating presence of curcumin (Figure 3).



Fig. 2. Transmission electron microscopy (TEM) image of the content of the curcumin-loaded nanomicelles shows the particles are less than 50nm in diameter.

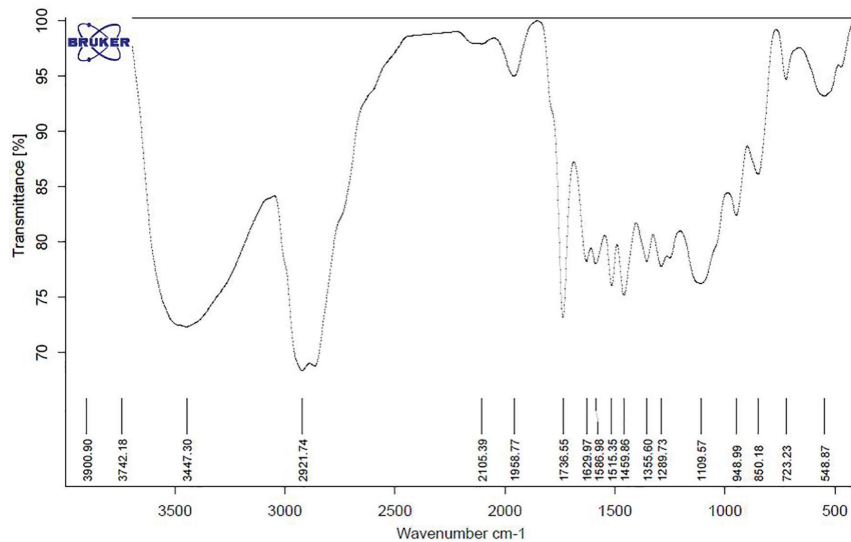


Fig. 3. Fourier-transform infrared (FTIR) spectrum of the curcumin-loaded nanomicelles.

Histopathologic Findings

Fibroblasts and fibrocytes were abundant in the healed area of the control group and some blood vessels were seen. Connective tissue containing collagen fibers was formed in an irregular pattern. The same was seen in the curcumin group, except that collagen fibers were more regular. Fibroblasts and fibrocytes in the nanocurcumin group were less than two previous groups and the muscle fibers had better healing. Ground substance of the connective tissue was less than the control and curcumin groups. The collagen fibers were more regular, comparable to the normal muscle of the sham group (Figures 4 and 5). The percentage of collagen fibers in the nanocurcumin

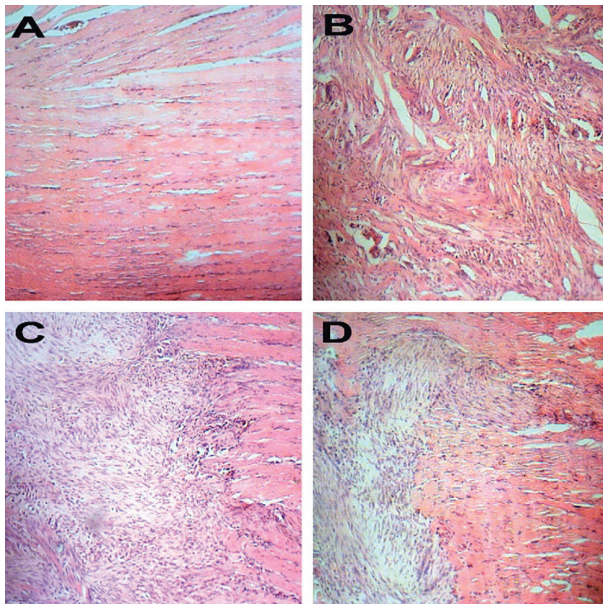


Fig. 4. Healed areas of the gastrocnemius muscle in experimental groups. A: Sham group. Normal muscle fibers. B: Negative control group. Abundant fibroblasts and fibrocytes along with irregular connective tissue containing collagen fibers. C: Curcumin group. Similar to the control group except that collagen fibers are more regular. D: Nanocurcumin group. Fibroblasts and fibrocytes are less than control and curcumin groups and the muscle fibers have better healing. (H&E, $\times 200$).

group was significantly lesser than the control and curcumin groups and was closer to the sham group ($p < 0.001$). In addition, muscle fiber regeneration in the treatment groups was significantly higher than the control group, which those of nanocurcumin group was better ($p = 0.000$). Finally, the blood vessels of the nanocurcumin group were significantly ($p = 0.000$) more than three other groups (Figure 6).

Biochemical Findings

The results of plasma AST and CPK levels are presented in Figures 7 and 8. Plasma AST had a significant difference in the control group compared to the sham and nanocurcumin groups ($p = 0.026$). The nanocurcumin group had not any significant difference with the sham and curcumin groups. The plasma

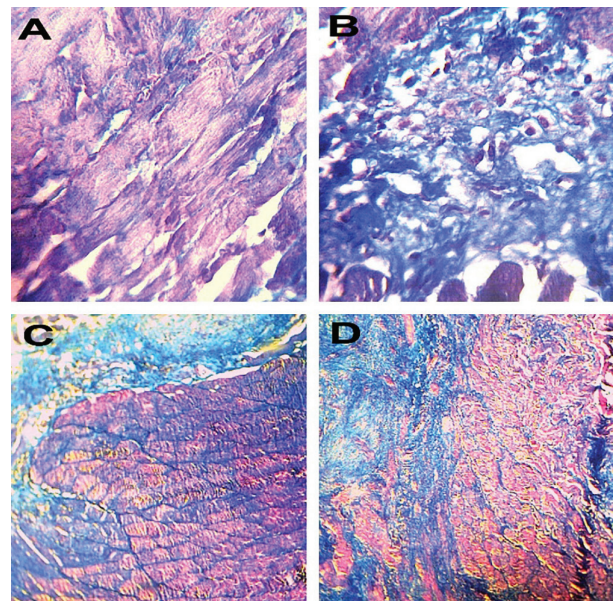


Fig. 5. Healed areas of the gastrocnemius muscle in experimental groups. Muscle fibers are seen in red and collagen is seen blue (Masson's trichrome). A: Sham group, B: Negative control group, C: Curcumin group, D: Nanocurcumin group, A and B: $\times 800$, C and D: $\times 200$

CPK level of the control group was also significantly higher than other groups ($p < 0.001$). Similarly, the nanocurcumin group had not any significant difference with the sham and curcumin groups.

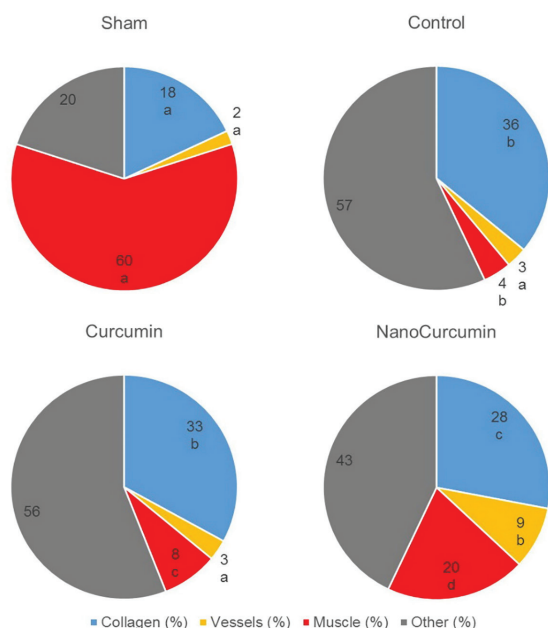


Fig. 6. Percentage of collagen, muscle fibers, and blood vessels in the healed area of the lacerated gastrocnemius muscle in experimental groups. Different letters (a, b, c, d) indicate significant difference among the groups ($p < 0.05$).

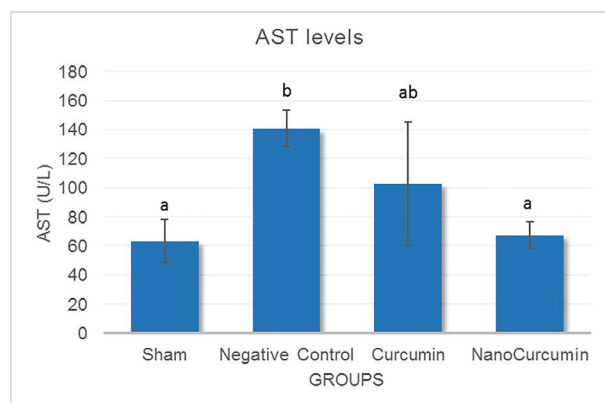


Fig. 7. Blood AST levels (U/L) in the experimental groups two weeks after muscle injury (mean \pm SD). Different letters (a, b) indicate significant difference ($p < 0.05$).

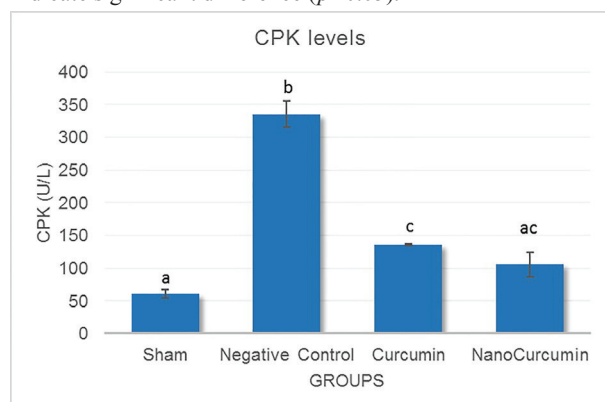


Fig. 8. Blood CPK levels (U/L) in the experimental groups two weeks after muscle injury (mean \pm SD). Different letters (a, b, c) indicate significant difference ($p < 0.05$).

Discussion

The current study compared the effects of orally administered curcumin and curcumin nanoparticles in the healing of lacerated muscle. The results of the present study demonstrated that this substance is effective in muscle fiber regeneration and fibrosis reduction, which are important for regaining normal muscle function, and its effects are augmented when used in nano form, because of enhanced oral bioavailability.

Curcumin (1,7-bis(4-hydroxy-3-methoxyphenyl)-1,6-heptadiene-3,5-dione) is a phenolic compound derived from spice herb *Curcuma longa* L. [21]. Preclinical safety studies by the US National Cancer Institute did not find any adverse effects at doses of 3.5 g/kg in rats receiving curcumin for 3 months [23]. Oral bioavailability of curcumin is about 1% [21]. The majority of the oral curcumin is excreted in the feces and about one-third of its total dose can be detectable unchanged. Efficient first-pass and some degree of intestinal metabolism of curcumin, mainly glucuronidation and sulfation, may be the cause of its poor systemic availability when orally administered [24]. Various methods have been used to increase curcumin solubility and oral bioavailability. Conjugation with phospholipids, proteins, or polysaccharides improve its solubility [25, 26]. Adjuvant molecules such as piperine, quercetin, or silibinin enhance the oral absorption of curcumin by inhibiting metabolic conjugation [27]. However, curcumin could be rapidly degraded in the majority of these cases [28]. Cheng *et al.*, [29] reported a low dose of curcumin encapsulated in polyethylene glycol- polylactic acid nanoparticles increases the mean concentration of curcumin in plasma during 10 minutes. However, it then quickly diminished after 40 min. Szymusiak *et al.*, [28] investigated the bioavailability of curcumin in blood plasma and CNS after oral intake of nanocurcumin and curcumin in mice. Their results showed that oral nanocurcumin at the dose of 1/20 of the unformulated curcumin can provide similar concentrations in CNS tissues. Bioavailability of curcumin nanoparticles was 5% in another study [30]. So, the dose of 100 mg/kg was chosen in our research. Commercially available curcumin nanomicelles used in this study has approximately 100% of curcumin encapsulation in the nanomicelle, and the sizes are less than 50 nm [31]. These nanomicelles are prepared from generally recognized as safe (GRAS) pharmaceutical excipients and C3-complex form of curcumin and have a significantly higher bioavailability after oral use, because of its water-solubility [32].

FTIR analysis confirmed the curcumin incorporation in nanoparticles. The functional groups of the curcumin including hydroxyl, carbonyl, and ethylene groups show peaks at 3509, 1600-1650, and 1510 cm^{-1} , respectively [33]. We observed the peaks corresponding to these functional groups

for the curcumin-loaded nanomicelles at 3447, 1629, and 1515 cm^{-1} respectively, indicating that the major peaks of curcumin were retained in the product. The peaks at 725, 817, and 967 cm^{-1} in the curcumin spectrum indicate the bending vibrations of -CH bond of alkene group [33]. These peaks were observed in the curcumin nanomicelles at 723, 850, and 948 cm^{-1} .

AST is a marker of both hepatic, cardiac, and skeletal muscle damage. It is one of the most important enzymes of the aminotransferase group, which catalyzes the alpha-keto acid into amino acids by transferring amine units. Similarly, plasma CPK is a serological marker of skeletal muscle injury arising from myofibrillar disruption [34, 35]. Oral curcumin supplementation has reduced plasma CPK concentrations during recovery from exercise-induced muscle damage [36]. Our findings revealed that AST and CPK levels were significantly increased in the control group indicating severe muscle damage. The results showed these biomarkers in the treatment groups compared to the control are decreased, which could tell us that oral curcumin supplementation has alleviated the muscle damage and that nanocurcumin supplementation exerts this effect better than curcumin.

Curcumin possesses numerous pharmacological activities such as anti-inflammatory, anti-cancer, anti-oxidant, wound healing and anti-microbial effects [13]. Interestingly, anti-fibrosis effect of curcumin has been studied in various organs. Curcumin reduces adipose fibrosis by preventing low oxygen tension and suppressing the mammalian target of rapamycin (mTOR) activation [37]. It also inhibited hepatic fibrosis by demethylation of key genes [38]. It is reported that curcumin attenuates the inflammation and fibrotic changes in the idiopathic pulmonary fibrosis models by inhibiting the nuclear factor- κ B (NF- κ B)-mediated inflammation and TGF- β 1-mediated fibrotic lung remodeling [39]. We find that nanocurcumin can decrease fibroblast proliferation and collagen formation. This is not unexpected because curcumin can induce fibroblast apoptosis. Madhyastha *et al.*, [11] reported that curcumin enhances fibrinolysis during wound healing by upregulating the serine protease uPA via the activation of the c-Jun N-terminal kinase (JNK) and p38 mitogen-activated protein kinase (MAPK) signal pathways. uPA is amongst the earliest mediators of the fibrinolysis cascade and has a critical role in fibrin dissolution. Our results

also demonstrated an increase in neovascularization by nanocurcumin. It is reported that curcumin enhances wound healing by increasing granulation tissue formation, neovascularization, and faster reepithelialization [40].

Mechanisms for the anti-inflammatory effects of curcumin include inhibition of NF- κ B activity, activation of the heat-shock response, inhibition of p38 kinase activity and oxygen free radical formation, and prevention of cytokine production and release [41]. Oral administration of curcumin has attenuated skeletal muscle mitochondrial impairment in chronic obstructive pulmonary disease rats [42]. In the repair phase of the muscle healing, the regenerating myofibers replace the necrotized area of the ruptured myofiber inside the remaining basal lamina within 5-6 days. Afterward, the newly formed muscle fibers begin to penetrate into the scar tissue [3]. Our findings showed that the myofiber regeneration in the curcumin and nanocurcumin groups is significantly improved compared to the control group. Myogenesis is a highly regulated process that involves differentiation of multipotential mesodermal cells to myoblasts and muscle fibers. NF- κ B is a very important signaling system which its activation leads to skeletal muscle loss [43]. Pan *et al.*, [34] showed that curcumin relieves muscular dystrophy and improves muscle contraction function in *mdx* mice. They found abnormally high levels of tumor necrosis factor alpha (TNF- α), interleukin 1 beta (IL-1 β), and Inducible nitric oxide synthase (iNOS) in *mdx* mice –which inhibit myogenesis- and these were reduced by administration of curcumin. Curcumin is a pharmacological inhibitor of the NF- κ B and greatly enhances the murine muscle regeneration. It has been found that muscle-specific inhibition of NF- κ B improves skeletal muscle regeneration [17].

In conclusion, although oral curcumin supplementation has little effects because of its poor bioavailability, embedding it with nanoparticles could enhance its systemic effects in promoting the muscle healing process.

Acknowledgment

The authors would like to appreciate Faculty of Veterinary Medicine, University of Tabriz for providing facilities to perform this research.

Conflicts of Interest: None declared.

References

1. Danna NR, Beutel BG, Campbell KA, Bosco JA 3rd. Therapeutic approaches to skeletal muscle repair and healing. *Sports Health*. 2014;6(4):348-55.
2. Covey DC. Combat orthopaedics: a view from the trenches. *J Am Acad Orthop Surg*. 2006;14(10 Spec No.):S10-7.
3. Järvinen TA, Järvinen M, Kalimo H. Regeneration of injured skeletal muscle after the injury. *Muscles Ligaments Tendons J*. 2014;3(4):337-45.
4. Fukushima K, Badlani N, Usas A, Riano F, Fu F, Huard J. The use of an antifibrosis agent to improve muscle recovery after laceration. *Am J Sports Med*. 2001;29(4):394-402.
5. Shen W, Li Y, Tang Y, Cummins J, Huard J. NS-398, a cyclooxygenase-2-specific inhibitor, delays skeletal

- muscle healing by decreasing regeneration and promoting fibrosis. *Am J Pathol.* 2005;**167**(4):1105-17.
6. Lieber RL, Ward SR. Cellular mechanisms of tissue fibrosis. 4. Structural and functional consequences of skeletal muscle fibrosis. *Am J Physiol Cell Physiol.* 2013;**305**(3):C241-52.
 7. Chan YS, Li Y, Foster W, Fu FH, Huard J. The use of suramin, an antifibrotic agent, to improve muscle recovery after strain injury. *Am J Sports Med.* 2005;**33**(1):43-51.
 8. Bondesen BA, Mills ST, Kegley KM, Pavlath GK. The COX-2 pathway is essential during early stages of skeletal muscle regeneration. *Am J Physiol Cell Physiol.* 2004;**287**(2):C475-83.
 9. Mackey AL, Mikkelsen UR, Magnusson SP, Kjaer M. Rehabilitation of muscle after injury - the role of anti-inflammatory drugs. *Scand J Med Sci Sports.* 2012;**22**(4):e8-14.
 10. Corbiere TF, Weinheimer-Haus EM, Judex S, Koh TJ. Low-Intensity Vibration Improves Muscle Healing in a Mouse Model of Laceration Injury. *J Funct Morphol Kinesiol.* 2018;**3**(1). pii: 1.
 11. Madhyastha R, Madhyastha H, Nakajima Y, Omura S, Maruyama M. Curcumin facilitates fibrinolysis and cellular migration during wound healing by modulating urokinase plasminogen activator expression. *Pathophysiol Haemost Thromb.* 2010;**37**(2-4):59-66.
 12. Gaedeke J, Noble NA, Border WA. Curcumin blocks multiple sites of the TGF-beta signaling cascade in renal cells. *Kidney Int.* 2004;**66**(1):112-20.
 13. Maheshwari RK, Singh AK, Gaddipati J, Srimal RC. Multiple biological activities of curcumin: a short review. *Life Sci.* 2006;**78**(18):2081-7.
 14. Srivastava A, Agarwal R, Chaturvedi TP, Chandra A, Singh OP. Clinical evaluation of the role of tulsi and turmeric in the management of oral submucous fibrosis: A pilot, prospective observational study. *J Ayurveda Integr Med.* 2015;**6**(1):45-9.
 15. Kawanishi N, Kato K, Takahashi M, Mizokami T, Otsuka Y, Imaizumi A, et al. Curcumin attenuates oxidative stress following downhill running-induced muscle damage. *Biochem Biophys Res Commun.* 2013;**441**(3):573-8.
 16. Avci G, Kadioglu H, Sehirli AO, Bozkurt S, Guclu O, Arslan E, et al. Curcumin protects against ischemia/reperfusion injury in rat skeletal muscle. *J Surg Res.* 2012;**172**(1):e39-46.
 17. Thaloor D, Miller KJ, Gephart J, Mitchell PO, Pavlath GK. Systemic administration of the NF-kappaB inhibitor curcumin stimulates muscle regeneration after traumatic injury. *Am J Physiol.* 1999;**277**(2):C320-9.
 18. Lopresti AL. The Problem of Curcumin and Its Bioavailability: Could Its Gastrointestinal Influence Contribute to Its Overall Health-Enhancing Effects? *Adv Nutr.* 2018;**9**(1):41-50.
 19. Piedade MC, Galhardo MS, Battlehner CN, Ferreira MA, Caldini EG, de Toledo OM. Effect of ultrasound therapy on the repair of gastrocnemius muscle injury in rats. *Ultrasonics.* 2008;**48**(5):403-11.
 20. Nonose N, Pereira JA, Machado PR, Rodrigues MR, Sato DT, Martinez CA. Oral administration of curcumin (*Curcuma longa*) can attenuate the neutrophil inflammatory response in zymosan-induced arthritis in rats. *Acta Cir Bras.* 2014;**29**(11):727-34.
 21. Yang KY, Lin LC, Tseng TY, Wang SC, Tsai TH. Oral bioavailability of curcumin in rat and the herbal analysis from *Curcuma longa* by LC-MS/MS. *J Chromatogr B Analyt Technol Biomed Life Sci.* 2007;**853**(1-2):183-9.
 22. Terada S, Ota S, Kobayashi M, Kobayashi T, Mifune Y, Takayama K, et al. Use of an antifibrotic agent improves the effect of platelet-rich plasma on muscle healing after injury. *J Bone Joint Surg Am.* 2013;**95**(11):980-8.
 23. Clinical development plan: curcumin. *J Cell Biochem Suppl.* 1996;**26**:72-85.
 24. Sharma RA, Steward WP, Gescher AJ. Pharmacokinetics and pharmacodynamics of curcumin. The molecular targets and therapeutic uses of curcumin in health and disease: Springer; 2007. p. 453-70.
 25. Liu A, Lou H, Zhao L, Fan P. Validated LC/MS/MS assay for curcumin and tetrahydrocurcumin in rat plasma and application to pharmacokinetic study of phospholipid complex of curcumin. *J Pharm Biomed Anal.* 2006;**40**(3):720-7.
 26. Tapal A, Tiku PK. Complexation of curcumin with soy protein isolate and its implications on solubility and stability of curcumin. *Food Chemistry.* 2012;**130**(4):960-5.
 27. Grill AE, Koniar B, Panyam J. Co-delivery of natural metabolic inhibitors in a self-microemulsifying drug delivery system for improved oral bioavailability of curcumin. *Drug Deliv Transl Res.* 2014;**4**(4):344-52.
 28. Szymusiak M, Hu X, Leon Plata PA, Ciupinski P, Wang ZJ, Liu Y. Bioavailability of curcumin and curcumin glucuronide in the central nervous system of mice after oral delivery of nano-curcumin. *Int J Pharm.* 2016;**511**(1):415-423.
 29. Cheng KK, Yeung CF, Ho SW, Chow SF, Chow AH, Baum L. Highly stabilized curcumin nanoparticles tested in an in vitro blood-brain barrier model and in Alzheimer's disease Tg2576 mice. *AAPS J.* 2013;**15**(2):324-36.
 30. Tsai YM, Jan WC, Chien CF, Lee WC, Lin LC, Tsai TH. Optimised nano-formulation on the bioavailability of hydrophobic polyphenol, curcumin, in freely-moving rats. *Food Chem.* 2011;**127**(3):918-25.
 31. Saadipoor A, Razzaghdoust A, Simforoosh N, Mahdavi A, Bakhshandeh M, Moghadam M, et al. Randomized, double-blind, placebo-controlled phase II trial of nanocurcumin in prostate cancer patients undergoing radiotherapy. *Phytother Res.* 2019;**33**(2):370-378.
 32. Rahimi HR, Nedaeinia R, Sepehri Shamloo A, Nikdoust S, Kazemi Oskuee R. Novel delivery system for natural products: Nano-curcumin formulations. *Avicenna J Phytomed.* 2016;**6**(4):383-98.
 33. Athira GK, Jyothi AN. Preparation and characterization of curcumin loaded cassava starch nanoparticles with improved cellular absorption. *International Journal of Pharmacy and Pharmaceutical Sciences.* 2014;**6**(10):171-6.
 34. Pan Y, Chen C, Shen Y, Zhu CH, Wang G, Wang XC, et al. Curcumin alleviates dystrophic muscle pathology in mdx mice. *Mol Cells.* 2008;**25**(4):531-7.
 35. Kim HJ, Lee YH, Kim CK. Biomarkers of muscle and cartilage damage and inflammation during a 200 km run. *Eur J Appl Physiol.* 2007;**99**(4):443-7.
 36. McFarlin BK, Venable AS, Henning AL, Sampson JN, Pennel K, Vingren JL, et al. Reduced inflammatory and muscle damage biomarkers following oral supplementation with bioavailable curcumin. *BBA Clin.* 2016;**5**:72-8.
 37. Qiu Z, Zhang S, Li A, Yu J, Li N, Huang F, et al. The role of curcumin in disruption of HIF-1 α accumulation to alleviate adipose fibrosis via AMPK-mediated mTOR pathway in high-fat diet fed mice. *J Funct Foods.* 2017;**33**:155-65.
 38. Wu P, Huang R, Xiong YL, Wu C. Protective effects of curcumin against liver fibrosis through modulating DNA methylation. *Chin J Nat Med.* 2016;**14**(4):255-264.

39. Hu Y, Li M, Zhang M, Jin Y. Inhalation treatment of idiopathic pulmonary fibrosis with curcumin large porous microparticles. *Int J Pharm.* 2018;**551**(1-2):212-222.
40. Sidhu GS, Singh AK, Thaloor D, Banaudha KK, Patnaik GK, Srimal RC, et al. Enhancement of wound healing by curcumin in animals. *Wound Repair Regen.* 1998;**6**(2):167-77.
41. Alamdari N, O'Neal P, Hasselgren PO. Curcumin and muscle wasting: a new role for an old drug? *Nutrition.* 2009;**25**(2):125-9.
42. Zhang M, Tang J, Li Y, Xie Y, Shan H, Chen M, et al. Curcumin attenuates skeletal muscle mitochondrial impairment in COPD rats: PGC-1 α /SIRT3 pathway involved. *Chem Biol Interact.* 2017;**277**:168-175.
43. Li H, Malhotra S, Kumar A. Nuclear factor-kappa B signaling in skeletal muscle atrophy. *J Mol Med (Berl).* 2008;**86**(10):1113-26.

Open Access License

All articles published by Bulletin of Emergency And Trauma are fully open access: immediately freely available to read, download and share. Bulletin of Emergency And Trauma articles are published under a Creative Commons license (CC-BY-NC).