



## Acute Subdural Hemorrhage of a Convexity Meningioma in the Postpartum Period; Case Report and Literature Review

Mohammad Sadegh Masoudi<sup>1,2</sup>, Saber Zafarshampour<sup>1\*</sup>, Mohammad Ghasemi-Rad<sup>3</sup>, Neda Soleimani<sup>4</sup>, Abbas Rakhsha<sup>1</sup>, Christie Lincoln<sup>3</sup>

<sup>1</sup>Department of Neurosurgery, Shiraz University of Medical Sciences, Shiraz, Iran

<sup>2</sup>Neurotrauma Research Center, AJA University of Medical Sciences, Tehran, Iran

<sup>3</sup>Department of Radiology, Baylor college of medicine, Houston, Texas, USA

<sup>4</sup>Department of Pathology, Shiraz University of Medical Sciences, Shiraz, Iran

\*Corresponding author: Saber Zafar Shampour

Address: Resident of Neurosurgery, Neurosurgery Office, Nemzee Hospital, Neamazee Square, Shiraz, Iran. Tel: +98-914-1467267; Fax: +98-713-6474259  
e-mail: saberzsp@gmail.com

Received: February 11, 2019

Revised: March 12, 2019

Accepted: March 23, 2019

### ► ABSTRACT

New onset seizures in pregnancy or the postpartum period can be of great importance and denote various underlying pathologies. Eclampsia and cerebrovascular accidents are common, and brain tumors are uncommon causes of postpartum seizures among others. Acute presentation of brain tumors in pregnancy or the postpartum period is extremely rare. Meningiomas are the most common benign intracranial tumors. Although 1.3 to 2.4% of these benign tumors may bleed, acute presentation of them with hemorrhage is quite rare. Herein, we report a rare case of a 36-year-old lady who presented with severe headache, seizure, and loss of consciousness in the postpartum period, five days after delivery of a full-term baby. Primary emergency evaluation revealed an extra-axial lesion with subdural hemorrhage. A Decompressive craniectomy was performed, hematoma was evacuated, and the tumor was totally resected. Histopathologic evaluation was consistent with a fibroblastic meningioma (WHO grade I). She was discharged in good general condition. Our case highlights the significance of complete evaluation of patients with new-onset seizures in pregnancy or the postpartum period. Although uncommon, brain tumors in pregnancy can have potentially devastating outcomes which may necessitate prompt surgical intervention.

**Keywords:** Convexity meningioma; Pregnancy; Brain neoplasm; Hemorrhage; Seizure.

Please cite this paper as:

Masoudi MS, Zafarshampour S, Ghasemi-Rad M, Soleimani N, Rakhsha A, Lincoln C. Acute Subdural Hemorrhage of a Convexity Meningioma in the Postpartum Period; Case Report and Literature Review. *Bull Emerg Trauma*. 2019;7(3):324-329. doi: 10.29252/beat-0703018.

### Introduction

Brain tumors infrequently occur during pregnancy, and their acute presentation in pregnancy or in the postpartum period is very rare [1, 2] Meningiomas are the most common benign brain tumors that usually present between 40-60 years old.

These tumors are twice as common in women. The growth of meningioma seems to be related to sex hormones, therefore, their growth increases during pregnancy. Approximately 10% of patients present with symptoms such as headache, dizziness, seizures, and focal neurological deficits depending on their location and size and if there is associated mass

effect or herniation. In pregnant women, symptoms such as headache, dizziness may be misdiagnosed as hyperemesis gravidarum. Seizure is a late symptom which is related to mass effect [3]. Approximately 1.3 to 2.4% of these benign tumors may bleed, but, acute presentation of these tumors with hemorrhage is uncommon and subdural hematoma is even rare [1, 4].

Although eclampsia is the most likely diagnosis for a new-onset seizure in pregnancy or the postpartum period, less common etiologies such as brain tumors and infections should also be considered [5, 6]. Herein, we report a rare case of a 36-year-old lady who presented with a severe headache, seizure, and loss of consciousness in the postpartum period, five days after delivery of a full-term baby.

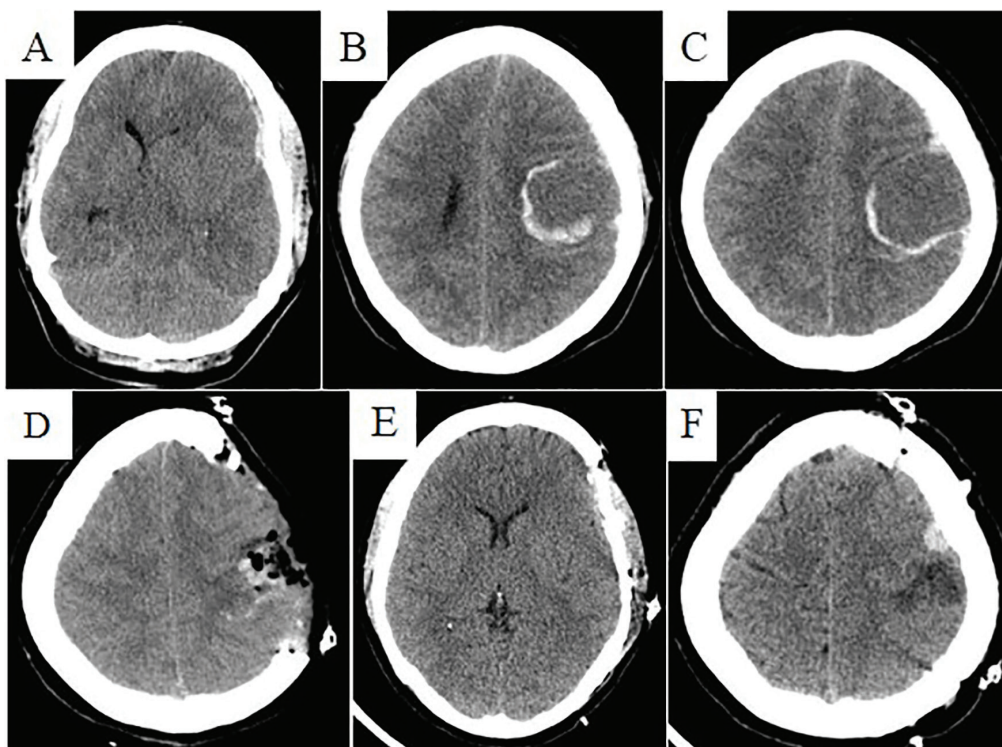
### Case Report

A 36-year-old pregnant lady (full-term, Gravidity 3, Parity 2, Live 2) with a history of trivial right hand weakness since 5 months ago, which had been neglected and attributed to common pregnancy issues was admitted for delivery. Her pregnancy had been uneventful in general without any significant medical or surgical issues. Her past medical and family histories were unremarkable except for two previous cesarean deliveries at her request without any medical indications. Her physical examination on admission was unremarkable except for right hand weakness of little importance. She denied any recent head trauma. Her lab results were all within normal limits. A cesarean section was performed for her

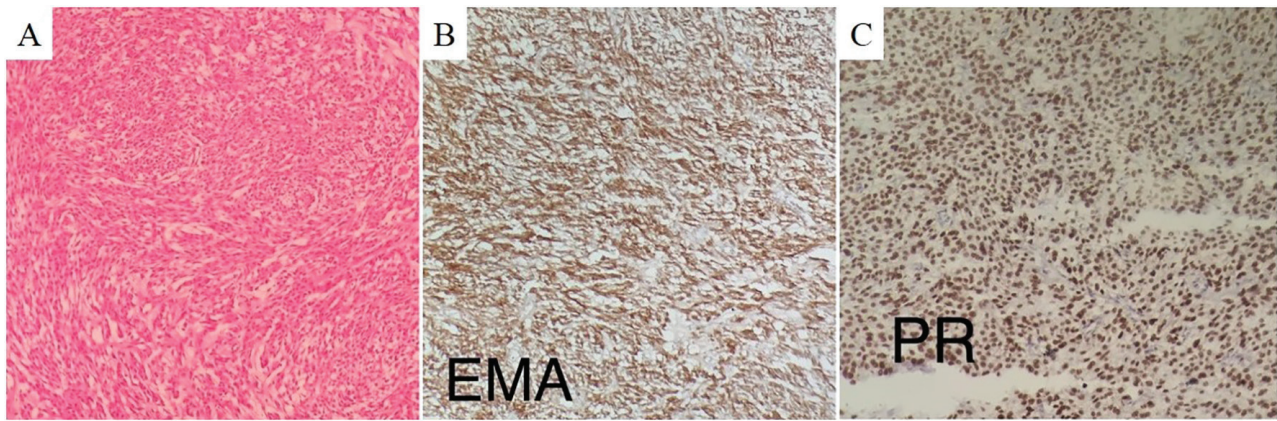
without complication. She and her baby were in good conditions. Five days later, she suddenly developed a severe headache, right side weakness, two episodes of seizures and acute loss of consciousness (GCS: 3/15, Pupils: Both fixed and dilated). She was rapidly intubated and airway was secured, her blood sugar was checked, anticonvulsant prophylaxis was initiated, and was stabilized. An urgent brain computerized tomography (CT) scan was requested for her which revealed a left frontoparietal subdural hematoma, a suspicious left high parietal lesion with evidence of peripheral hemorrhage, and brain edema with significant midline shift (Figure 1, A-C).

She was urgently taken to the operating room for both hematoma evacuation and decompressive craniectomy. A left traumatic incision was made, and a left frontotemporoparietal decompressive craniectomy was performed. When dura was opened, acute subdural hematoma and an extra-axial lesion in the parietal region with evidence of bleeding, in favor of a meningioma, were identified, subdural hematoma was evacuated, and the tumor was totally resected. Bone flap was preserved in the bone bank for future cranioplasty (Figure 1, D).

Histopathological examination of the hematoxylin and eosin stained specimen revealed spindle cells with indistinct cell boundaries arranged in intersecting fascicles without any mitosis and necrosis, consistent with fibroblastic meningioma (WHO grade I). The cells were strongly positive for epithelial membrane antigen (EMA) and progesterone receptor (PR) (Figure 2).



**Fig. 1.** Preoperative noncontrast computerized tomography (CT) scan of the brain which revealed a left frontoparietal subdural hematoma, a suspicious left high parietal lesion with evidence of peripheral hemorrhage, and brain edema with significant midline shift (A-C: Axial sections); D: postoperative CT-scan of the brain showing a decompressive craniectomy with gross total resection of the mass lesion and evacuation of the subdural hemorrhage; E, F: Postoperative CT scan of brain after the cranioplasty operation at 6 months follow-up.



**Fig. 2.** Histopathological examination of the hematoxylin and eosin stained material revealed spindle cells with indistinct cell boundaries arranged in intersecting fascicles without any mitosis and necrosis, consistent with fibroblastic meningioma, WHO grade I. The cells were strongly positive for EMA and PR. A: H&E section of the tumor showing fascicular pattern of bland looking spindle cells ( $\times 100$ ). B: EMA staining of the tumor cells ( $\times 200$ ). C: PR staining of the tumor cells ( $\times 200$ ).

Her hospital course went on uneventfully. She had no more seizures. She was discharged a week after surgery totally conscious in good condition with minimal right-side weakness. Two weeks after the surgery she was feeling quite well and her headache had subsided, and her weakness had totally been resolved. She reported no seizures. Two months after surgery, cranioplasty was performed for her without any complications. During the 6-month follow-up visits, no neurological deficits or a headache were noted (Figure 1, E-F).

## Discussion

Seizures occur in approximately 1.2% of all pregnancies [7] and are the most common neurologic complication observed in pregnant women. The underlying causes of seizures in pregnancy and postpartum are extensive, and include, but not limited to, epilepsy, eclampsia, cerebrovascular accidents (stroke, cerebral venous thrombosis, etc.), and other less common conditions such as tumors [6]. In pregnancy, eclampsia is of significant importance and should be top on the list in the initial evaluation of a new-onset seizure in pregnancy [5]. Eclampsia can occur even in the absence of pre-existing preeclampsia (hypertension, proteinuria, and edema) [8]. Although, brain imaging is not necessary for the evaluation, and management of eclampsia, it is indicated in cases of focal neurologic deficit, prolonged coma or when evidence regarding an underlying preeclampsia are lacking [6]. Therefore, determining the underlying cause, and providing appropriate therapy is critical to prevent adverse acute and long-term consequences [5].

A new-onset seizure is a presenting symptom in approximately 30% to 50% of brain tumors which always warrant a thorough workup [3]. Primary intracranial tumors represent the fifth leading cause of cancer-related death in women aged 20-39 years. In this age group, gliomas and meningiomas are the two most common primary brain tumors

[9, 10]. The incidence of brain tumors does not seem to be influenced by pregnancy. Brain tumors usually present with nonspecific symptoms such as a headache, nausea, vomiting, focal neurological deficit, and seizures which are related to an increase in intracranial pressure and mass effect of the tumor [3].

Meningiomas are the third most common intracranial tumors in pregnancy representing 14% of all intracranial tumors in pregnant women [9]. Meningiomas are strongly associated with female gender and female sex hormones. Although, the incidence of meningiomas does not increase during pregnancy, however, 70%-90% of these benign tumors express progesterone receptors, and 33%-38% are estrogen receptor positive, and pregnancy may affect the size and growth of these tumors [3, 11]. Approximately 60% of meningiomas present during the third trimester or shortly thereafter within the first postpartum week. High rates of visual symptoms and parasellar locations are features unique to pregnancy-related meningiomas [12].

Meningiomas are slow growing, present indolently, and cause symptoms mainly by a local mass effect [4]. Approximately 1.3% to 2.4% of meningiomas may bleed, but their acute presentation with hemorrhage mimicking cerebrovascular accidents is quite rare [1, 2, 4]. Different bleeding patterns (subarachnoid, intracerebral/intratumoral, and subdural hemorrhage) can occur in meningiomas [2, 13-16]. Bosnjak and colleagues reviewed 145 cases of unsuspected meningiomas which have presented with hemorrhage. Age over 70 years or below 30 years, convexity and intraventricular locations, and fibroblastic, malignant, and angioblastic histological types were associated with the increased bleeding tendency of intracranial meningiomas. Subdural and intracerebral hemorrhages were the most common patterns in convexity meningiomas (49.2% and 34.9%, respectively) [4]. Table 1 summarizes 38 cases of unsuspected meningiomas with acute subdural hemorrhage since 1966 to 2017. It is evident that cerebral convexity and meningothelial type

**Table 1.** Summary of the case reports of acute presentation of meningiomas with acute subdural hemorrhage

Authors/year	Age/Sex	Location	Type	Ref
Bingas & Meese, 1966	65, M	Convexity	Meningothelial	[17]
Cusick & Bailey, 1972	47, F	Convexity	Transitional	[18]
Modesti, et al., 1976	59, M	Sphenoid	Meningothelial	[19]
	49, F	Parasagittal	Meningothelial	
	72, F	Parasagittal	Angioblastic	
	69, M	Convexity	Meningothelial	
Walsh, et al., 1977	77, F	Olfactory G.	Meningothelial	[20]
Everett, et al., 1979	65, M	Convexity	Meningothelial	[21]
Patil, 1982	75, M	Convexity	Fibrous	[22]
Wang, et al., 1985	62, F	Convexity	NS	[23]
Kotwica&Zawirski, 1986	32, M	Convexity	Angioblastic	[24]
Tokunaga, et al., 1988	61, F	Convexity	Transitional	[25]
Jones &Blumbergs, 1989	76, F	Convexity	Meningothelial	[26]
Sato, et al., 1989	46, F	Convexity	Angioblastic	[27]
Niikawa, et al., 1990	49, F	Convexity	Meningothelial	[28]
Martinez-Lage, et al., 1991	70, M	Convexity	Meningothelial	[15]
Chaskis, et al., 1992	59, F	Convexity	Angioblastic	[29]
	62, M	Convexity	Meningothelial	
Chen, et al., 1992	79, M	Convexity	Fibrous	[30]
Renowden&Hourihan, 1992	41, F	Parasagittal	Meningothelial	[31]
Ueno, et al., 1993	67, M	Convexity	Meningothelial	[32]
Shimizu, et al., 1998	67, M	Convexity	Meningothelial	[33]
Sunada, et al., 1998	48, F	Parasagittal	Malignant	[34]
Okuno, et al., 1999	78, F	Falx	Transitional	[35]
Lefranc, et al., 2001	59, F	Convexity	Angioblastic	[14]
	62, M	Convexity	Meningothelial	
	68, F	Parasagittal	Meningothelial	
	85, F	Convexity	Atypical	
Goyal, et al., 2003	66, M	Falx	Transitional	[36]
Mitsuhara, et al., 2006	60, F	Petrotentorial	Meningothelial	[37]
Kashimura, et al., 2008	50, M	Convexity	Lipomatous	[38]
Worm, et al., 2009	64, M	Falx	NS	[39]
Lakshmi, et al., 2010	73, M	Sphenoid	NS	[13]
Chonan, et al., 2013	67, F	Convexity	Meningothelial	[40]
Hambra, et al., 2014	59, M	Sphenoid	Angiomatous	[1]
Kim, et al., 2015	61, F	Convexity	NS	[41]
Ravindran, et al., 2017	36, F	Convexity	NS	[2]

are the most common location and histologic type associated with subdural bleeding, respectively.

Mechanisms underlying hemorrhage within brain tumors have not been totally elucidated. Aberrant endothelial proliferation, friable blood vessels, and tumor necrosis may account for bleeding in malignant tumors, however, factors underlying hemorrhage within benign tumors are less obvious. In case of meningioma, cerebral edema, and venous congestion have been postulated to cause infarction and subsequent hemorrhage. Other precipitating factors include minor trauma, severe coughing, physical exertion, seizures, sexual activity, emotion, irradiation, and embolization of meningioma [4].

Complete discussion of the management of epilepsy and brain tumors, especially meningiomas, in pregnancy is beyond the scope of this paper, and the interested reader is referred to the reviews on the subject [3, 5, 6, 9, 11, 12]. In summary, management

of meningiomas in pregnancy poses a great challenge to the medical team. When managing these patients, it is necessary to take patients' general condition, gestational age, tumor's size, signs and symptoms of increased intracranial pressure, and patients' preferences into account. As a general rule, as long as the patient is in good general condition, and the tumor does not grow rapidly or cause any permanent neurological deficits, surgical intervention may be postponed until postpartum, and close follow-up with MRI would suffice. However, in emergency situations where signs and symptoms of increased intracranial pressure, significant edema and midline shift, decreased level of consciousness or acute neurological deficits are present, prompt surgical intervention would be the best choice [9]. Our case highlights the importance of a thorough evaluation of pregnant and postpartum women who present with new-onset seizures or focal neurological deficits,

and consideration of the less common but potentially devastating causes of seizure in pregnancy or the postpartum period.

In conclusion, based on observations in this case report and to our knowledge, postpartum seizure associated with acute subdural hemorrhage of a convexity meningioma is a very rare combination to occur. During pregnancy, the growth of meningiomas seems to be affected by hormonal changes, but

their dramatic and unsuspected presentation is uncommon. Although eclampsia and cerebrovascular accidents are high on the list of differential diagnosis for a new-onset seizure in pregnancy or postpartum period, brain tumors should also be considered a possible cause with potentially devastating outcomes which might need prompt surgical intervention.

**Conflicts of Interest:** None declared.

## References

- Hambra DV, Danilo de P, Alessandro R, Sara M, Juan GR. Meningioma associated with acute subdural hematoma: A review of the literature. *Surg Neurol Int.* 2014;**5**(Suppl 12):S469-71.
- Ravindran K, Gaillard F, Lasocki A. Spontaneous subdural haemorrhage due to meningioma in the post-partum setting. *J Clin Neurosci.* 2017;**39**:77-9.
- Bonfield CM, Engh JA. Pregnancy and brain tumors. *Neurol Clin.* 2012;**30**(3):937-46.
- Bosnjak R, Derham C, Popovic M, Ravnik J. Spontaneous intracranial meningioma bleeding: clinicopathological features and outcome. *J Neurosurg.* 2005;**103**(3):473-84.
- Bollig KJ, Jackson DL. Seizures in Pregnancy. *Obstet Gynecol Clin North Am.* 2018;**45**(2):349-67.
- Hart LA, Sibai BM. Seizures in pregnancy: epilepsy, eclampsia, and stroke. *Semin Perinatol.* 2013;**37**(4):207-24.
- Zack MM, Kobau R. National and State Estimates of the Numbers of Adults and Children with Active Epilepsy - United States, 2015. *MMWR Morb Mortal Wkly Rep.* 2017;**66**(31):821-5.
- Sibai BM. Eclampsia. VI. Maternal-perinatal outcome in 254 consecutive cases. *Am J Obstet Gynecol.* 1990;**163**(3):1049-54; discussion 54-5.
- Laviv Y, Bayoumi A, Mahadevan A, Young B, Boone M, Kasper EM. Meningiomas in pregnancy: timing of surgery and clinical outcomes as observed in 104 cases and establishment of a best management strategy. *Acta Neurochir (Wien).* 2017.
- Terry AR, Barker FG, 2nd, Leffert L, Bateman BT, Souter I, Plotkin SR. Outcomes of hospitalization in pregnant women with CNS neoplasms: a population-based study. *Neuro Oncol.* 2012;**14**(6):768-76.
- DeAngelis LM. Central nervous system neoplasms in pregnancy. *Adv Neurol.* 1994;**64**:139-52.
- Laviv Y, Ohla V, Kasper EM. Unique features of pregnancy-related meningiomas: lessons learned from 148 reported cases and theoretical implications of a prolactin modulated pathogenesis. *Neurosurg Rev.* 2018;**41**(1):95-108.
- Lakshmi Prasad G, Ramdurg SR, Suri A, Mahapatra AK. A rare association of meningioma with intratumoral bleed and acute subdural hematoma. *Neurol India.* 2010;**58**(6):977-8.
- Lefranc F, Nagy N, Dewitte O, Baleriaux D, Brotchi J. Intracranial meningiomas revealed by non-traumatic subdural haematomas: a series of four cases. *Acta Neurochir (Wien).* 2001;**143**(10):977-82; discussion 82-3.
- Martinez-Lage JF, Poza M, Martinez M, Esteban JA, Antunez MC, Sola J. Meningiomas with haemorrhagic onset. *Acta Neurochir (Wien).* 1991;**110**(3-4):129-32.
- Nery B, Costa RAF, Pereira LCT, Quaggio E, Coronatto LH, Tirapelli D, et al. Spontaneous subdural hematoma associated with microcystic meningioma: first case report in the literature. *Br J Neurosurg.* 2017:1-4.
- Bingas B, Meese M. [Subdural hematoma with a rare etiology (case report)]. *Nervenarzt.* 1966;**37**(4):175-7.
- Cusick JF, Bailey OT. Association of ossified subdural hematomas and a meningioma. Case report. *Journal of neurosurgery.* 1972;**37**(6):731-4.
- Modesti LM, Binet EF, Collins GH. Meningiomas causing spontaneous intracranial hematomas. *J Neurosurg.* 1976;**45**(4):437-41.
- Walsh JW, Winston KR, Smith T. Meningioma with subdural hematoma. *Surg Neurol.* 1977;**8**(4):293-5.
- Everett BA, Kusske JA, Pribram HW. Anticoagulants and intracerebral hemorrhage from an unsuspected meningioma. *Surg Neurol.* 1979;**11**(3):233-5.
- Patil AA. Intracranial meningioma with subdural membrane. A case report. *Acta Neurochir (Wien).* 1982;**66**(1-2):103-7.
- Wang AM, Chinwuba CE, O'Reilly GV, Kleeffeld J. Subdural hematoma in patients with brain tumor: CT evaluation. *J Comput Assist Tomogr.* 1985;**9**(3):511-3.
- Kotwica Z, Zawirski M. Subdural hematoma caused by cerebral tumors. *Zentralbl Neurochir.* 1986;**47**(3):259-62.
- Tokunaga T, Kuboyama M, Kojo N, Matsuo H, Shigemori M, Kuramoto S. [A case of acute subdural hematoma associated with convexity meningioma]. *No Shinkei Geka.* 1988;**16**(12):1389-93.
- Jones NR BP. Intracranial haemorrhage from meningiomas: a report of five cases. *Br J Neurosurg.* 1989;**3**(6):8.
- Sato K, Sugawara T, Fujiwara S, Mizoi K, Yoshimoto T. [A case of small meningioma with acute subdural hematoma]. *No Shinkei Geka.* 1989;**17**(7):687-90.
- Niikawa S, Kawaguchi M, Sugimoto S, Hattori T, Ohkuma A. Meningioma associated with subdural hematoma--case report. *Neurol Med Chir (Tokyo).* 1990;**30**(3):169-72.
- Chaskisa CRC, Notermana J, Flament-Durandb J, Brothia J. Meningioma associated with subdural haematoma: report of two cases and review of the literature. *Clinical Neurology and Neurosurgery.* 1992;**94**(3):6.
- Chen JW UH, Grafe MR. Unsuspected meningioma presenting as a subdural haematoma. *J Neural Neurosurg Psychiatry.* 1992;**55**(2):2.
- Renowden SA, Hourihan MD. Case report: acute subdural haematoma--an unusual presentation of a meningioma. *Clin Radiol.* 1992;**45**(5):351-2.
- Ueno M, Nakai E, Naka Y, Kido T, Itakura T, Komai N. Acute subdural hematoma associated with vacuolated meningioma--case report. *Neurol Med Chir (Tokyo).* 1993;**33**(1):36-9.
- Shimizu J, Tazawa T, Park-Matsumoto YC, Katano T, Akiba Y, Kuroiwa T. [Meningioma associated with acute subdural hematoma: a case report]. *No Shinkei Geka.* 1998;**26**(8):743-7.
- Sunada I, Nakabayashi H, Matsusaka

- Y, Yamamoto S. Meningioma associated with acute subdural hematoma--case report. *Radiat Med.* 1998;**16**(6):483-6.
35. Okuno S, Touho H, Ohnishi H, Karasawa J. Falx meningioma presenting as acute subdural hematoma: case report. *Surg Neurol.* 1999;**52**(2):180-4.
36. Goyal A, Singh AK, Kumar S, Gupta V, Singh D. Subdural hemorrhage associated with falx meningioma. *Neurol India.* 2003;**51**(3):419-21.
37. Mitsuhashi T, Ikawa F, Ohbayashi N, Imada Y, Abiko M, Inagawa T. [A case of petrotentorial meningioma presented as an acute subdural hemorrhage]. *No Shinkei Geka.* 2006;**34**(8):827-32.
38. Kashimura H, Arai H, Ogasawara K, Beppu T, Kurose A, Ogawa A. Lipomatous meningioma with concomitant acute subdural hematoma--case report. *Neurol Med Chir (Tokyo).* 2008;**48**(10):466-9.
39. Worm PV, Ferreira MP, Ferreira NP, Cechetti F. Subdural haematoma in a patient with meningioma. *Arq Neuropsiquiatr.* 2009;**67**(2A):308-10.
40. Chonan M, Niizuma K, Koyama S, Kon H, Sannohe S, Kurotaki H, et al. [An operated case of a meningioma causing acute subdural hematoma]. *No Shinkei Geka.* 2013;**41**(3):235-9.
41. Kim JH, Gwak HS, Hong EK, Bang CW, Lee SH, Yoo H. A case of benign meningioma presented with subdural hemorrhage. *Brain Tumor Res Treat.* 2015;**3**(1):30-3.

**Open Access License**

All articles published by Bulletin of Emergency And Trauma are fully open access: immediately freely available to read, download and share. Bulletin of Emergency And Trauma articles are published under a Creative Commons license (CC-BY-NC).