



Inferior Vena Cava Injuries: Sometimes Less is More

Eduardo Smith Singares^{1*}

¹Chief- Division of Trauma and Critical Care, Director of SICU, University of Illinois, Chicago, USA

***Corresponding author:** Eduardo Smith Singares
Address: Chief- Division of Trauma and Critical Care, Director of SICU, University of Illinois at Chicago, Chicago, IL, USA. **Tel:** 1-312-996-5632; **Fax:** 1-312-413-3483
e-mail: singares@uic.edu

Received: April 14, 2017
Revised: April 21, 2017
Accepted: April 22, 2017

Keywords: Inferior Vena Cava; Cavaplasty; Vascularized grafts.

Please cite this paper as:

Singares ES. Inferior Vena Cava Injuries: Sometimes Less is More. *Bull Emerg Trauma*. 2017;5(3):219-220.

Dear Editor,

I have reviewed the manuscript titled “Inferior Vena Cava Reconstruction by Gallbladder patch: An experimental design”, which has been published in the Bulletin of Emergency and Trauma [1]. I wish to commend the authors on their hard work and their ingenuity for this project. Their work is based on sound principles for the use of vascularized, composite grafts in the reconstruction of anatomical structures, vascular and otherwise.

In fact the opposite scenario (the use of venous grafts for the reconstruction of the biliary tract) is well known, having been described first in 1969 [2]. Recent case reports [3] describe the technique in combination with biliary stenting. The use of a vascularized gallbladder as a graft is also well established. A pedicled gallbladder has been used to reconstruct duodenal injuries [4], repair common bile duct injuries [5] and as a conduit for biliary drainage on a transplanted liver [6]. Likewise, the use of serosal patches of many origins to contain intestinal contamination or for difficult GI enteric reconstructions is an accepted technique in the management of complex injuries. In the previous issue of the Bulletin, one such report was made for the same target organ (the IVC) [7].

As a proof-of-concept, therefore, this study is in

distinguished company, and has enough merit to warrant publication. A word of caution, however, must be exercised when translating this results into clinical practice. The incidence of gallbladder disease alone in the Western population makes the use of a pedicled gallbladder graft for this indication inconvenient and potentially dangerous, turning a routine laparoscopic cholecystectomy into a mayor vascular reconstruction in a potentially infected field, the very reason a serosal patch would have been chosen in the first place.

Another question that begs pondering is obvious: does the IVC needs reconstruction? In considering this question one must make a distinction between elective cases and emergency ones. There is enough evidence to support the attempt to reconstruct the IVC that has been resected during major oncological procedures [8]. Alternatives in use currently include a variety of vascular conduits such as Dacron, Gore-Tex and other varieties of PTFE. There are also autologous grafts, such as renal vein, tubularized saphenous vein, inferior mesenteric vein, ovarian veins, the internal jugular vein, and autologous peritoneum-fascia [9] and pericardium [10], my preferred technique (Figure 1).

During the damage-control management of a patient with an infrarenal IVC traumatic injury,

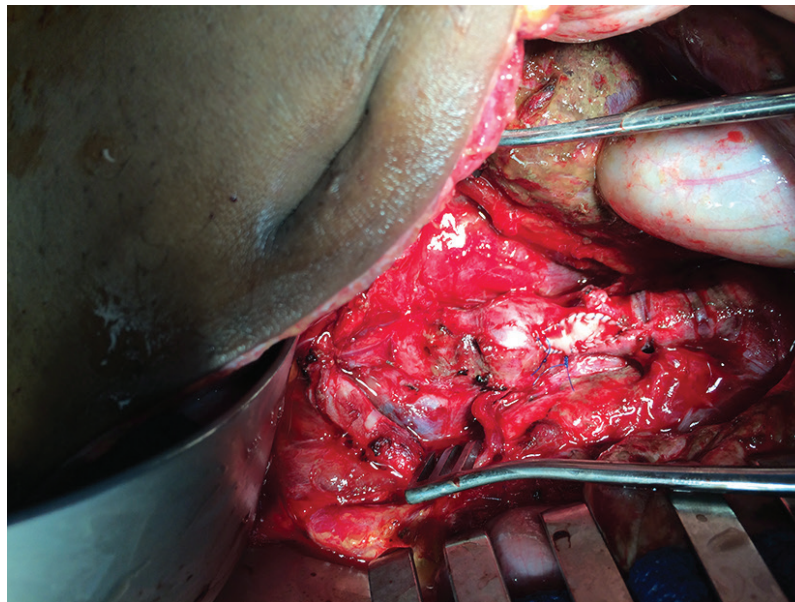


Fig. 1. Autologous pericardium cavaplasty-reconstruction during damage-control surgery in a multiple GSW victim.

consideration should be given to the ligation of the vein. This procedure is well tolerated, and follow up has shown little more than trace edema in the lower extremities at 1 year [11]. On the other hand, the suprarenal vena cava does necessitate reconstruction: while the overall survival of the infrarenal IVC ligation was 72%, only occasional survivors are reported above the renal veins for ligation [11]. Short term patency rates have been studied for venous reconstruction in trauma of the IVC. For lateral venorrhaphy, the patency rate was documented by US, CT scan of both at around 86% [11]. Unfortunately, at this moment there is no long

term patency data with the use of interposition grafts or patch-type reconstructions.

In closing: Although a valuable addition to the existing literature on the topic (and a starting point for future research), at this moment there is no impetus to recommend the use of exotic biological vascularized grafts for the management of this type of problem; the use of sound damage-control principles and the current materials available to choose from seem to offer more than adequate results to the majority of patients sustaining this type of injury.

Conflict of Interest: None declared.

References

- Hodjati H, Sohrabi Nazari S, Dehghani Nazhvani S, Karami MY, Geramizadeh B. Inferior Vena Cava Reconstruction by Gallbladder Patch: An Experimental Design. *Bull Emerg Trauma*. 2017;**5**(3):160-164.
- Mainetti JM, Soria NR. Choledochoplasty with saphenous vein. *Prensa Med Argent*. 1969;**56**(17):810-2.
- Biglari M, Van den Bussche D, Vanlangenhove P. Reconstruction of a common bile duct injury by venous bypass. *Acta Chir Belg*. 2013;**113**(4):308-10.
- Rohondia OS, Bapat RD, Husain S, Shriyan PG, Pradhan R, Kumar KS. Cholecystoduodenoplasty for high-output duodenal fistula. *Indian J Gastroenterol*. 2001;**20**(3):107-8.
- Sandblom P, Tabrizian M, Rigo M, Fluckiger A. Repair of common bile duct defects using the gallbladder or cystic duct as a pedicled graft. *Surg Gynecol Obstet*. 1975;**140**(3):425-32.
- Calne RY. A new technique for biliary drainage in orthotopic liver transplantation utilizing the gall bladder as a pedicle graft conduit between the donor and recipient common bile ducts. *Ann Surg*. 1976;**184**(5):605-9.
- Hodjati H, Hoseinzadeh A, Mousavi SM, Dehghani Nazhavi S, Kumar V, Sehhatpour M. Inferior Vena Cava Repair Using Serosal Patch of Small Bowel: An Experimental Study. *Bull Emerg Trauma*. 2017;**5**(1):24-8.
- Quinones-Baldrich W, Alktaifi A, Eilber F. Inferior vena cava resection and reconstruction for retroperitoneal tumor excision. *J Vasc Surg*. 2012;**55**(5):1386-93; discussion 93.
- Chin PT, Gallagher PJ, Stephen MS. Inferior vena caval resection with autogenous peritoneo-fascial patch graft caval repair: a new technique. *Aust N Z J Surg*. 1999;**69**(5):391-2.
- Piccione W, Jr., Faber LP, Warren WH. Superior vena caval reconstruction using autologous pericardium. *Ann Thorac Surg*. 1990;**50**(3):417-9.
- Asensio JA, Chahwan S, Hanpeter D, Demetriades D, Forno W, Gambaro E, et al. Operative management and outcome of 302 abdominal vascular injuries. *Am J Surg*. 2000;**180**(6):528-33; discussion 33-4.