



## Effect of Fibrin Packing on Managing Hepatic Hemorrhage and Liver Wound Healing in a Model of Liver Stab Wound in Rat

Mehrzad Banihashemi<sup>1</sup>, Azam Safari<sup>1</sup>, Navid Nezafat<sup>1</sup>, Mahmoodreza Tahamtan<sup>2</sup>, Manica Negahdaripour<sup>1,3</sup>, Negar Azarpira<sup>4,5</sup>, Younes Ghasemi<sup>1,3\*</sup>

<sup>1</sup>Pharmaceutical Sciences Research Center, Shiraz University of Medical Sciences, Shiraz, Iran

<sup>2</sup>Department of Pathobiology, Saadati Pathobiology Laboratory, Shiraz, Iran

<sup>3</sup>Department of Pharmaceutical Biotechnology, School of Pharmacy, Shiraz University of Medical Sciences, Shiraz, Iran

<sup>4</sup>Transplant Research Center, Shiraz University of Medical Sciences, Shiraz, Iran

<sup>5</sup>Department of pathology, Shiraz University of Medical Sciences, Shiraz, Iran

\*Corresponding author: Younes Ghasemi

Address: Department of Pharmaceutical Biotechnology, Faculty of Pharmacy, Shiraz University of Medical Sciences, P.O. Box 71345-1583, Shiraz, Iran.

Tel/Fax: +98-71-32426729

e-mail: ghasemiy@sums.ac.ir

Received: June 25, 2016

Revised: September 10, 2016

Accepted: September 12, 2016

### ABSTRACT

**Objective:** To evaluate the effect of fibrin perihepatic packing on controlling liver hemorrhage and liver wound healing.

**Methods:** In this animal experimental study, 20 adult male Sprague Dawley rats, weighing 200-220 g, were included. Stab wound injury was created by number 15 scalpel, so that bilateral liver capsules and liver tissue were cut, and acute bleeding was accrued. The animals were divided into 2 study groups: control (with a primary gauze packing treatment) and test group (with fibrin packing treatment). Serum alanine aminotransferase (ALT), aspartate aminotransferase (AST), and total serum bilirubin (TSB) levels were measured as a liver function test during the treatment period. Blood loss was calculated for estimation of hepatic hemorrhage during surgery. After four weeks, the liver wound repair was evaluated by sampling and Hematoxylin and Eosin staining (H&E).

**Results:** In the test group, all of animals were alive (mortality rate=0%). Significantly, ALT and AST levels were raised after surgery, followed by a decrease ALT ( $p=0.783$ ) and AST ( $p=0.947$ ) to the normal level during 4 days. Estimated blood loss was  $2.89 \pm 0.73$  mL (about 19.65% of estimated blood volume). Hematocrit levels returned to the normal level ( $p=0.109$ ) after 48 hours. In the control group, the mortality rate was 50% during 12h after surgery. ALT ( $p=0.773$ ) and AST ( $p=0.853$ ) were decreased to normal level during 6 days, and estimated blood loss was  $4.98 \pm 0.77$  mL (about 32.98% of estimated blood volume) in the remaining animals. Moreover, hematocrit levels returned to the normal level ( $p=0.432$ ) after 72 hours. Estimated blood loss in the test group was significantly less than control group ( $p<0.001$ ). Total serum bilirubin levels were not significantly different from the normal level, before and after surgery in both groups. Histopathology sections from the post-hepatectomy specimens showed that the site of the previous incision was completely repaired, and a dense fibrous septum was observed in both groups.

**Conclusion:** The fibrin dressing was effective in preventing blood loss and saving lives after a liver stab injury and major internal bleeding in the animal model of rat.

**Keywords:** Fibrin packing; Liver; Trauma; Hemorrhage; Wound healing; Penetrating injury

Please cite this paper as:

Banihashemi M, Safari A, Nezafat N, Tahamtan MR, Negahdaripour M, Azarpira N, Ghasemi Y. Effect of Fibrin Packing on Managing Hepatic Hemorrhage and Liver Wound Healing in a Model of Liver Stab Wound in Rat. *Bull Emerg Trauma*. 2017;5(1):18-23.

## Introduction

Traumatic injuries are the primary cause of death in 1 to 34 years-old people and are the fifth leading cause of death in USA [1]. In trauma handling, hemorrhage management plays an important role in surgery success and saving patients' lives [2, 3]. In the external wounds with an active bleeding, direct compression can significantly reduce blood loss volume. Internal bleeding and anemia are the most important causes of death in liver injuries. Approximately, 25 percent of liver injuries lead to mortality. After liver injuries, when internal bleeding occurs, coagulopathy can happen as a result of hypothermia, dilution of clotting factors, and thrombocytopenia [4]. Blunt abdominal trauma is a leading cause of morbidity and mortality among all age groups. Liver and spleen are the most frequently injured organs. In managing blunt abdominal trauma, in order to control hemorrhage and spillage, laparotomy is the usual indication for patients with features of hemodynamic instability and peritonitis. Perihepatic packing (PHP) is the most successful method for bleeding management. The most important goal in PHP methods is achieving a faster hemostasis by packing the liver with placing surgical pads, and the correction of acidosis, coagulopathy, and hypothermia. Sepsis, vascular collapse, and re-bleeding after packs removal are some of the complications of PHP methods [3, 5].

Naturally, fibrinogen and fibrin play a key role in blood clotting. After a vessel injury, fibrin is formed as the lead of the clotting cascade, and blood cells are trapped to fibrin mesh. The fibrinogen molecule is comprised of two sets of three polypeptide chains, termed  $A\alpha$ ,  $B\beta$ , and  $\gamma$ , which are joined together in the N-terminal E domain by five symmetrical disulfide bridges [6].

Interactions between the specific-binding sites on fibrin, pro-enzymes, clotting factors, enzyme inhibitors, and cell receptors play an important role in blood clotting, fibrinolysis, cellular and matrix interactions, inflammation, wound healing, angiogenesis, and neoplasia [7]. Fibrin also acts as a vector for delivering growth factors. Growth factors play an essential role in cell proliferation, migration, differentiation, and tissue regeneration. Fibrin is a modulator of macrophages activity and changer rate between wound inflammation and tissue repair. Endothelial cells injury stimulates the synthesis of platelet-activating factor (PAF) as a primary hemostasis process and wound healing [8]. Following binding of fibrin to the platelet integrin  $\alpha$ IIb $\beta$ 3 receptors, a platelet plug will be formed that includes activated platelets and fibrin fibers [9]. These activated platelets secrete a number of growth factors, such as platelet-derived growth factor (PDGF). Subsequently, PDGF stimulates the process of wound healing by activating fibroblasts to produce collagen, glycosaminoglycans, and proteoglycans

[10]. Moreover, coagulation cascade activates several components including thrombin and fibrin, which can promote angiogenesis and wound repairing [11].

In recent years, a range of topical haemostatic agents and techniques became available that led to surgical success. These products, which are classified as topical hemostats, sealants, and adhesives, would be fast-acting, non-antigenic, easily applied and removed, inexpensive, stable and transportable with few side-effects [2, 12]. These applicants are ready-to-use. They are made from equine collagen coated with human fibrinogen and thrombin and initiate the final steps of coagulation cascade [13]. The main objective of this study is evaluation of fibrin perihepatic packing method on the control of liver hemorrhage and liver wound healing.

## Materials and Methods

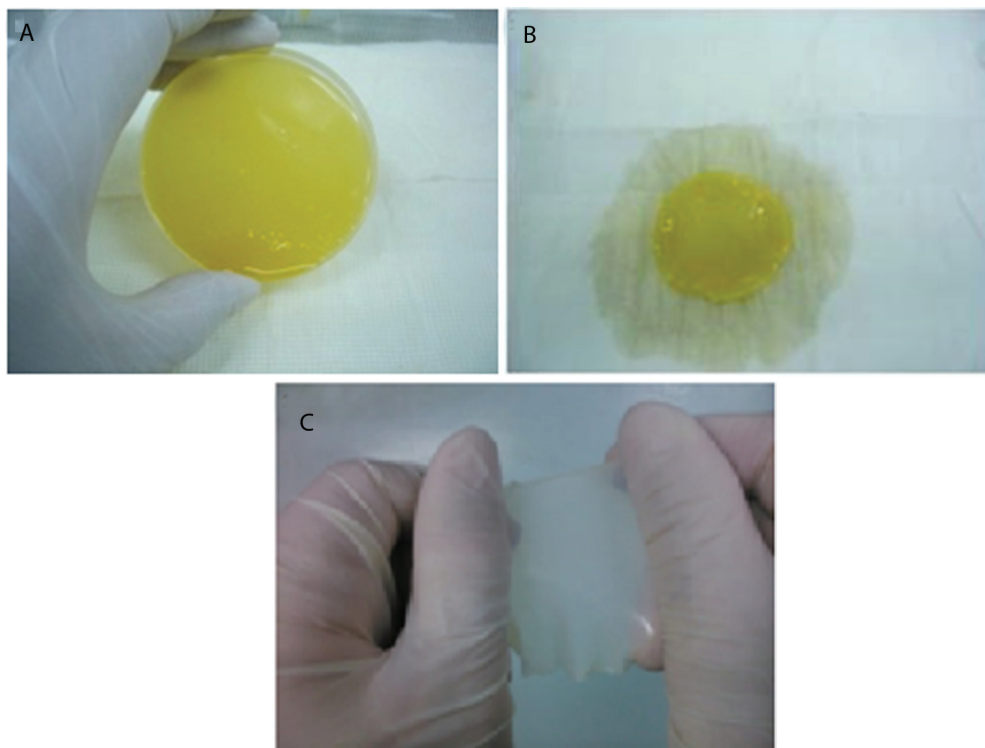
### Animal Preparation

All the procedures involving animal subjects were reviewed and approved by the Institutional Research Ethics Committee of Shiraz University of Medical Sciences. Male Sprague-Dawley rats (n=20), weighing 200-220 g, were selected from the Laboratory Animal Center of Shiraz University of Medical Sciences (Shiraz, Iran). The animals were acclimatized in the animal house facility and were kept under controlled humidity and temperature for at least 5 days before surgery. The animals were divided into two groups: control (with a primary gauze packing treatment) and test group (with fibrin packing treatment). Animals were maintained on a regular 12-hr dark/light cycle (6 PM to 6 AM). Food and water were ad libitum [14, 15]. The study protocol was approved by the institutional review board (IRB) of Shiraz University of Medical Sciences.

### Fibrin Patch Preparation

Fresh frozen human plasma (FFP) with normal coagulation parameters and 300mg/dl fibrinogen concentration, citrate phosphate dextrose adenine (CPDA-1) (as an anticoagulant) was obtained from Iranian blood transfusion organization. FFP was thawed in room temperature. 25 ml of plasma was derived and poured in a 50 ml falcon tube in sterile conditions. The falcon tube was centrifuged at 3000 rpm for 5 min. Then 20 ml of the top plasma was transferred to a 10 cm glass dish. In the next step, 1 ml of  $CaCl_2$  with 0.2 mol concentration was added to the plasma and was mixed well. The plasma was incubated at 37 °C until fibrin formation was completed and plasma was gelated (Figure 1A). Slowly and carefully, the clotted plasma was isolated from the dish wall by a surgery knife in a sterile condition. Then it was put upside down on an autoclaved plastic mesh with a toilet paper under the mesh as a fluid absorbent (Figure 1B).

After about 10 min, when the plasma fluid was absorbed, the fibrin fibers became compact and made



**Fig. 1.** Fibrin patch preparation: gelating plasma after 1ml of  $\text{CaCl}_2$  with 0.2mol concentration was added to 20ml of plasma and incubated at  $37^\circ\text{C}$  (A); putting clot of plasma upside down on a plastic mesh while applying toilet paper under the mesh as a fluid absorbent (B); removing fibrin layer from the mesh and keeping between the fingers of both hands in the flattened state (C).

a fibrin layer on the mesh. It should be noted that the fibrin layer will dry up, if it is not in wet conditions. For this purpose, while the fibrin layer is connected to the net, it should be put in a container containing a piece of wet gas and be kept closed until usage. When using, with the help of forceps, the fibrin layer should be removed carefully and slowly from the mesh and be kept between the fingers of both hands in the flattened state (Figure 1C).

#### *Anesthesia and Abdominal Skin Preparation*

To reduce contamination, animals were prepared for surgery at a bench in another room separated from surgical operation area. General anesthesia was administrated by intraperitoneal injection combined of 100 mg/kg ketamine and 10 mg/kg xylazine. After anesthesia, which was confirmed with no response to pain stimulus and absence of corneal reflex, animals were located horizontally in dorsal position with all paws held by sticky tape. Then their abdominal hairs were removed carefully by a #40 blade. The area along the incision line and extended outward in a circular pattern was prepped with a betadine-impregnated gauze.

#### *Laparotomy*

With a number 21 cold scalpel, an approximately 3.5 cm median incision was generated. After opening the abdominal cavity, the median lobe was pulled out, and a 4-5 mm injury was created by a number 15 scalpel, so that bilateral liver capsules and liver tissue were cut (Figure 2A). Following this major injury, acute bleeding was accrued. In this step, in

the control group, we tried to control bleeding with sterile gauze bondage. After 10 minutes, bondage was opened and the liver was returned to the abdominal cavity. In the test group, fibrin patch was spread immediately and the median lobe was returned on the fibrin patch. The four corners of the fibrin patch were folded over the median lobe and sutured to each other (Figure 2B). Abdominal was sutured by 5-0 vicryl needle.

#### *Blood Sampling*

About 10 minutes before surgery, when animals were anesthetized, 0.5 ml tail blood samples were collected in two types of tube; ethylene diamine tetra acetic acid (K3-EDTA), the tubes for hematocrit (HCT) assay and clot samples for evaluation of liver function tests (ALT, AST, TSB). Sampling was repeated 2 hours after surgery as well. During 6 days after surgery, blood sampling was done for evaluation of ALT, AST, TSB, and HCT levels. Clot samples were allowed to stand for 30 minutes in room temperature and were centrifuged at 3000 g for 5 min to separate the serum from the blood cells.

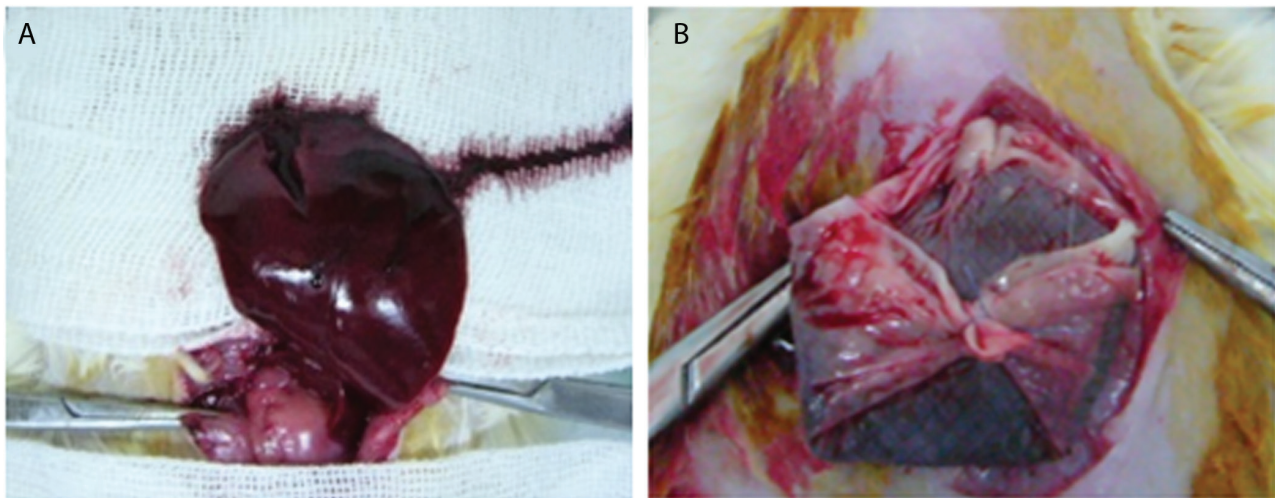
#### *Evaluation of Liver Function*

Evaluation of liver function was performed by using enzymatic colorimetric ALT, AST kits (Mancompany, Iran) and using a nonchemical photometric device to measure TSB, before and daily for 6 days after surgery.

#### *Measurement of Blood Loss*

Blood loss was calculated by Gross' formula. No





**Fig. 2.** Creating injury by a number 15 scalpel so that bilateral liver capsules and liver tissue were cut (A); fibrin dressing, the four corners of fibrin layer were folded over the median lobe and sutured to each other (B).

fluid and blood transfer was used during and after surgery. Estimated blood loss =  $EBV \times (Hct_0 - Hct_f) / Hct_{AV}$ . Where estimated blood volume (EBV) is 7% of body weight [16];  $Hct_0$  is the initial hematocrit before surgery,  $Hct_f$  is the patient's minimum allowable hematocrit and  $Hct_{AV}$  is the average of the initial and minimum hematocrit [17].

### Histopathology

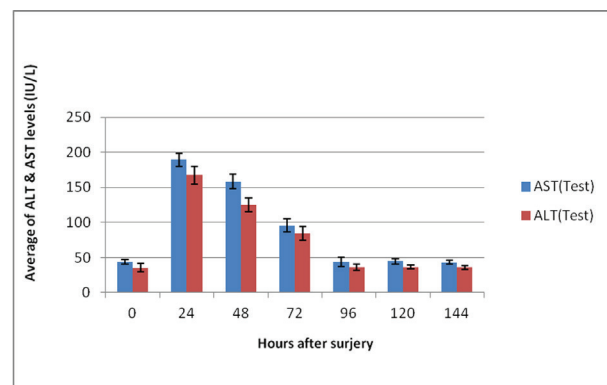
After 4 weeks, all rats were anesthetized and killed. The liver lobes were fixed in 10% buffered formalin. After 48 hours, the lobes with inflicted injury were cut in 6×6 mm slices and embedded in paraffin. Slide preparation was done with thin layer (4μ diameter) tissue slices. Then slides were stained with Hematoxylin and Eosin staining based on standard Elastica-van Gieson protocol.

### Statistical Analysis

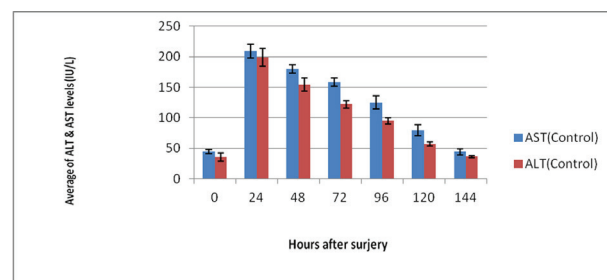
All the statistical analyses were performed using statistical package for social sciences (SPSS Inc., Chicago, Illinois, USA) version 16.0. The parametric data were compared using Paired Samples *t*-test before and after the surgery. independent *t*-test was used to compare the data between two study group. A 2-sided *p*-value of less than 0.05 was considered statistically significant.

### Results

In the test group, all animals were alive (mortality rate=0%). Significantly, ALT and AST levels were raised after surgery, followed by a decrease ALT ( $p=0.783$ ) and AST ( $p=0.947$ ) to the normal level during 4 days (Figure 3). Estimated blood loss was  $2.89 \pm 0.73$  ml (about 19.65% of estimated blood volume). Hematocrit returned to normal level ( $p=0.109$ ) after 48 hrs. In the control group, the mortality rate was 50% during 12 hrs after surgery (These animals were excluded from the study). ALT ( $p=0.773$ ) and AST ( $p=0.853$ ) levels decreased to reach the normal level during 6 days (Figure



**Fig. 3.** Rise of ALT and AST levels (IU/L) after surgery and return to normal level ( $p < 0.05$ ) during 96 hrs in the test group.

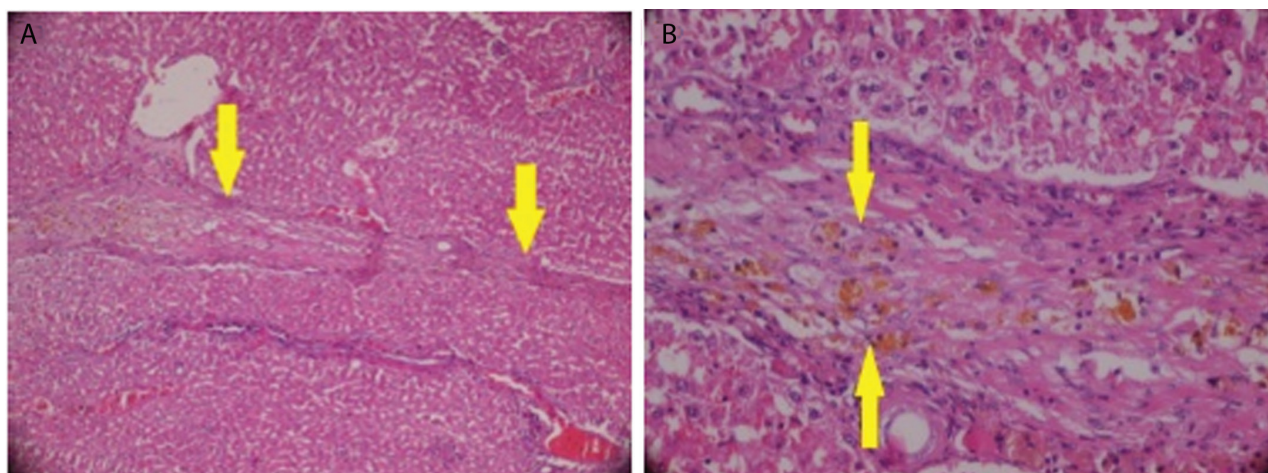


**Fig. 4.** Rise of ALT and AST levels (IU/L) after surgery and return to normal level ( $p < 0.05$ ) during 144 hrs in the control group.

4). Estimated blood loss was  $4.98 \pm 0.77$  ml (about 32.98% of the estimated blood volume). It was also observed that hematocrit returned to the normal level ( $p=0.432$ ) after 72 hrs. Totally, the observed results, indicated that estimated blood loss in the test group, was significantly ( $p < 0.001$ ) less than control group (Table 1). Total serum bilirubin levels were not notably different from the normal level, before and after surgery in both groups. Histopathology sections from the post hepatectomy specimens showed that the site of previous incision was completely repaired, and dense fibrous septum was observed in both control and test groups (Figure 5A). This band contained hemosidrine laden macrophages, which were in favor of old hemorrhage in this site (Figure 5B).

**Table 1.** Average of hematocrit and estimated blood loss in test and control group

	Test	Control	p value
Number of animals	10	5	–
Animals weight ( gr)	210±4.95	215±2.6	0.071
Estimated blood volume (ml)	14.7±0.34	15.1±0.17	0.029
Estimated blood loss (ml)	2.89±0.73	4.98±0.77	<0.001
<b>Hematocrit (%)</b>			
Before surgery	44.23±2.33	43.65±1.61	0.064
2-hour after surgery	36.30±1.46	31.2±1.19	<0.001
48-hour after surgery	43.80±1.99	36.5±1.26	<0.001
72-hour after surgery	43.82±1.92	42.6±0.95	0.235



**Fig. 5.** Histopathology sections from post-hepatectomy. The site of previous incision was completely repaired and dense fibrous septum was observed, the dense fibrous septum shown in yellow arrows. H&E staining  $\times 10$  (A); Hemosiderin laden macrophages, which were in favor of old hemorrhage in this site, shown in yellow arrows. H&E staining  $\times 40$  (B).

## Discussion

Liver and other parenchymatous organs are at the risk of various types of abdominal trauma, with a mortality rate greater than 60% [18]. Uncontrollable hemorrhage, coagulopathy, multiple organ failure, and sepsis are the consequences of abdominal injuries, which cause a high mortality rate.

Fibrin is a natural substance with a high potential for application in tissue engineering and wound healing [19]. Fresh and autologous fibrin patch as a suitable source of PDGF, cytokines, and other components, plays an essential role in wound healing [20]. Other studies also showed that cell proliferation, migration, differentiation, and tissue regeneration are related to fibrin activities [21]. A variety of studies have shown successful hemorrhage control with fibrin sealants in the presence of coagulopathy and in a trauma setting [22-24]. Usage of liquid fibrin sealant may be difficult and time-consuming. Additionally, they can easily be diluted and washed off the surface by high-volume bleeding in lacerated large vessels. Dry fibrin sealant dressings (FSD) are more effective than standard gauze swabs when used to pack grade V liver lacerations with severe large venous hemorrhage [25].

Some studies on liver packing methods have shown some adverse effects such as inability to control bleeding, increasing the rate of liver parenchymal necrosis due to pressure on the hepatic portal vein and

hepatic arteries and increasing the rate of abdominal abscess formation. Moreover, the risk of rebleeding in second surgery and some adverse effects on the pulmonary and cardiovascular functions can be accrued [5, 26, 27]. Besides the above-mentioned drawbacks, the complications of perihepatic packing methods are sepsis and vascular collapse following pack removal [26], but the most important aspect of our fibrin dressing is being digestible by plasmin enzymes and also absorbable (no need for second surgery and patch removal).

This study showed that mortality rate was significantly less in the test group (with liver fibrin perihepatic packing) than control group (with gauze dressing). The estimated blood loss decreased significantly in test group in comparison to the control group (about 2.9 mL in test group and 4.9 mL in control group). Furthermore, the returning time of hematocrit (48h in test and 72h in the control group) and returning time of liver functional enzymes to normal levels were significantly faster than the control group (4 days in test and 6 days in the control group). However, there was no significant difference in the bilirubin level between two groups.

Notably, our experimental animal trial evaluated the effects of a noncommercial fibrin patch that was made without using external thrombin as a coagulation activator. Similar to other studies, our result showed that fibrin dressing could be effective in preventing blood loss and saving lives [5, 22-24].



In addition, the time of returning ALT and AST to normal levels in the test group, showed that fibrin dressing was effective in wound healing [28].

In conclusion, the fibrin dressing is effective approach in preventing blood loss and saving lives after a liver stab injury and major internal bleeding in the animal model of rat. Although, this method prevents bleeding and is suitable for injury treatment, we recommend autologous fibrin patch for human surgery protocols. Moreover, comprehensive clinical

and immunological examinations may be needed to avoid possible side effects.

### Acknowledgment

The authors wish to thank Shiraz University of Medical Sciences for supporting the conduct of this research.

**Conflict of Interest:** None declared.

### References

- Holcomb JB. Methods for improved hemorrhage control. *Crit Care*. 2004;**8** Suppl 2:S57-60.
- Zentai C, Braunschweig T, Rossaint R, Daniels M, Czaplik M, Tolba R, et al. Fibrin patch in a pig model with blunt liver injury under severe hypothermia. *J Surg Res*. 2014;**187**(2):616-24.
- Paydar S, Mahmoodi M, Jamshidi M, Niakan H, Keshavarz M, Moeenvaziri N, et al. Perihepatic Packing versus Primary Surgical Repair in Patients with Blunt Liver Trauma; an 8-year Experience. *Bull Emerg Trauma*. 2014;**2**(3):103-9.
- Navarro A, Brooks A. Use of local pro-coagulant haemostatic agents for intra-cavity control of haemorrhage after trauma. *Eur J Trauma Emerg Surg*. 2015;**41**(5):493-500.
- Ebrahimi S, Tahmasebi S, Rouhezamin MR, Mousavi SM, Abbasi HR, Bolandparvaz S, et al. Modified Perihepatic Packing; A Creative and Beneficial Method for Management of High Grade Liver Injury. *Bull Emerg Trauma*. 2013;**1**(1):22-7.
- Mosesson MW. Fibrinogen and fibrin structure and functions. *J Thromb Haemost*. 2005;**3**(8):1894-904.
- Clark RA, Lanigan JM, DellaPelle P, Manseau E, Dvorak HF, Colvin RB. Fibronectin and fibrin provide a provisional matrix for epidermal cell migration during wound reepithelialization. *J Invest Dermatol*. 1982;**79**(5):264-9.
- Lewis MS, Whatley RE, Cain P, McIntyre TM, Prescott SM, Zimmerman GA. Hydrogen peroxide stimulates the synthesis of platelet-activating factor by endothelium and induces endothelial cell-dependent neutrophil adhesion. *J Clin Invest*. 1988;**82**(6):2045-55.
- Joo SJ. Mechanisms of Platelet Activation and Integrin alphaIIbeta3. *Korean Circ J*. 2012;**42**(5):295-301.
- Marx RE, Carlson ER, Eichstaedt RM, Schimmele SR, Strauss JE, Georgeff KR. Platelet-rich plasma: Growth factor enhancement for bone grafts. *Oral Surg Oral Med Oral Pathol Oral Radiol Endod*. 1998;**85**(6):638-46.
- Nehls V, Schuchardt E, Drenckhahn D. The effect of fibroblasts, vascular smooth muscle cells, and pericytes on sprout formation of endothelial cells in a fibrin gel angiogenesis system. *Microvasc Res*. 1994;**48**(3):349-63.
- Gruen RL, Brohi K, Schreiber M, Balogh ZJ, Pitt V, Narayan M, et al. Haemorrhage control in severely injured patients. *Lancet*. 2012;**380**(9847):1099-108.
- Grottke O, Braunschweig T, Daheim N, Coburn M, Grieb G, Rossaint R, et al. Effect of TachoSil in a coagulopathic pig model with blunt liver injuries. *J Surg Res*. 2011;**171**(1):234-9.
- Rafati A, Taj SH, Azarpira N, Zarifkar A, Noorafshan A, Najafizadeh P. Chronic morphine consumption increase allograft rejection rate in rat through inflammatory reactions. *Iran Biomed J*. 2011;**15**(3):85-91.
- Kuwahara R, Kawaguchi S, Kohara Y, Jojima T, Yamashita K. Bisphenol A does not affect memory performance in adult male rats. *Cell Mol Neurobiol*. 2014;**34**(3):333-42.
- Lee H, Blaufox M. Blood volume in the rat. *Journal of Nuclear Medicine*. 1985;**26**(1):72-6.
- Gibon E, Courpied JP, Hamadouche M. Total joint replacement and blood loss: what is the best equation? *Int Orthop*. 2013;**37**(4):735-9.
- Pusateri AE, McCarthy SJ, Gregory KW, Harris RA, Cardenas L, McManus AT, et al. Effect of a chitosan-based hemostatic dressing on blood loss and survival in a model of severe venous hemorrhage and hepatic injury in swine. *J Trauma*. 2003;**54**(1):177-82.
- Mendez JJ, Ghaedi M, Sivarapatna A, Dimitrievska S, Shao Z, Osuji CO, et al. Mesenchymal stromal cells form vascular tubes when placed in fibrin sealant and accelerate wound healing in vivo. *Biomaterials*. 2015;**40**:61-71.
- Mirza RE, Koh TJ. Contributions of cell subsets to cytokine production during normal and impaired wound healing. *Cytokine*. 2015;**71**(2):409-12.
- Banihashemi M, Mohkam M, Safari A, Nezafat N, Negahdaripour M, Mohammadi F, et al. Optimization of Three Dimensional Culturing of the HepG2 Cell Line in Fibrin Scaffold. *Hepat Mon*. 2015;**15**(3):e22731.
- Pusateri AE, Delgado AV, Dick EJ, Jr., Martinez RS, Holcomb JB, Ryan KL. Application of a granular mineral-based hemostatic agent (QuikClot) to reduce blood loss after grade V liver injury in swine. *J Trauma*. 2004;**57**(3):555-62; discussion 62.
- Jewelewicz DD, Cohn SM, Crookes BA, Proctor KG. Modified rapid deployment hemostat bandage reduces blood loss and mortality in coagulopathic pigs with severe liver injury. *J Trauma*. 2003;**55**(2):275-80; discussion 80-1.
- Holcomb JB, Pusateri AE, Harris RA, Reid TJ, Beall LD, Hess JR, et al. Dry fibrin sealant dressings reduce blood loss, resuscitation volume, and improve survival in hypothermic coagulopathic swine with grade V liver injuries. *J Trauma*. 1999;**47**(2):233-40; discussion 40-2.
- Navarro A, Brooks A. Use of local pro-coagulant haemostatic agents for intra-cavity control of haemorrhage after trauma. *Eur J Trauma Emerg Surg*. 2015;**41**(5):493-500.
- Nicol AJ, Hommes M, Primrose R, Navsaria PH, Krige JE. Packing for control of hemorrhage in major liver trauma. *World J Surg*. 2007;**31**(3):569-74.
- Meldrum DR, Moore FA, Moore EE, Haenel JB, Cosgriff N, Burch JM, Jack A. Barney Resident Research Award. Cardiopulmonary hazards of perihepatic packing for major liver injuries. *Am J Surg*. 1995;**170**(6):537-40; discussion 40-2.
- Jackson MR. Fibrin sealants in surgical practice: An overview. *Am J Surg*. 2001;**182**(2 Suppl):1S-7S.