



Ketamine Infusion Therapy as an Alternative Pain Control Strategy in Patients with Multi-Trauma including Rib Fracture; Case Report and Literature Review

Ashley K Losing¹, Justin M Jones¹, Adis Keric¹, Steven E Briggs², David D Leedahl^{1*}

¹Pharmacy Services, Sanford Health, Fargo ND, USA

²Department of Trauma and Acute Care Surgery, Sanford Health, Fargo ND, USA

*Corresponding author: David D Leedahl

Address: 801 Broadway N, Rt 204, Fargo, ND 58122, USA. Tel: +1-701-2345470;

Fax: +1-701-2345090

e-mail: david.leedahl@sanfordhealth.org

Received: May 27, 2016

Revised: June 8, 2016

Accepted: June 12, 2016

► ABSTRACT

Ketamine is a promising alternative agent for pain control that offers benefit to traditional strategies, particularly in the setting of rib fracture. Current pharmacologic therapies have clear adverse effects, and other options may be invasive, cost prohibitive, or marginally effective. We describe three consecutive patients with traumatic injuries including rib fracture for which a ketamine infusion was utilized as part of their pain control strategy. For each patient, use of a ketamine infusion trended toward reduced opioid requirements with stable pain scores. One patient experienced a dissociative adverse effect prompting decrease and discontinuation of ketamine. No pulmonary complications in the form of emergent intubation or new diagnosis of pneumonia were observed. We believe the addition of ketamine infusion to be a valid alternative strategy for managing pain associated with rib fracture.

Keywords: Thoracic injury; Rib fracture; Pain management; Ketamine.

Please cite this paper as:

Losing AK, Jones JM, Keric A, Briggs SE, Leedahl DD. Ketamine Infusion Therapy as an Alternative Pain Control Strategy in Patients with Multi-Trauma including Rib Fracture; Case Report and Literature Review. *Bull Emerg Trauma*. 2016;4(3):165-169.

Introduction

Rib fracture occurs in up to 80% of patients with blunt chest trauma and is managed by controlling pain, optimizing pulmonary hygiene, and facilitating mobilization [1,2]. Although opioids and non-steroidal anti-inflammatory drugs (NSAIDs) are commonly utilized to alleviate rib fracture pain, untoward side effects may include constipation, respiratory depression, acute kidney

injury, and gastrointestinal bleeding. The balancing act between pain control and pulmonary hygiene is most delicate in the setting of rib fracture, wherein the patient's ability to take deep breaths is a therapeutic goal (indicating pain relief) that is, in turn, threatened by the therapy itself (opioid-induced respiratory depression). Therefore, alternative pain control strategies in rib fracture patients have been a topic of increasing interest in recent literature [3]. However, many of these therapies are invasive, cost

prohibitive, or marginally effective [4-6].

Ketamine is an intravenous (IV) anesthetic with analgesic, sedative, and dissociative properties that primarily exerts its effect via N-methyl-D-aspartate receptor antagonism. In contrast to most traditional analgesics, ketamine promotes respiratory drive, stimulates the cardiovascular system, and increases muscle tone [7]. Ketamine has been established as an analgesic alternative or adjunct in several patient populations. Of note, several recent randomized controlled trials and other studies examining pain control in the post-operative period have shown that adding peri-operative ketamine results in lower opioid consumption while maintaining adequate analgesic effect [8-10]. Thus, the potential benefit in the setting of rib fracture is multifactorial, including efficacy against a variety of pain etiologies, avoidance or opposition of opioid and NSAID adverse effects, noninvasive nature of therapy, and relatively low financial burden for the patient and institution [11,12].

To the authors' knowledge, no peer-reviewed literature describes the efficacy of ketamine in rib fracture-associated pain. This gap in the literature is highlighted due to the potential benefits listed above. Accordingly, we describe three patients in our institution that received ketamine infusions as part of their pain control strategy in the setting of rib fracture. The aims of this case series were to determine if ketamine reduced the total opioid requirement and whether pulmonary complications were effectively avoided in these patients.

Case Report

Patient 1

A male (age 57, 111 kg) was admitted with respiratory distress after falling from his bicycle. Injuries included a moderately-sized left pneumothorax with some lung contusion noted by imaging, four lateral left rib fractures (#3-6), left comminuted scapula fracture, localized hematoma

in the left side of the pelvis without fracture, and scalp laceration. No peritoneal damage was noted. He was intubated at an outside facility for respiratory distress and transported to our facility via fixed wing aircraft at approximately 2100 (hospital day 0). The revised trauma score upon admission was 4. Past medical history was significant for Factor V Leiden thrombophilia treated with oral warfarin.

During hospital day 1, the patient was sedated with propofol to a Richmond Agitation Sedation Scale score -3, and intravenous (IV) fentanyl was available as needed for pain score of >3. Following extubation at 1300, morphine IV for severe pain was ordered, and total opioid use on day 1 was 102 oral morphine milligram equivalents (MME). On day 2, the patient reported a pain score 6/10, and ketamine was initiated at 1 µg/kg/min (range received 1-5 µg/kg/min) to minimize opioid reliance along with scheduled acetaminophen. Ketamine was titrated to a pain score < 3 while patient awake and alert. Average 8-hour analog pain scores decreased from 5 to 4 in the next 24 hours (between days 1 and 2) with concurrent reduction in daily opioid requirement from 36 to 0 MME (Table 1, Figure 1).

Ketamine was discontinued on day 5 after 72 hours. No hypersalivation or dissociative adverse effects were noted. The patient transitioned to morphine PCA and oxycodone 5-10 mg by mouth every 4 hours for severe pain. Average daily pain scores increased from 3 to 5 between days 5 and 7 (Figure 1). The patient developed constipation with no bowel movement for 4 days despite treatment with magnesium citrate, bisacodyl suppositories, lactulose, and polyethylene glycol. On hospital day 11, the patient was discharged to a skilled nursing facility.

Patient 2

A male (age 65, 70 kg) presented to the emergency department (ED) after mechanical fall while intoxicated. Imaging revealed three rib fractures: left anterior 3rd rib and left lateral ribs #5-6. Aside

Table 1. Daily range of ketamine infusion rate, opioid requirement, and average 8-hour analog pain scores

	Day -1	Day 0 ^a	Day +1	Day +2	Day +3	Day +4
Patient 1						
Ketamine Range, µg/kg/min	-	1-2	2-5	2-3	1-2	-
Opioid Requirement, MME ^b	102	36	0	0	40.5	61.5
Average 8-Hour Analog Pain Score ^c	4, 4	6, 5, 3	4, 4, 4	4, 4, 3	4, 3, 3	4, 2, 6
Patient 2						
Ketamine Range, µg/kg/min	0	5	7.5-10	5-7.5	2.5	-
Opioid Requirement, MME	29	149.1	137.7	117	94.5	60
Average 8-Hour Analog Pain Score	7	5, 6, 6	5, 4, 4	4, 5, 5	5, 4, 3	3, 3, 4
Patient 3						
Ketamine Range, µg/kg/min	-	5	2.5-5	2.5	-	-
Opioid Requirement, MME	123	205.8	126 ^d	178	136	212.5
Average 8-Hour Analog Pain Score	10, 8	5, 2, 1	5, 3, 1	3, 3, 4	4, 3, 5	6, 7, 8

^aDay 0 indicates day of ketamine infusion initiation; ^bMilligrams oral morphine equivalents; ^cRated on a scale of 0-10. If a patient did not have a pain score for a given 8 hour period (00:00-07:59, 08:00-15:59, 16:00-23:59), the pain score immediately preceding the time period and the pain score immediately following the time period were averaged; ^dThe patient also received 125 MME during a surgical procedure in addition to the opioid requirement listed above

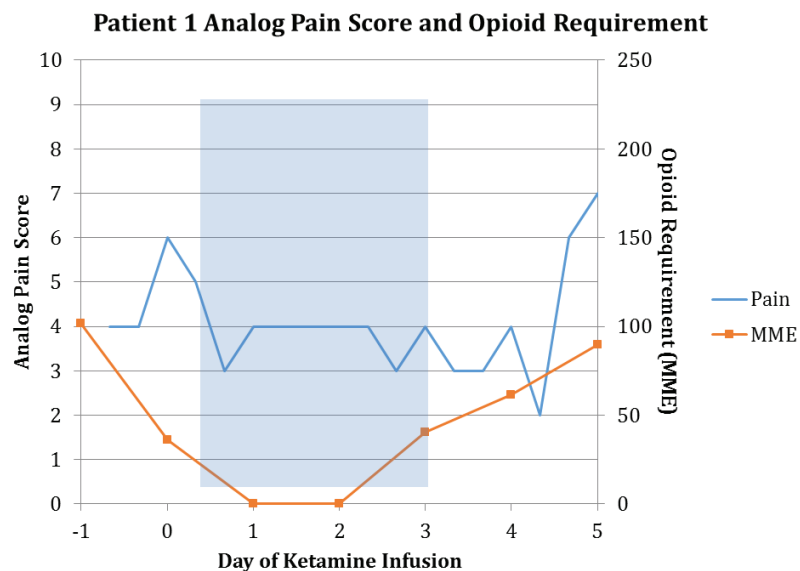


Fig. 1. Analog pain score and opioid requirement in oral morphine milligram equivalents (MME) of patient 1. Shaded area represents duration of ketamine infusion.

from scattered bruising and two partial thickness abrasions on the left elbow, no other injuries were noted. Revised trauma score on admission was 8. Past medical history was significant for stroke, anxiety, depression, alcohol abuse, and history of Wernicke's encephalopathy. Home medications included oral aspirin, extended release bupropion, and naproxen.

Morphine 8 mg IV one time and hydromorphone IV 0.25 mg every 2 hours for severe pain were ordered upon admission. For 24 hours, analog pain scores ranged between 5 and 7. On hospital day 1, the patient was initiated on morphine PCA, ketorolac IV 15 mg every 6 hours, and acetaminophen four times daily. The patient continued rating pain at 10/10 with movement and coughing. Ketamine was initiated at 5 $\mu\text{g}/\text{kg}/\text{min}$ (range received 2.5-10 $\mu\text{g}/\text{kg}/\text{min}$) and

titrated to analgesia augmentation. Average daily pain score decreased from 5.7 to 4.7 between hospital days 1 and 3, while opioid requirements decreased from 149 to 117 MME (Table 1, Figure 2).

On hospital day 2, the patient described feeling "high and drunk" but remained orientated to person and place. Ketamine was reduced from 10 to 7.5 $\mu\text{g}/\text{kg}/\text{min}$, and the patient was alert and oriented times 3 on day 3. On day 4, the patient reported poor sleep overnight due to "seeing things," after which ketamine and morphine PCA were discontinued. The total ketamine duration was 68 hours, and no medications were prescribed to attenuate the dissociative adverse effects.

No hypersalivation or constipation was noted during or following ketamine administration. Pain scores remained between 2 and 4 for the

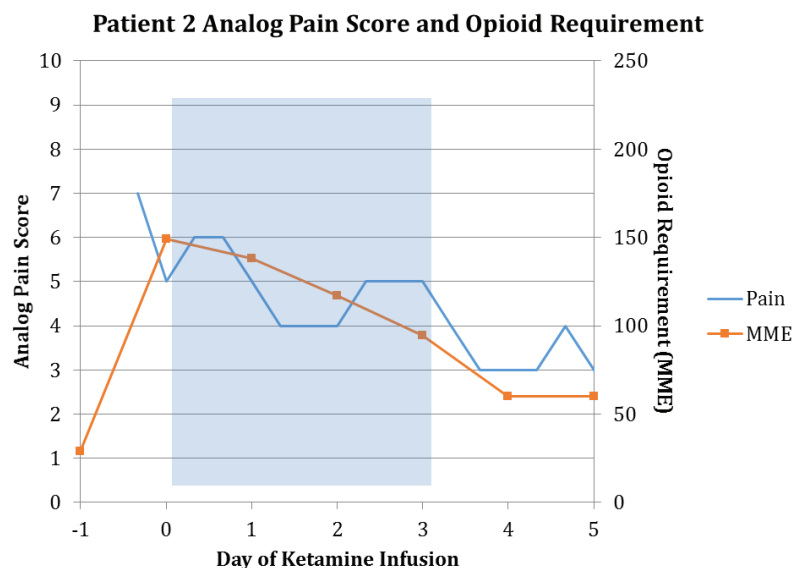


Fig. 2. Analog pain score and opioid requirement in oral morphine milligram equivalents (MME) of patient 2. Shaded area represents duration of ketamine infusion.

remainder of hospitalization with a daily lidocaine 5% transdermal patch and oral methocarbamol, acetaminophen, tramadol, and oxycodone. The patient was discharged home on hospital day 8.

Patient 3

A female (age 29, 115 kg) was admitted directly from an outside hospital following a motor vehicle rollover accident. Her injuries included displaced left clavicle fracture, twelve rib fractures (T1-3 bilateral posterior, left T4 proximal, T6 anterior superior endplate and bilateral, right T7 posterior, T7 superior endplate, left T11-12 proximal), multiple thoracic and lumbar transverse process fractures, T5 burst compression fracture with kyphotic deformity, T6-7 vertebral compression fractures, small bilateral pneumothoraxes, bilateral comminuted scapular fractures, and grade 2 splenic injury. Patchy air space with right lung contusions was noted in addition to mild abrasions on the patient's chest and back with no peritoneal damage. Revised trauma score on admission was 8. Past medical history was significant for major depressive disorder treated with oral extended-release venlafaxine.

After the patient required 35 mg of IV morphine PCA over the initial 16 hours, oxygen requirements increased from 2 to 10 L/min via nasal cannula, and heart rate increased to 140 beats per minute. Ketamine was subsequently initiated at 5 µg/kg/min (range received 2.5-5 µg/kg/min), and PCA changed to hydromorphone. On hospital day 2, the patient underwent surgical stabilization of the burst fracture, receiving fentanyl IV 350 µg and hydromorphone IV 1 mg during surgery. On day 3, oxygen requirements decreased from 10 to 4 L/min. Ketamine was discontinued after 49 hours, and she was transferred to the general floor. During the ketamine infusion, daily opioid requirements decreased from 205.8 to 178 MME with no change

in average daily pain score (Table 1, Figure 3).

On day 4, patient experienced increased pain with movement, and scheduled cyclobenzaprine was ordered. Oxycodone 10 mg by mouth every 4 hours was added on day 5, along with her home dose of venlafaxine. Average daily pain score increased from 3 to 7 between days 3 and 5. On day 6, sustained-release morphine 15 mg by mouth twice daily and scheduled acetaminophen were ordered, while PCA was discontinued. The patient underwent a surgical clavicle repair on day 8. She no longer required supplemental oxygen on day 12. Morphine was increased to 15 mg by mouth three times daily on day 9 along with oral oxycodone until patient discharged to a skilled nursing facility on hospital day 14.

No hypersalivation or dissociative adverse events were noted. She reported constipation on days 5, 8, 9, and 13 treated with bisacodyl suppositories. Itching was observed periodically throughout hospitalization and postulated by the medical team to be opioid-induced.

Discussion

Each of the three patients presented after a traumatic injury with at least one rib fracture. One patient received the ketamine infusion starting on day 0 in anticipation of difficult pain control, and two patients were initiated later in their hospital course. The ketamine protocol utilized at our facility is defined in Table 2. The average length of ketamine infusion was 63 hours (range 49-72 hours), and the average hospital length of stay was 12 days (range 9-15 days).

Each patient demonstrated a trend toward reduced opioid requirements and stable pain scores, as illustrated in Figures 1-3. The reduced opioid requirement is of specific interest in this population as we seek to minimize respiratory depression and other pharmacologic adverse effects while

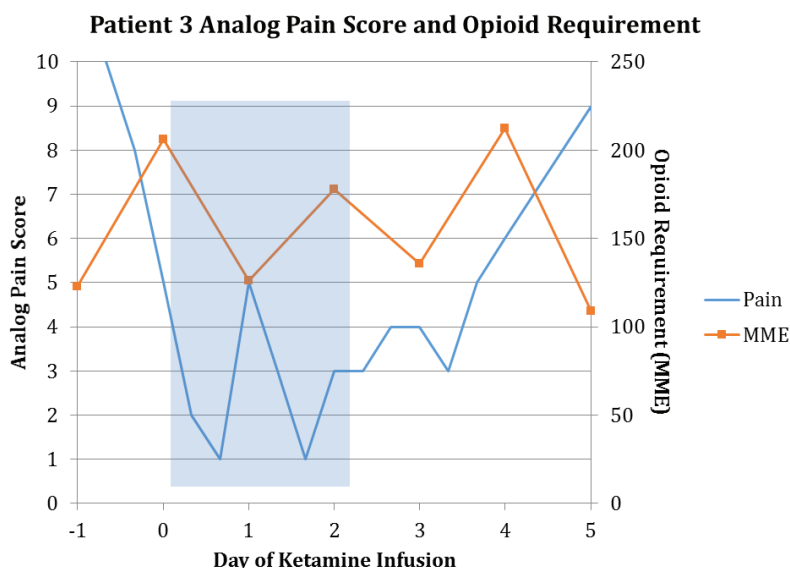


Fig. 3. Analog pain score and opioid requirement in oral morphine milligram equivalents (MME) of patient 3. Shaded area represents duration of ketamine infusion.

Table 2. Ketamine Infusion Protocol

Dosing	
Initiation	1-5 µg/kg/min
Range	1-10 µg/kg/min
Titration Parameters	
<ul style="list-style-type: none"> • Increase rate by 2.5 µg/kg/min every 30 minutes if goal pain score not achieved • Decrease rate by 2.5 µg/kg/min every hour if RASS^a less than goal or if weaning desired 	
Monitoring Parameter and Interval	
Pulse Oximetry	Continuous
Incentive Spirometry, Pain	Hourly
Total PCA ^b Dose	Every 8 Hours

^aRichmond Agitation Sedation Scale; ^bPatient Controlled Analgesia

still providing adequate pain control to facilitate therapeutic goals.

Furthermore, the lack of pulmonary complications observed is an encouraging correlation. Of note, patient 3 exhibited increasing oxygen dependency shortly after admission, which contributed to the decision to initiate ketamine infusion. Ketamine was discontinued after the oxygen requirements decreased. No further pulmonary complications as defined by emergent intubation or pneumonia diagnoses were observed. Only one patient was intubated after admission, and only to facilitate a surgical procedure. Of note, although these observations are valuable, one must use caution in interpreting this information as the complexity of the injuries described above makes it difficult to generalize our findings to patients with isolated rib fracture.

Patient 2 experienced a dissociative adverse effect that prompted a decrease in rate and subsequent discontinuation of ketamine. He did not receive treatment for the psychomimetic reaction, nor were

additional therapies or testing prescribed in response to the reaction. However, mitigation of emergence reactions or hallucinations with benzodiazepines have been observed in previous studies and reviews [7,13].

In this case series, we report our experience of three patients managed with ketamine infusions as an adjunct pain control strategy for rib fracture in the setting of multi-trauma. The decreased opioid requirement and lack of pulmonary complications are encouraging in this uniquely vulnerable population. Although the authors note that the trends observed in MME and pain score may be attributed to multiple factors including the confounding effect of other traumatic injuries, we believe ketamine infusions to be a valid addition to the repertoire of pain control strategies for patients with rib fracture. A randomized controlled trial is currently active and may eventually clarify the role of ketamine infusions in this population [14].

Conflict of Interest: None declared.

References

- Lin FC, Tsai SC, Li RY, Chen HC, Tung YW, Chou MC. Factors associated with intensive care unit admission in patients with traumatic thoracic injury. *J Int Med Res.* 2013;**41**(4):1310-7.
- Sirmali M, Turut H, Topcu S, Gulhan E, Yazici U, Kaya S, et al. A comprehensive analysis of traumatic rib fractures: morbidity, mortality and management. *Eur J Cardiothorac Surg.* 2003;**24**(1):133-8.
- Paydar S, Farhadi P, Ghaffarpasand F, Taheri A, Farbood A, Dabiri G, et al. Acute trauma pain control algorithm. *Bull Emerg Trauma.* 2014;**2**(4):170-1.
- Elvir-Lazo OL, White PF. The role of multimodal analgesia in pain management after ambulatory surgery. *Curr Opin Anaesthesiol.* 2010;**23**(6):697-703.
- Ilfeld BM, Enneking FK. Continuous peripheral nerve blocks at home: a review. *Anesth Analg.* 2005;**100**(6):1822-33.
- Truitt MS, Mooty RC, Amos J, Lorenzo M, Mangram A, Dunn E. Out with the old, in with the new: a novel approach to treating pain associated with rib fractures. *World J Surg.* 2010;**34**(10):2359-62.
- Craven R. Ketamine. *Anaesthesia.* 2007;**62** Suppl 1:48-53.
- Gelir IK, Gulec S, Ceyhan D. Preventive effect of dexketoprofen on postoperative pain. *Agri.* 2016;**28**(2):67-71.
- Wang L, Johnston B, Kaushal A, Cheng D, Zhu F, Martin J. Ketamine added to morphine or hydromorphone patient-controlled analgesia for acute postoperative pain in adults: a systematic review and meta-analysis of randomized trials. *Can J Anaesth.* 2016;**63**(3):311-25.
- Siddiqui KM, Khan FA. Effect of preinduction low-dose ketamine bolus on intra operative and immediate postoperative analgesia requirement in day care surgery: A randomized controlled trial. *Saudi journal of anaesthesia.* 2015;**9**(4):422.
- Ho AM, Karmakar MK, Critchley LA. Acute pain management of patients with multiple fractured ribs: a focus on regional techniques. *Curr Opin Crit Care.* 2011;**17**(4):323-7.
- Persson J. Ketamine in pain management. *CNS Neurosci Ther.* 2013;**19**(6):396-402.
- Chudnofsky CR, Weber JE, Stoyanoff PJ, Colone PD, Wilkerson MD, Hallinen DL, et al. A combination of midazolam and ketamine for procedural sedation and analgesia in adult emergency department patients. *Acad Emerg Med.* 2000;**7**(3):228-35.
- Kugler N. Ketamine infusion therapy for the management of acute pain in adult rib fracture patients. In: ClinicalTrials.gov [Internet]. Bethesda (MD): National Library of Medicine (US). 2000-[cited 2016 Apr 19]. Available from: <http://clinicaltrials.gov/ct2/show/NCT02432456?term=ketamine+rib&rank=1>. NLM identifier: NCT02432456.