



## Effects of Platelet Rich Plasma on Healing Rate of Long Bone Non-union Fractures: A Randomized Double-Blind Placebo Controlled Clinical Trial

Fariborz Ghaffarpasand<sup>1</sup>, Mostafa Shahrezaei<sup>2</sup>, Maryam Dehghankhalili<sup>3\*</sup>

<sup>1</sup>Department of Neurosurgery, Shiraz University of Medical Sciences, Shiraz, Iran

<sup>2</sup>Department of Orthopedic Surgery, AJA University of Medical Sciences, Tehran, Iran

<sup>3</sup>Health Policy Research Center, Shiraz University of Medical Sciences, Shiraz, Iran

\*Corresponding author: Maryam Dehghankhalili

Address: Health Policy Research Center, Shiraz University of Medical Sciences, Shiraz, Iran. Tel/Fax: +98-713-6254206; Cellphone: +98-936-9799535  
e-mail: maryam\_dhkh@yahoo.com

Received: April 13, 2016

Revised: June 6, 2016

Accepted: June 14, 2016

### ► ABSTRACT

**Objective:** To determine the effects of platelet rich plasma PRP on healing rates of long bone non-union fracture.

**Method:** This was a randomized double-blind placebo controlled clinical trial being performed in a 12-month period. We included 75 adult (>18 years) patients suffering from long bone (Femur, Tibia, Humerus and Ulna) non-union fracture who were randomly assigned to receive 5mL PRP (n=37) or 5mL normal saline as placebo (n=38) in the site of fracture after intramedullary nailing or open reduction and internal fixation (ORIF) along with autologous bone graft. Patients were followed each 45 days till 9 months and were evaluated both clinically and radiologically in each visit. The healing rate, failure rate, incidence of infection, mal-union and limb shortening were recorded and compared between groups after 9 months of follow-up.

**Results:** The healing rate was significantly higher in PRP group compared to placebo (81.1% vs. 55.3%;  $p=0.025$ ). The limb shortening was significantly higher in those who received placebo ( $2.61\pm 1.5$  vs.  $1.88\pm 1.2$ mm;  $p=0.030$ ). Injection of PRP was also associated with lower pain scores ( $p=0.003$ ) and shorter healing duration ( $p=0.046$ ). The surgical site infection ( $p=0.262$ ) and mal-union rate ( $p=0.736$ ) were comparable between groups.

**Conclusion:** Application of PRP along with autologous bone graft in the site of non-union of long bone after intramedullary nailing or ORIF results in higher cure rate, shorter healing duration, lower limb shortening and less postoperative pain. Higher infection rate might be a complication of PRP application.

**Clinical Trial Registry:** This trial is registered with the Iranian Clinical Trials Registry (IRCT201208262445N1; www.irct.ir).

**Keywords:** Non-union; Long bone fracture; Platelet rich plasma (PRP); Intramedullary nailing; Open reduction and internal fixation (ORIF).

Please cite this paper as:

Ghaffarpasand F, Shahrezaei M, Dehghankhalili M. Effects of Platelet Rich Plasma on Healing Rate of Long Bone Non-union Fractures: A Randomized Double-Blind Placebo Controlled Clinical Trial. *Bull Emerg Trauma*. 2016;4(3):134-140.

## Introduction

Non-union of long bones is among the most devastating complications of traumatic fractures and the treatment still remains a dilemma to physicians and orthopedic surgeons [1]. The incidence of traumatic non-union fractures of humerus, femur and tibia is approximately 2-6%, 2-8% and 3-6.4% respectively [2]. Despite several introduced methods for treatment of non-union of long bones, it remains an unsolved problem [1]. These fractures impose the healthcare system to tremendous economic burden, as it was reported that mean expense for treatment of non-union of humerus, femur and tibia is 31132, 34400 and 32660 USD, respectively [1]. Prevention of non-union fracture is considered the best method of their management. This could be achieved by aligning the fracture site using internal or external fixators [3]. Debridement of necrotic and infectious tissue and aligning fracture site along with intramedullary nailing has also been successfully implicated [4]. Despite these surgical techniques, non-union occurs in a proportion of patients. Thus several alternative treatment modalities have been introduced with conflicting results including application of electromagnetic fields [5], biodegradable implants [6], recombinant bone morphogenetic protein 7 (rhBMP-7) [7] and platelet rich plasma (PRP) [8,9].

PRP is an autologous blood product with high activated platelet concentrations (approximately 1 million per each micro-liters) containing platelet derived growth factor (PDGF), vascular endothelial growth factor (VEGF), epidermal growth factor (EGF), fibroblast growth factor (FGF) and transforming growth factor (TGF- $\beta$ 1, TGF- $\beta$ 2) which are responsible for repair and granulation tissue formation in the human body [10]. PRP has been successfully used in treatment of musculoskeletal injuries [11,12]. Several studies have investigated the role of local PRP application in treatment of non-union fractures with conflicting results [9,13-16]. Although some studies have shown that PRP increases the healing rate of the non-union fractures in animal models [13,14] and human subjects [15,16], some others found that PRP poses no advantage over placebo or rhBMP-7 [17,18]. A recent meta-analysis indicated that there is lack of standard randomized clinical trials to shed light on effectiveness of PRP application on healing rate of non-union of long bones [19]. Thus the aim of this study was to determine the effects of PRP application on healing rates of long bone non-union fracture.

## Materials and Methods

### Study Population

This was prospective randomized double-blind placebo controlled trial being performed in Shahid Rajaei trauma center (our level I trauma center)

affiliated with Shiraz University of Medical Sciences during a 17-months period (from May 2011 to October 2012). The study protocol was approved by both institutional review board (IRB) and ethics committee of AJA University of Medical Sciences and all the participants gave their informed written consents. The trial was registered with the Iranian Clinical Trials Registry (IRCT201208262445N1; www.irct.ir). We included 79 adult patients (>18 years) suffering from long bone non-union fractures (Femur, Tibia, Humerus, Ulna) with duration of more than 6 months [20]. Those less than 18 years of age, infectious non-unions, vascular injuries, large skin defects of fracture site, musculoskeletal disorders, malignancies, pathological fractures (tumors, metabolic osteopenia), active autoimmune disorders and large bone defects were excluded from the study. We also excluded those patients with thrombocytopenia (platelet count less than 100,000 per micro-liter) and thrombocytosis (platelet count less than 650,000 per micro-liter), those who had received treatment with growth factors, steroids and NSAIDs during the previous year.

### Randomization and Intervention

Those who entered the study (n=75) were randomly assigned to two study groups based on their registration numbers using a computer-based random digit generator. Those assigned to PRP group (n=37) received 5mL PRP and the others received 5mL of normal saline as placebo (n=38) in the site of fracture after intramedullary nailing or open reduction and internal fixation (ORIF).

### Study Protocol and Measurements

All the included patients underwent a complete history and physical examination one day before operation and the demographic information (age, sex) as well as clinical characteristics (fracture site, injury mechanism, number of previous operations, type of operation, duration of non-union) were recorded. We also withdrew 5mL venous blood to measure the blood indices including hemoglobin (Hb) and platelet count.

Autologous PRP was prepared using Gravitational Platelet Separation System (GPS<sup>®</sup> III; BIOMET, Warsaw, Indiana, USA) according to manufacturer's protocol and that previously described [21]. Briefly, 54mL venous blood was withdrawn from the right cubital vein at the time of operation using acid-citrate-dextrose containing GPS<sup>®</sup> III tubes in PRP group. The tubes were centrifuged immediately for 15 min on 3200 rpm in order to separate red blood cells (RBCs) from platelets and plasma. Approximately 5–6mL of PRP was obtained after removing platelet poor plasma (PPP) and was transferred to dark syringes. The platelet concentration of the PRP was approximately 4.2–4.8 times higher than native blood compared to the baseline platelet count.

All the patients underwent general anesthesia

using standard protocol. As prophylaxis, 1 gram Cefazolin was injected just before the operation and low-molecular weight heparin was given as deep vein thrombosis (DVT) prophylaxis after the operation. All the operations were performed by two orthopedic surgeons and the surgical technique was chosen according to clinical decision and expertise. Under general anesthesia, all previous metal implants (whenever present) were removed and the ends of non-union fracture were decorticated. For the femoral fractures, the reaming of the canal was conserved and intramedullary nailing was performed. Anterograde approach was used for inserting the stainless steel core shaft fixation nail. For fractures of humerus, ulna and tibia, ORIF using stainless steel plates and screws were used. All necrotic tissues were debrided and bacterial cultures were obtained from the fracture site. Autologous bone graft using iliac crest was performed in all the patients according to standard techniques. A membrane was formed using the muscular fascia and the PRP or placebo was injected around the fracture site, in the periosteum. The surgeons were blinded toward the content of the syringes which were handed to them by the assistant.

The patients were discharged from the hospital after 48 hours of uneventful hospital course and were instructed to follow rehabilitation programs to minimize the risk of pseudoarthrosis. The rehabilitation started after 24 hours of operation and the patients with femoral or tibial fractures were allowed to partial weight bearing after 4 weeks. The patients with humeral or ulnar non-union were immobilized in a plaster cast for 3 weeks before starting rehabilitation. Patients were followed each 45 days up to 270 days (9 months) in daytime clinics. They were evaluated both clinically and radiologically (anteroposterior and lateral views) in each visit and the pain was measured using a manual version of visual analogue scale (VAS) from 1 to 10. Clinical union was defined as pain-free full-weight bearing for lower extremity fracture non-unions, and pain-free movement for fracture non-unions of the upper extremity. Radiological union was defined as the presence of bridging callus on at least 3/4 cortices on the AP and lateral radiographic views. Failure of treatment was defined as absence of clinical and radiological union after 9 months of operation [20]. The limb length was also measured in each visit and was compared with preoperative length. Limb shortening >4mm was recorded. The incidence of postoperative infections, malunion and non-union was also recorded and compared between groups. All the patients and those visiting the patients postoperatively were blind to the study groups. Only the statisticians were aware of the study groups.

#### Statistical Analysis

In order to have 90% power to detect 5% difference between clinical healing rates of non-union fractures

with  $\alpha$  equal to 0.01 and assumed coefficient as 1.96, we required 32 patients in each study group. To compensate for possible non-evaluable patients and those who would possibly exit the study, we enrolled 79 participants. The Statistical Package for Social Science, SPSS for Windows, version 16.0 (SPSS, Chicago, IL) was used for data analysis. Paired t-tests were used to compare results within groups; independent t-tests were used to compare results between the groups; chi-square or Fisher's exact tests were used to compare proportions and categorical variables. Data are reported as means $\pm$ SD. A two-sided *p*-value less than 0.05 was considered statistically significant.

#### Results

A total number of 79 patients were found eligible for the study out of whom, 4 did not accepted to participate in the study. Thus the final number of patients included in the study was 75 and all the participants finished the study (Figure 1). There was no significant difference between two study groups regarding the baseline characteristics (Table 1). Femur was the most common site of non-union fracture accounting for 46.6% of all cases.

Table 2 summarizes the main outcomes of the study. Those who received PRP during the operation had significantly higher healing rate compared to placebo group (81.1% vs. 55.3%;  $p=0.025$ ). They also had shorter admission (6.6 $\pm$ 1.3 vs. 7.7 $\pm$ 1.4 days;  $p<0.001$ ) and healing duration (8.1 $\pm$ 1.2 vs. 8.5 $\pm$ 0.7 months;  $p=0.003$ ) compared to placebo group. This was consistent in upper and lower extremities separately (Table 2). Although postoperative infection rate was higher in PRP group (13.5% vs. 5.3%), this difference did not reach statistical significance ( $p=0.062$ ). Mal-union incidence was also comparable between groups (10.8% vs. 15.8%;  $p=0.136$ ). Limb shortening was also lower in PRP group compared to placebo ( $p=0.030$ ). The postoperative pain was significantly lower in PRP group compared to placebo group in days 45 ( $p=0.014$ ) and 90 ( $p<0.001$ ) while it was comparable on the other follow-up visits (Table 2).

#### Discussion

In the current study we determine the effectiveness of PRP application along with autologous iliac crest bone grafting for treatment of long bone non-union fracture through a randomized placebo controlled clinical trial. We found that application of PRP increased the cure rate significantly. It was also associated with lower healing duration, lower limb shortening and less postoperative pain. The results of this study clearly demonstrate that application of PRP in addition to autologous bone graft is a logical approach for treatment of long bone non-union fracture. To the best of our knowledge, this is among the only standard randomized clinical trial addressing

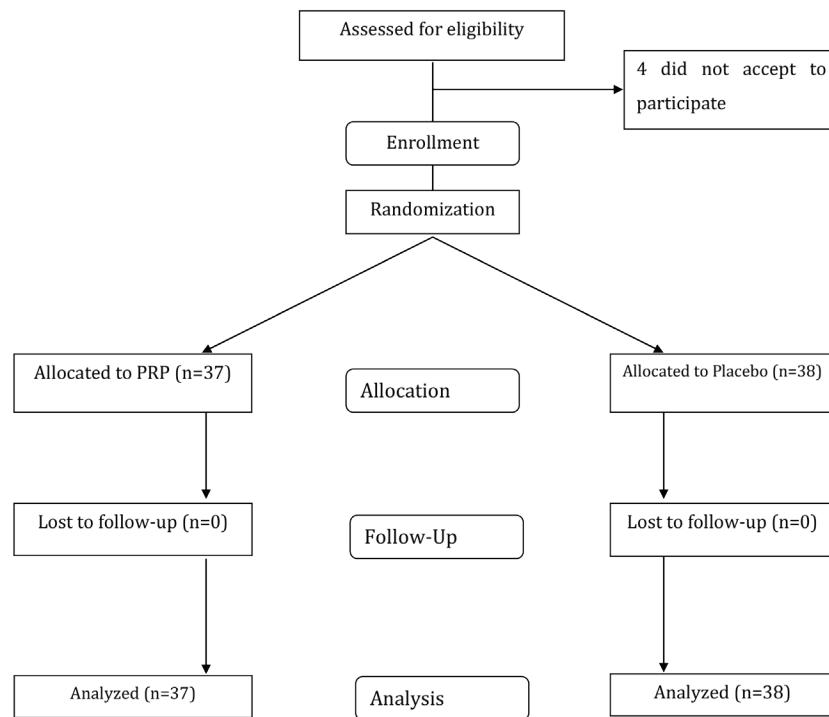


Fig. 1. CONSORT flow diagram of the study.

Table 1. Baseline characteristics of 75 patients with non-union fractures of long bones who received platelet rich plasma (PRP) or placebo

	PRP (n=37)	Placebo (n=38)	p value
<b>Age (years)</b>	26.5±5.8	26.3±6.2	0.918
<b>Sex</b>			
Man (%)	31 (83.8%)	33 (86.6%)	0.754
Women (%)	6 (16.2%)	5 (13.2%)	
<b>Fracture site</b>			
Femur (%)	16 (43.2%)	19 (50.0%)	0.844
Tibia (%)	14 (37.8%)	12 (31.6%)	
Humerus (%)	6 (16.3%)	5 (13.2%)	
Ulna (%)	1 (2.7%)	2 (5.3%)	
<b>Non-union type</b>			
Hypertrophic (%)	23 (62.1%)	25 (65.7%)	0.065
Oligotrophic (%)	9 (24.4%)	11 (28.9%)	
Atrophic (%)	5 (13.5%)	2 (5.4%)	
<b>Injury mechanism</b>			
Motorcycle (%)	12 (32.4%)	9 (3.7%)	0.519
Car crash (%)	6 (16.3%)	8 (21.1%)	
Pedestrian (%)	8 (21.6%)	13 (34.2%)	
Falling down (%)	9 (24.3%)	5 (13.1%)	
Assault trauma (%)	2 (5.4%)	3 (7.9%)	
<b>No. previous operation</b>			
One (%)	13 (35.1%)	16 (42.1%)	0.291
Two (%)	17 (45.9%)	11 (28.9%)	
Three (%)	7 (18.9%)	11 (28.9%)	
<b>Operation type</b>			
IM <sup>a</sup> nailing (%)	16 (43.2%)	19 (50.0%)	
ORIF <sup>b</sup> (%)	21 (56.8%)	19 (50.0%)	
<b>Non-union (months)</b>	18.1±3.1	18.7±3.4	0.373
<b>Operation time (min)</b>	53.2±9.8	52.5±12.1	0.812
<b>PRP volume (cc)</b>	5.5±0.5	5.6±0.6	0.929
<b>Preoperative Hb<sup>c</sup> (mg/dL)</b>	13.5±1.8	13.1±2.3	0.412
<b>Preoperative platelet count (×10<sup>6</sup>/μL)</b>	2.1±0.6	2.2±0.8	0.823
<b>PRP platelet count<sup>d</sup> (×10<sup>6</sup>/μL)</b>	9.3±2.6	—	—

<sup>a</sup>IM: Intramedullary; <sup>b</sup>ORIF: Open Reduction and Internal Fixation; <sup>c</sup>Hb: Hemoglobin; <sup>d</sup>PRP: Platelet Rich Plasma

**Table 2.** Treatment outcomes of 75 patients with non-union fractures of long bones who received platelet rich plasma (PRP) or placebo

	PRP <sup>a</sup> (n=37)	Placebo (n=38)	p value
<b>Treatment outcome</b>			
Complete healing (%)	30 (81.1%)	21 (55.3%)	0.025
Failure (%)	7 (18.9%)	17 (44.7%)	
<b>Admission duration (days)</b>	6.6±1.3	7.7±1.4	0.001
<b>Healing duration (months)</b>	8.1±1.2	8.5±0.7	0.003
Upper extremity (months)	7.9±0.6	8.4±1.3	0.002
Lower extremity (months)	8.4±1.3	8.8±2.1	0.032
<b>Infection complications (%)</b>	5 (13.5%)	2 (5.3%)	0.062
<b>Revision for infection (%)</b>	2 (5.4%)	1 (2.6%)	0.215
<b>Mal-union (%)</b>	4 (10.8%)	6 (15.8%)	0.136
<b>Limb shortening (mm)</b>	1.8±1.2	2.6±1.5	0.030
>4mm (%)	3 (8.1%)	5 (13.2%)	0.711
<4mm (%)	34 (91.9%)	33 (86.6%)	
<b>Postoperative pain</b>			
Day 45	2.8±1.4	3.5±1.3	0.014
Day 90	2.1±1.2	3.1±1.2	<0.001
Day 135	1.6±0.7	2.3±1.1	0.004
Day 180	1.4±0.7	1.7±0.7	0.142
Day 225	1.2±0.5	1.3±0.5	0.378
Day 270	1.1±0.3	1.1±0.3	0.969

<sup>a</sup>PRP: Platelet Rich Plasma

this issue. Recently Malhotra *et al.*, [22] used PRP for treatment of 94 patients with established nonunion of long bones. The fracture union was evaluated clinically and radiologically regularly at monthly interval till 4 months. Eighty-two patients had their fracture united at the end of 4 months. Thirty-four patients showed bridging trabeculae on X-rays at the end of 2 months, while 41 patients showed bridging trabeculae at the end of third month. Twelve patients did not show any attempt of union at 4 months and were labeled as failure of treatment [22]. In another recent study, Memeo *et al.*, [23] used PRP to treat 7 patients with forearm post-traumatic non-union that were previously treated in different ways. All patients in the study showed complete recovery, with excellent clinical outcomes [23]. Samy [24] compared the results of femur neck non-union treatment between those who received PRP and those who did not along with internal fixation. He reported that cure rate was higher and healing time was lower in PRP group supporting our results. However, Say *et al.*, [25] did not observe adequate healing in the treatment of lower extremity non-union fracture with PRP injection. Taking all these together, along with our results, this could be emphasized that PRP application would be beneficial in treatment of long bone fractures.

Several animal studies have used PRP for treatment of bone defects and non-unions [13,14]. Hakimi and co-workers [13] demonstrated that PRP combined with autologous cancellous bone leads to a significantly better bone regeneration compared to isolated application of autologous cancellous bone in an in vivo critical size defect on load-bearing long bones of mini-pigs during a time period of 6 weeks.

Gerard and colleagues [26] also studied the effects of PRP on healing rate of maxillary non-unions in animal model of dog. They demonstrated that PRP enhances the early healing rate of autologous bone grafts in maxillary bone. However the PRP healing rate enhancement was not found significant after 2 months. This could be explained due to the fact that PRP enhances the removal of non-viable grafted autologous bones, but does not affect the regeneration and formation of new bone. Thus PRP has been concluded to affect the early healing rate. They also demonstrate that PRP administration does not increase the trabecular density in the bone grafts. We also observed that the postoperative pain was significantly lower in those who received PRP only in early phase but was comparable in late phase of treatment. The discrepancy between our study and that of Gerard *et al.*, [26] could be explained due to site of non-union. We studied the effects of PRP on healing rate of long bones while they determined its effects on maxillary bone. In consistent with our results, Kanthan and co-workers [9] found that application of PRP in combination with bone grafting improved the bone healing rate of rabbit tibial fractures when compared to bone graft alone. They also demonstrated that use of PRP alone (without bone grafting) does not affect the outcome and healing rate and provides limited advantage over placebo [9]. The result of this experimental study was further supported by a clinical study that reported the results of successful treatment of 17 patients with persistent non-union of long bones using combination of PRP and autologous bone grafting [16]. Galasso and colleagues [15] also used a combination of self-locking intramedullary nailing and PRP for

treatment of atrophic diaphyseal long bone non-unions. They reported a healing rate of 91% which is comparable with previous reports. However they did not applied autologous bone grafting. Recently it was demonstrated by Lee *et al.*, [27] that autologous bone marrow aspirate concentrate combined with PRP injection at the osteotomy site helped improve bone healing in distraction osteogenesis of the tibia, although the effect size was small. In contrast to our results, Aghaloo and co-workers [28] did not observe any additive effects of PRP and autologous bone grafting for treatment of bone defects of rabbit animal model. This could be explained due to the methodology of this single experimental study. The platelet concentration used in this study was 7.3 times higher than the native blood which is higher compared to other studies and ours [13-18].

Several studies have indicate that PRP healing process enhancement effect could be observed just in early stage while it diminishes in late stages of healing [13,16]. This is because the concentration of growth factors decreases over time resulting in decreased healing capacities. Actually, PRP enhances the removal of non-viable grafted autologous bones, but does not affect the regeneration and formation of new bone. Thus PRP has been concluded to affect the early healing rate. We also observed pain lower effects in early stage of the healing process (up to 12 weeks after operation). This finding could be explained due the fact that platelets life span is approximately 5 days when they are injected in the tissue. The overall infection rate was approximately high in our study when compared to the international literature (1.5-6%) [23-25]. This is because our center is a very populated trauma center with heavy operating room workload involving many residents and medical students. PRP was associated with higher postoperative injection rate although the difference was not statistically significant. This is consistent with previous reports [15,25]. Most of the postoperative infections were management conservatively with intravenous and oral antibiotics while only few (4%) required surgical intervention.

We note some limitations to our study. First, limited number of patients was included in our study which may result in low power of the study. This is because limited patients could fulfill the precise inclusion and exclusion criteria of our study. However the sample

size calculation and power assessments demonstrated that our study has the 90% power to detect the significant difference. Thus the results are reliable and could be interpreted clinically. The important point that should be considered is that this power is calculated for all the fracture non-unions together (Femur, Tibia, Humerus and Ulna). The power of the study for the femur and tibia fracture non-unions were 86% and 82% respectively. It would be more accurate to include only one fractures site with larger number of patients to obtain more accurate results. Second, we did not record and assess the expenses of both management protocols. This could enhance our knowledge of cost and benefit advantages of PRP over other available methods. However objectively, it is clear that PRP products are very available and inexpensive. One explanation for our inability to calculate the expenses was the high economical and health inflation rate during the study period probably secondary to international sanction on Iran. The other limitation was that we did not asked patients to measure their pain intensity according to the type of pain (localized pain, chronic pain, weight bearing pain, etc.). These patient experience different type of pains and we did not separate these types. Thus the measured VAS would be a summation of all pain types.

In conclusion, application of PRP along with autologous bone graft in the site of non-union of long bone after intramedullary nailing or ORIF results in higher cure rate, shorter healing duration, lower limb shortening and less postoperative pain. Higher infection rate might be a complication of PRP application.

### Acknowledgment

The authors would like to thank all the patients and their families who patiently participated in the study. We would also like to acknowledge the AJA University of Medical Sciences for providing the financial support for this project (Grant number: #690121). This manuscript is the results of the thesis of Dr. Fariborz Ghaffarpasand (First author) instead of the military service in accordance to Bonyad Melli Nokhbegan (BMN) regulations.

**Conflict of Interest:** None declared.

### References

1. Lynch JR, Taitsman LA, Barei DP, Nork SE. Femoral nonunion: risk factors and treatment options. *J Am Acad Orthop Surg.* 2008;**16**(2):88-97.
2. Tzioupis C, Giannoudis PV. Prevalence of long-bone non-unions. *Injury.* 2007;**38** Suppl 2:S3-9.
3. Santolini E, West R, Giannoudis PV. Risk factors for long bone fracture non-union: a stratification approach based on the level of the existing scientific evidence. *Injury.* 2015;**46** Suppl 8:S8-S19.
4. Megas P, Syggelos SA, Kontakis G, Giannakopoulos A, Skouteris G, Lambiris E, et al. Intramedullary nailing for the treatment of aseptic femoral shaft non-unions after plating failure: effectiveness and timing. *Injury.* 2009;**40**(7):732-7.
5. Griffin XL, Costa ML, Parsons N, Smith N. Electromagnetic field stimulation for treating delayed union or non-union of long bone fractures in adults. *Cochrane Database Syst Rev.* 2011;(4):CD008471.
6. Akmaz I, Kiral A, Pehlivan O, Mahirogullari M, Solakoglu C, Rodop O. Biodegradable implants in the treatment of scaphoid nonunions.

- Int Orthop.* 2004;**28**(5):261-6.
7. Calori GM, D'Avino M, Tagliabue L, Albisetti W, d'Imporzano M, Peretti G. An ongoing research for evaluation of treatment with BMPs or AGFs in long bone non-union: protocol description and preliminary results. *Injury.* 2006;**37** Suppl 3:S43-50.
  8. Brossi PM, Moreira JJ, Machado TS, Baccarin RY. Platelet-rich plasma in orthopedic therapy: a comparative systematic review of clinical and experimental data in equine and human musculoskeletal lesions. *BMC Vet Res.* 2015;**11**:98.
  9. Kanthan SR, Kavitha G, Addi S, Choon DS, Kamarul T. Platelet-rich plasma (PRP) enhances bone healing in non-united critical-sized defects: a preliminary study involving rabbit models. *Injury.* 2011;**42**(8):782-9.
  10. Roffi A, Filardo G, Kon E, Marcacci M. Does PRP enhance bone integration with grafts, graft substitutes, or implants? A systematic review. *BMC Musculoskelet Disord.* 2013;**14**:330.
  11. Abbasipour-Dalivand S, Mohammadi R, Mohammadi V. Effects of Local Administration of Platelet Rich Plasma on Functional Recovery after Bridging Sciatic Nerve Defect Using Silicone Rubber Chamber; An Experimental Study. *Bull Emerg Trauma.* 2015;**3**(1):1-7.
  12. Mohammadi R, Mehrtash M, Mehrtash M, Hassani N, Hassanpour A. Effect of Platelet Rich Plasma Combined with Chitosan Biodegradable Film on Full-Thickness Wound Healing in Rat Model. *Bull Emerg Trauma.* 2016;**4**(1):29-37.
  13. Hakimi M, Jungbluth P, Sager M, Betsch M, Herten M, Becker J, et al. Combined use of platelet-rich plasma and autologous bone grafts in the treatment of long bone defects in mini-pigs. *Injury.* 2010;**41**(7):717-23.
  14. Sun Y, Feng Y, Zhang CQ, Chen SB, Cheng XG. The regenerative effect of platelet-rich plasma on healing in large osteochondral defects. *Int Orthop.* 2010;**34**(4):589-97.
  15. Galasso O, Mariconda M, Romano G, Capuano N, Romano L, Ianno B, et al. Expandable intramedullary nailing and platelet rich plasma to treat long bone non-unions. *J Orthop Traumatol.* 2008;**9**(3):129-34.
  16. Hakimi M, Jungbluth P, Thelen S, Betsch M, Linhart W, Flohe S, et al. Platelet-rich plasma combined with autologous cancellous bone : An alternative therapy for persistent non-union?. *Unfallchirurg.* 2011;**114**(11):998-1006.
  17. Brogkini N, Hofstetter W, Hunziker E, Bosshardt DD, Bornstein MM, Seto I, et al. The influence of PRP on early bone formation in membrane protected defects. A histological and histomorphometric study in the rabbit calvaria. *Clin Implant Dent Relat Res.* 2011;**13**(1):1-12.
  18. Calori G, Tagliabue L, Gala L, d'Imporzano M, Peretti G, Albisetti W. Application of rhBMP-7 and platelet-rich plasma in the treatment of long bone non-unions: a prospective randomised clinical study on 120 patients. *Injury.* 2008;**39**(12):1391-402.
  19. Griffin XL, Wallace D, Parsons N, Costa ML. Platelet rich therapies for long bone healing in adults. *Cochrane Database Syst Rev.* 2012;**(7)**:CD009496.
  20. Frolke JP, Patka P. Definition and classification of fracture non-unions. *Injury.* 2007;**38** Suppl 2:S19-22.
  21. Eppley BL, Woodell JE, Higgins J. Platelet quantification and growth factor analysis from platelet-rich plasma: implications for wound healing. *Plast Reconstr Surg.* 2004;**114**(6):1502-8.
  22. Malhotra R, Kumar V, Garg B, Singh R, Jain V, Coshic P, et al. Role of autologous platelet-rich plasma in treatment of long-bone nonunions: a prospective study. *Musculoskelet Surg.* 2015;**99**(3):243-8.
  23. Memeo A, Verdoni F, De Bartolomeo O, Albisetti W, Pedretti L. A new way to treat forearm post-traumatic non-union in young patients with intramedullary nailing and platelet-rich plasma. *Injury.* 2014;**45**(2):418-23.
  24. Samy AM. The role of platelet rich plasma in management of fracture neck femur: new insights. *Int Orthop.* 2016;**40**(5):1019-24.
  25. Say F, Turkeli E, Bulbul M. Is platelet-rich plasma injection an effective choice in cases of non-union? *Acta Chir Orthop Traumatol Cech.* 2014;**81**(5):340-5.
  26. Gerard D, Carlson ER, Gotcher JE, Jacobs M. Effects of platelet-rich plasma at the cellular level on healing of autologous bone-grafted mandibular defects in dogs. *J Oral Maxillofac Surg.* 2007;**65**(4):721-7.
  27. Lee DH, Ryu KJ, Kim JW, Kang KC, Choi YR. Bone marrow aspirate concentrate and platelet-rich plasma enhanced bone healing in distraction osteogenesis of the tibia. *Clin Orthop Relat Res.* 2014;**472**(12):3789-97.
  28. Aghaloo TL, Moy PK, Freymiller EG. Investigation of platelet-rich plasma in rabbit cranial defects: A pilot study. *J Oral Maxillofac Surg.* 2002;**60**(10):1176-81.