



Post-Traumatic Balint's Syndrome: A Case Report and Review of the Literature

Luis Rafael Moscote-Salazar^{1*}, Willem Guillermo Calderon-Miranda², Zenen Antonio Carmona-Meza³, Hernando Raphael Alvis-Miranda⁴, Nasly Zabaleta Churio⁵, Gabriel Alcalá-Cerra⁶, Andrés M. Rubiano⁷

¹Neurosurgeon-Critical Care, RED LATINO, Latin American Trauma & Intensive Neuro-Care Organization, Bogotá, Colombia

²Universidad Nacional Autonoma de Mexico, Ciudad de Mexico, Mexico

³Universidad de Cartagena, Cartagena de Indias, Colombia

⁴Department of Neurosurgery, Universidad de Cartagena, Cartagena de Indias, Colombia

⁵Nurse, Universidad Popular del Cesar, Valledupar, Colombia

⁶Department of Neurosurgery, Universidad de Cartagena, Barranquilla, Colombia

⁷Department of Neurosurgery, Universidad El Bosque, RED LATINO, Latin American Trauma & Intensive Neuro-Care Organization, Bogotá, Colombia

*Corresponding author: Luis Rafael Moscote-Salazar

Address: Neurosurgeon-Critical Care, RED LATINO, Latin American Trauma & Intensive Neuro-Care Organization, Bogotá, Colombia.

e-mail: mineurocirujano@aol.com

Received: December 4, 2015

Revised: February 2, 2016

Accepted: February 22, 2016

ABSTRACT

Balint's syndrome is a rare neurological disorder associated with bilateral parieto-occipital damage which was described by Rezső Bálint in 1909. The syndrome is manifested clinically by the presence of a hemispatial neglect. The lesion is usually inside parietooccipital region bilaterally in most cases but may also be compromised angular convolutions, the dorsolateral area of the occipital lobe as the superior parietal lobule. We herein report a 61-year-old man with traumatic brain injury who was diagnosed to have right parieto-occipital contusion in radiologic evaluation. Physical examination was consistent with Balint's syndrome. The patient was followed for 12 months post-injury and received 4-months of outpatient rehabilitation. Patient showed improvement of Balint's syndrome 8 months after the starts of symptoms.

Keywords: Balint's syndrome; Cerebral contusion; Simultanagnosia; Optic ataxia; Oculomotor apraxia.

Please cite this paper as:

Moscote-Salazar LR, Calderon-Miranda WG, Carmona-Meza ZA, Alvis-Miranda HR, Churio NZ, Alcalá-Cerra G, Rubiano AM. Post-Traumatic Balint's Syndrome: A Case Report and Review of the Literature. *Bull Emerg Trauma*. 2016;4(2):113-115.

Introduction

Traumatic brain injury (TBI) is the leading cause of death worldwide. Every year more than 1.5 million people and about 10 million are hospitalized with brain injuries [1,2] among with

the brain contusions are frequent finding [3]. The traumatic brain pathology can facilitate the presence of multiple neurological manifestations based on the location of injury in the brain.

The Balint syndrome is a rare neurologic condition being first described in 1909 by Rezső Bálint, a

Hungarian physician in a patient with bilateral parietal lesions presenting with visual disturbances [4]. The disorder is characterized by problems in simultaneously processing multiple items resulting in poor interpretation of complex visual scenes, sensory inattention, and deficits in visually guided limb and eye movements [5]. Since Balint's first publication, several other cases have been published and in its current status the syndrome is described to comprise of several primary symptoms including simultanagnosia (impaired spatial awareness of more than one object at time), optic ataxia (misreaching to visual targets), ocular apraxia (described by Bálint as "psychic paralysis of gaze") and general visuospatial disorientation [6]. Affected individuals often behave as if they are blind due to the lack of normal visual awareness of the surrounding world, which for them can appear to be a chaotic compilation of random single objects. The etiology of the syndrome include wide range of cerebral and cortical lesions [7-9]. We herein report a patient with post-traumatic Balint syndrome.

Case Report

A 61-year-old man without any past medical history was brought to our emergency department due to loss of consciousness after being wind back by motor vehicle. The Glasgow coma scale (GCS) score was 14 (M: 6, V: 5, E: 3) in admission and the pupils were bilateral equal and reactive to light. On examination, the presence of blunt trauma was evident on right parietal region and he was alert, but disoriented as to time and place, and showed impaired attention. He also presented with optic ataxia, simultanagnosia and oculomotor apraxia, and there were no other abnormalities in the central nervous system. The rest of the musculoskeletal assessment revealed no evidence of severe trauma. Neuroimaging was

performed which revealed a contusion in right parieto-occipital region without midline shift and with minimal pressure effect (Figure 1). The patient was admitted to the medical ward and management of brain contusion including anticonvulsant and tight blood pressure control was performed. After 24 hours the neurological examination evidenced difficulty in distinguishing colors and shapes including objects interpreted as associative visual agnosia. The presence of optic ataxia in the right visual hemifield was also detected. The diagnosis of Balint syndrome was recorded according to previously described cases. He had an uneventful hospital course and was discharged from hospital after 5 days of medical therapy. The patient was followed for 12 months post-injury and received 4 months of outpatient rehabilitation. He showed improvement of Balint's syndrome 8 month after the injury.

Discussion

Balint syndrome is caused by bilateral lesions of the parietal-occipital lobes, which affects the connection between the cortical regions of vision and motor pre-rolandic areas [5,10]. Despite this, in lesions of these regions, not only primary sensory and motor failures occur, but a deficit to a more integrated sensorimotor, in which there is an alteration of the two main visual pathways of sensorimotor integration: The connections of occipito-parietal dorsal allowing the processing of spatial information (via the "where") and a occipito-temporal ventral stream to identify objects (via the "what") resulting in what is now known as Balint syndrome. This is clinically characterized by three specific symptoms: First psychic gaze palsy or simultanagnosia, i.e. the ability to perceive individual objects but inability to perceive other objects, even in the same line

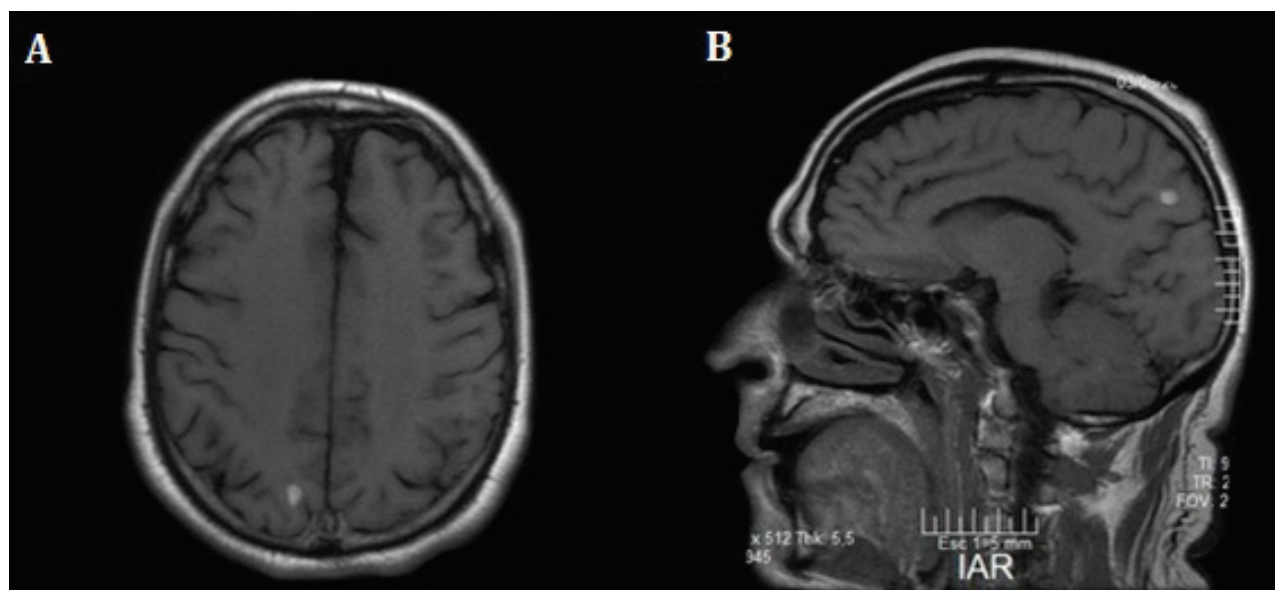


Fig. 1. Axial (A) and sagittal (B) T1-weighted magnetic resonance imaging (MRI) of the patient demonstrating a hyperintense lesion in right parieto-occipital region in favor of acute blood or brain contusion.

of sight and time; Second optical ataxia or spatial disorientation, as evidenced by the inability to reach the object they see or previously has reported verbally location. However, they can locate their body parts through touch and proprioception; and finally the oculomotor apraxia in which there is impairment of eye movements and focusing saccades patient causing him direct his movements visually. An interesting aspect of this case is the unilateral nature of the injury, Balint syndrome usually seen in bilateral lesions. The literature has attributed the occurrence of Balint syndrome with multiple diseases and processes from penetrating head trauma, cerebrovascular disease, degenerative

diseases like Alzheimer's, CNS tumors, metastases, encephalitis, and toxoplasmosis in AIDS patients [5-9,11-13]. This is the only report of Balint syndrome after blunt traumatic brain injury in the literature with unilateral lesion.

In conclusion, the superior parietal lobe has been shown to be the main center for the visual control of movement. Its anatomical location is the parietal occipital junction. Damage to this area is liable for optical ataxia. The presence of traumatic brain injuries in the parietal-occipital region should lead us to always dismiss this unusual syndrome.

Conflict of Interest: None declared.

References

1. Voss JD, Connolly J, Schwab KA, Scher AI. Update on the Epidemiology of Concussion/Mild Traumatic Brain Injury. *Curr Pain Headache Rep.* 2015;**19**(7):32..
2. DePalma RG. Frontiers in Neuroengineering Combat TBI: History, Epidemiology, and Injury Modes. In: Kobeissy FH, editor. *Brain Neurotrauma: Molecular, Neuropsychological, and Rehabilitation Aspects.* Boca Raton (FL): CRC Press/Taylor & Francis(c) 2015 by Taylor & Francis Group, LLC.; 2015.
3. Abbasi HR, Mousavi SM, Akerdi AT, Niakan MH, Bolandparvaz S, Paydar S. Pattern of traumatic injuries and Injury Severity Score in a major trauma center in Shiraz, Southern Iran. *Bull Emerg Trauma.* 2013;**1**(2):81-5.
4. Bálint D. Seelenlähmung des "Schauens", optische Ataxie, räumliche Störung der Aufmerksamkeit. pp. 67–81. *European Neurology.* 1909;**25**(1):67-81.
5. Chechlacz M, Humphreys GW. The enigma of Balint's syndrome: neural substrates and cognitive deficits. *Front Hum Neurosci.* 2014;**8**:123.
6. Rizzo M, Vecera SP. Psychoanatomical substrates of Balint's syndrome. *J Neurol Neurosurg Psychiatry.* 2002;**72**(2):162-78.
7. Falconer R, Rogers S, Amjad F, Osborne B. Diffuse Lewy Body Disease and Associated Balint's Syndrome: A Case Series (P2. 163). *Neurology.* 2014;**82**(10 Supplement):P2. 163-P2.
8. Girotti F, Milanese C, Casazza M, Allegranza A, Corridori F, Avanzini G. Oculomotor disturbances in Balint's syndrome: anatomoclinical findings and electrooculographic analysis in a case. *Cortex.* 1982;**18**(4):603-14.
9. Moreaud O. Balint syndrome. *Arch Neurol.* 2003;**60**(9):1329-31.
10. Baylis GC, Driver J, Baylis LL, Rafal RD. Reading of letters and words in a patient with Balint's syndrome. *Neuropsychologia.* 1994;**32**(10):1273-86.
11. Andersen RA, Andersen KN, Hwang EJ, Hauschild M. Optic ataxia: from Balint's syndrome to the parietal reach region. *Neuron.* 2014;**81**(5):967-83.
12. Battaglia-Mayer A, Caminiti R. Optic ataxia as a result of the breakdown of the global tuning fields of parietal neurones. *Brain.* 2002;**125**(Pt 2):225-37.
13. Gurjinder PS, Dhand UK, Chopra JS. Balint's syndrome following eclampsia. *Clin Neurol Neurosurg.* 1989;**91**(2):161-5.