



## Trans-Scaphoid Perilunate Fracture Dislocation; A Technical Note

Hossein Aslani<sup>1</sup>, Mohammad Reza Bazavar<sup>2</sup>, Ali Sadighi<sup>1</sup>, Ali Tabrizi<sup>3\*</sup>, Asghar Elmi<sup>1</sup>

<sup>1</sup>Department of Orthopedics and Traumatology Surgery, Shohada Educational Hospital, Tabriz University of Medical Sciences, Tabriz, Iran

<sup>2</sup>Department of Orthopedic Surgery, Shohada Educational Hospital, Tabriz University of Medical Sciences, Tabriz, Iran

<sup>3</sup>Department of Orthopedic Surgery, Emam Khomeini Educational Hospital, Urmia University of Medical Sciences, Urmia, Iran

**\*Corresponding author:** Ali Tabrizi

Address: Modarres Ave., Emam Khomeini Educational Hospital, Orthopedics Surgery Center, Urmia University of Medical sciences, Urmia, Iran.

Tel: +98-914-3130829

e-mail: dr.tabrizi.ali@hotmail.com

**Received:** January 1, 2016

**Revised:** February 12, 2016

**Accepted:** February 22, 2016

### ABSTRACT

Carpal fracture-dislocation is regarded as an unusual orthopedic injury and, thus, orthopedic surgeons are less experienced in dealing with and treating these fractures and dislocations. We report a 20-year-old worker man suffering from an unusual carpal fracture-dislocation. There was trans-scaphoid fracture and lunate dislocation with other carpal proximal bones toward volar of the wrist. Two volar and dorsal approaches were used to treat and stabilize the fracture. It was completely stabilized after open reduction and fixation using several pins. After two days, neural symptoms were completely recovered and the patient was discharged. Postoperative radiographies revealed complete restitution of lesser and greater arcs and normalization of Gilula's line. Scapholunate and lunatocapitate angles reached to less than 60° and 10°, respectively. The combined approach had favorable results for treatment of this unusual type of carpus fracture dislocation. However longer follow up is need to evaluate the arthritis and degenerative changes in wrist.

**Keywords:** Perilunate dislocation; Carpus Fracture; Fracture-dislocation; Trans-scaphoid fracture.

Please cite this paper as:

Aslani H, Bazavar MR, Sadighi A, Tabrizi A, Elmi A. Trans-Scaphoid Perilunate Fracture Dislocation; A Technical Note. *Bull Emerg Trauma*. 2016;4(2):110-112.

### Introduction

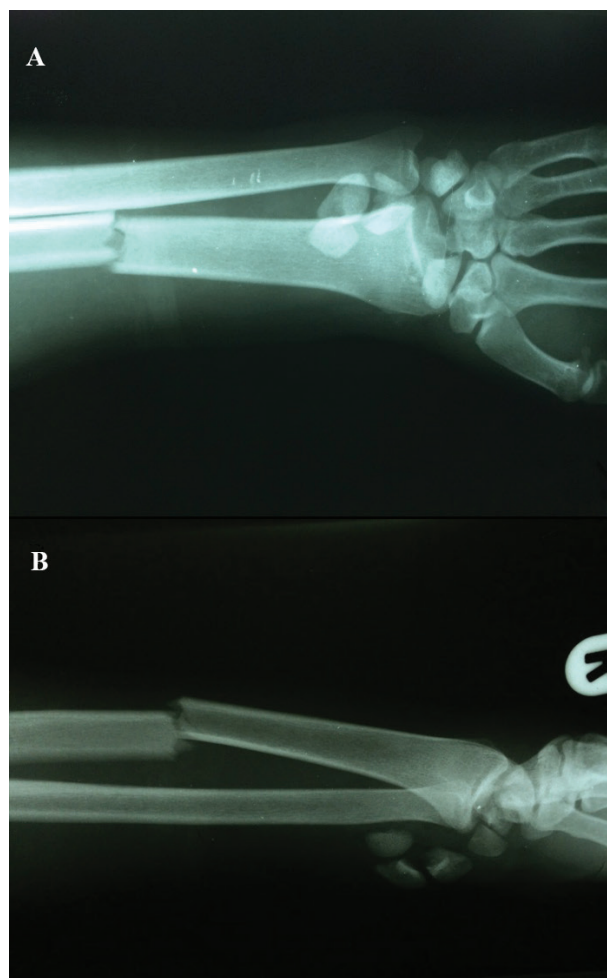
Perilunate dislocation and trans-scaphoid fracture-dislocation is among unusual orthopedic traumatic injuries mainly seen in youths due to high energy trauma [1-4]. These dislocations may be missed in 25% of cases. If it is neglected, it leads to progress of carpal instability and post-traumatic arthritis [5]. The treatment aims at reducing dislocation, internally fixing

fracture, and repairing ligament injuries. However, open reduction may result in injury of capsule and ligament structures and more complications such as joint stiffness due to fibrosis of the joint capsule [6]. Also, open reduction may create some problems in blood circulation of the repaired area and failure or delay in improvement process. On the other hand, closed reduction and percutaneous stabilization with pin which is highly associated with later recurrent instability and carpal incongruity may lead to more

post-traumatic arthritis [7,8]. In this report, a carpal fracture-dislocation case is introduced where two volar and dorsal approaches were used in surgery process. Appropriate carpal stabilization was the primary result of the treatment process.

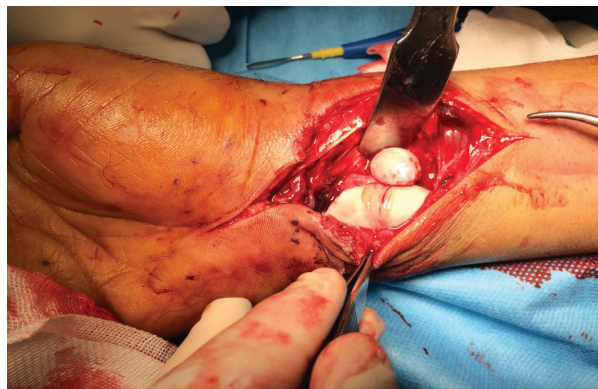### Case Report

A 20-year-old worker man, falling from a 2 meters height on his right hand, suffered from severe trauma in his wrist and referred to our emergency department. In initial examination, severe deformity of wrist and forearm was evident but vascular circulation was normal and arterial pulses were completely established. Neural examination referred to paresthesia of first, second, and third figures at volar level. Following wrist and forearm radiography of two plans (Figure 1), the patient was hospitalized with radius shaft fracture and carpus fracture-dislocation. There was trans-scaphoid fracture and lunate dislocation with other carpal proximal bones toward volar of the wrist. Considering neural symptoms, volar approach was used to open reduction and carpal tunnel decompress. However, the approach was not sufficient to complete reduction and exact reduction was not possible due to capitae



**Fig. 1.** Anteroposterior (A) and lateral (B) views of right forearm demonstrating radius fracture and carpal fracture-dislocation in the patient.

dislocation. Then, dorsal approach was used to open wrist joint capsule from among extensor tendons and the reduction was done using two approaches. It was fixed using several pins. The approach is centered over Lister's tubercle, reflecting the dorsal wrist capsule to preserve the dorsal intercarpal and dorsal radiotriquetral ligaments, using a radial-based capsular flap. The radial capsule is reflected from the scaphoid to its waist. The open technique allows direct visualization of the injured ligament, reduction, and ligament repair (Figure 2).



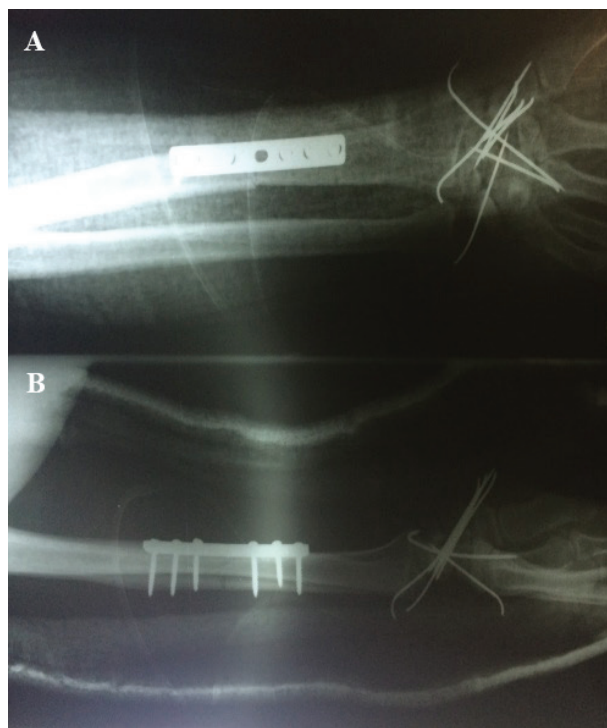
**Fig. 2.** Intraoperative image of volar approach used to decompress carpal tunnel and primary reduction of the carpus. Capitae is placed in volar aspect of distal radius and the effect of intensive pressure on the carpal tunnel is remarked.

Capitae was initially reduced and then scaphoid and lunate reduction was done. Scaphoid fracture was also fixed using pin. Carpal tunnel was decompressed before fixation. Scapholunate ligament which was at the ruptured scaphoid side was repaired. However, it was not possible to repair other ligaments because of extent of ligament injury. Following volar approach, radius was openly reduced and fixed with a 7-hole DCP plate. Finally, subcutaneous and skin were repaired. After two days, neural symptoms were completely recovered and the patient was discharged. Postoperative radiographies indicate to complete restitution of lesser and greater arcs and Gilula's line was normalized. Scapholunate and lunatocapitate angles reached to less than  $60^\circ$  and  $10^\circ$ , respectively. The gap between scaphoid and lunate was about 2 mm (Figure 3).

### Discussion

Carpal stabilization depends on perilunate ligaments and scaphoid bone such that relation of proximal and distal carpal row depends on health of these elements [5]. These unusual injuries consist about 10% of carpal injuries. Lesser arc injuries are often of ligament type and occur due to dislocation of lunate to dorsal while transosseous and greater arc injuries constitute over than two third of perilunate dislocations. The injuries often occur because of hyperextension, ulnar deviation, and intercarpal supination [6-8].

Surgical interventions significantly prevent from carpal instability but post-traumatic arthritis occurs in more than 50% of cases in these patients. Closed



**Fig. 3.** Postoperative anteroposterior (A) and lateral (B) views of right forearm in the patient demonstrating primary reduction of carpus and fixation with several pins and restitution of lesser arc and greater arc (A). The radius is fixed with a 7-hole DCP plate. Restitution of scapholunate and lunatocapitate angles are demonstrated in lateral plan (B).

reduction is highly related with poor outcome in these patients such that weak outcomes are observed in 27% of the patients in long-term follow up [9]. Although exact anatomic reduction is not possible, it may be prevented through open reduction. In this patient, volar and dorsal approaches were used in open reduction considering extent of injury and median neurological disorder. Exact primary neural and vascular examination is of high importance in these patients and should be taken seriously since it is really helpful in selecting the appropriate approach. According to our experience, it is not possible to use anatomic open reduction method with volar approach in complex cases and dorsal approach should also be used simultaneously. Fixation with several pins used to stabilize and repair scapholunate ligament results in complete stabilization of the wrist such that scapholunate and lunatocapitate angles became normal and the scapholunate gap reduced to less than 3mm. Although the patient was not followed up for long time, complete stabilization was realized initially and post-traumatic arthritis was highly possible because of extent of injury.

In conclusion, in unusual and complex cases, reduction with two approaches and fixation with several pins may be helpful in carpus stabilization. Longer follow-up periods are required to determine the effects of this surgery on degenerative changes and osteoarthritis of the wrist.

**Conflict of Interest:** None declared.

## References

1. Herzberg G, Comtet JJ, Linscheid RL, Amadio PC, Cooney WP, Stalder J. Perilunate dislocations and fracture-dislocations: a multicenter study. *J Hand Surg Am.* 1993;**18**(5):768-79.
2. Kohli S, Khanna V, Virani N, Chaturvedi H. Transradial, Transscaphoid, Transcapitate, Perilunate Dislocation; A Case Report and Approach to the Patient. *Bull Emerg Trauma.* 2016;**4**(1):54-57.
3. Obert L, Loisel F, Jardin E, Gasse N, Lepage D. High-energy injuries of the wrist. *Orthop Traumatol Surg Res.* 2016;**102**(1 Suppl):S81-93.
4. Israel D, Delclaux S, Andre A, Apredoaei C, Rongieres M, Bonneville P, et al. Peri-lunate dislocation and fracture-dislocation of the wrist: Retrospective evaluation of 65 cases. *Orthop Traumatol Surg Res.* 2016.
5. Divecha HM, Clarke JV, Barnes SJ. Established non-union of an operatively managed trans-scaphoid perilunate fracture dislocation progressing to spontaneous union. *J Orthop Traumatol.* 2011;**12**(3):159-62.
6. Sawardeker PJ, Kindt KE, Baratz ME. Fracture-dislocations of the carpus: perilunate injury. *Orthop Clin North Am.* 2013;**44**(1):93-106.
7. Herzberg G, Forissier D. Acute dorsal trans-scaphoid perilunate fracture-dislocations: medium-term results. *J Hand Surg Br.* 2002;**27**(6):498-502.
8. Knoll VD, Allan C, Trumble TE. Trans-scaphoid perilunate fracture dislocations: results of screw fixation of the scaphoid and lunotriquetral repair with a dorsal approach. *J Hand Surg Am.* 2005;**30**(6):1145-52.
9. Forli A, Courvoisier A, Wimsey S, Corcella D, Moutet F. Perilunate dislocations and transscaphoid perilunate fracture-dislocations: a retrospective study with minimum ten-year follow-up. *J Hand Surg Am.* 2010;**35**(1):62-8.