



## Short-Term Results of Muscle-Pedicle Bone Grafting with Tensor Fascia Lata for Delayed Femoral Neck Fractures; Case Series and Literature Review

Kuldip Salgotra, Sarabjeet Kohli, Nilesh Vishwakarma\*

Department of Orthopedics, Mahatma Gandhi Mission (MGM), University of Health Sciences, Mumbai, India

\*Corresponding author: Nilesh Vishwakarma

Address: Assistant Professor, Department of Orthopedics, Mahatma Gandhi Mission (MGM), University of Health Sciences, Mumbai, India.  
Tel/Fax: +91-98-69979657  
e-mail: nsv1978@gmail.com

Received: January 26, 2016

Revised: February 6, 2016

Accepted: February 25, 2016

### ► ABSTRACT

Neglected, untreated and delayed femur neck fractures are commonly encountered and the treatment dilemma arises especially when the patient is physiologically young and osteosynthesis is the preferred option. Controversy exists in the current literature as the various head salvage surgeries like valgus subtrochanteric osteotomy, non-vascularized fibular bone grafting, muscle pedicle bone grafting (Tensor fascia lata and Quadratus femoris graft) and vascularized bone grafting do not have clear lines of indications. The current study is a case series of 7 patients with femur neck fractures with delayed presentation beyond the vascular emergency period who were treated with osteosynthesis with muscle pedicle bone graft (MPBG) using tensor fascia lata muscle pedicle graft. Patients were followed clinically and radiologically at 6 weeks, 3 and 6 months, 1 year and 3 years and patients were regularly followed. The mean age of the patients was  $47 \pm 1.1$  ranging from 38 to 55 years. There were 6 (85.7%) men and 1 (14.3%) women among the patients. Overall 5 (71.5%) patients had transcervical and 2 (28.5%) had subcapital fractures. At the end of 6 months, 6 (85.7%) patients were pain free and on plain radiographs fracture union was noted. One (14.3%) patient developed collapse and persistent nonunion. Younger group less than 50 years presenting with neglected fracture neck femur should always be given an option of head salvage surgery in selected cases. Muscle pedicle bone grafting has been proven although inconsistently as a valid option for fracture neck femur. We encourage osteosynthesis with the use of tensor fascia lata muscle pedicle grafting along with cancellous cannulated screws as a first option in selected cases of neglected femur neck fractures.

**Keywords:** Muscle pedicle bone grafting; Femur Neck Fracture; Tensor Fascia Lata; Clinical Outcome.

Please cite this paper as:

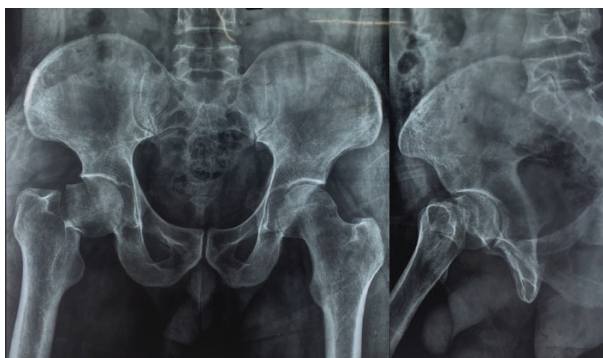Salgotra K, Kohli S, Vishwakarma N. Short-Term Results of Muscle-Pedicle Bone Grafting with Tensor Fascia Lata for Delayed Femoral Neck Fractures; Case Series and Literature Review. *Bull Emerg Trauma*. 2016;4(2):101-104.

Femoral neck fracture referring after a month of injury is considered as neglected [1]. Neglected femoral neck fractures are result of lack of awareness or lack of medical facilities leading to nonunion. The

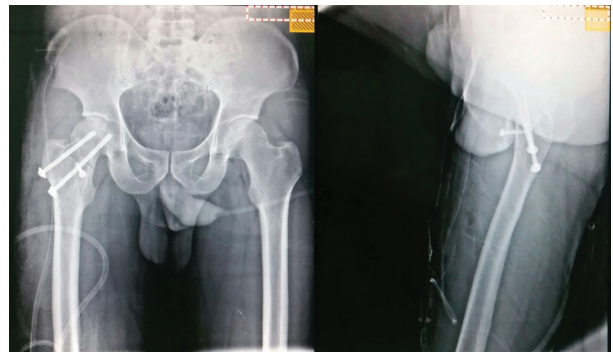
treatment is controversial, even in those presenting in less than a month but beyond the golden period [1]. Squatting and sitting cross legged is inherently involved in the activities of daily living especially

in a developing country like India. Considering the need of such patients and additionally the cost of joint replacement surgeries, the option of salvaging the femoral head is of paramount importance and many patients opt for head salvage surgery. Literature has not clearly defined the guidelines for the surgical management of neglected femur neck fractures [2-4]. Several options are available including valgus subtrochanteric osteotomy, non-vascularized fibular bone grafting, muscle pedicle bone grafting using Tensor fascia lata (TFL), Quadratus femoris graft and vascularized bone grafting [5,6]. Intracapsular neck femur fractures are considered by many authors as emergency surgery with the golden standard period of 6 hours making it a vascular emergency [7]. The aim of the current study was to determine the short term outcome of the muscle-pedicle bone grafting with tensor fascia lata for delayed femoral neck fractures in a small series of Indian patients.

This is a cross-sectional study including 7 patients with neglected femoral neck fracture (Figure 1) referring to Mahatma Gandhi Mission (MGM) university hospital between 2012 and 2015. All the patients were operated within a month of intracapsular neck femur fractures, with TFL muscle pedicle bone grafting. The interval between injury and operation was 4 weeks in 3 cases and 2 weeks in 4 cases. Open reduction and internal fixation with 6.5 mm cannulated cancellous screws was augmented with tensor fascia lata muscle pedicle graft which was fixed across the fracture site by 4 mm screws. In supine position, Smith Peterson approach was taken and the fracture site was approached after giving a T-shaped incision over the capsule. Freshening of the fracture site bone edges was done. Fracture was reduced and through another lateral incision over the greater trochanter. Two 6.5mm cannulated cancellous screws were put to fix the fracture. The tensor fascia lata origin from iliac crest was identified and using saw the graft was removed. The graft was fixed across the fracture site using 4 mm screws and in 5 cases a small 5mm to 10mm part of anterior femoral head was chiseled to adapt the graft across the neck properly. Adequate coverage of the neck by the capsule was ensured (Figure 2). Wound was closed over drain. Patients were mobilized non-weight bearing with



**Fig. 1.** Preoperative radiography of a patient demonstrating a Garden type 3 and Pauwels type 3 femur neck fractures.

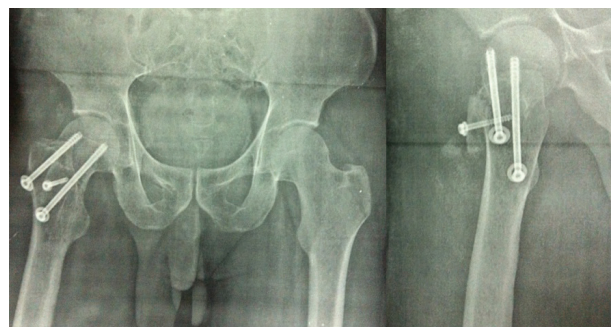

**Fig. 2.** Postoperative radiography of the same patient treated with osteosynthesis using 2 cancellous cannulated screws and tensor fascia lata muscle pedicle bone grafting.

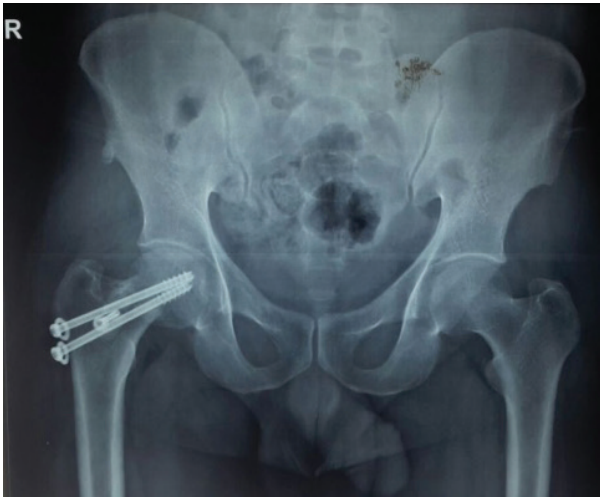a walker for 3 months. Regular radiographies were taken at 6 weeks, 3 and 6 months, 1 year and 3 years and patients were regularly followed.

The mean age of the patients was  $47 \pm 1.1$  ranging from 18 to 35 years. There were 6 (85.7%) men and 1 (14.3%) women among the patients. Overall 5 (71.5%) patients had transcervical and 2 (28.5%) had subcapital fractures. At the end of 6 months, 6 (85.7%) patients were pain free and on plain radiographs fracture union was noted. One (14.3%) patient developed collapse and persistent nonunion and thereafter the choice of total hip replacement (THR) was offered as the only feasible treatment. The Modified Harris hip score (MHHS) was found to be  $34.1 \pm 2.3$  at 6 weeks,  $55 \pm 1.6$  at 3 months,  $93.5 \pm 1.8$  at 1 year (Figure 3) and  $95 \pm 1.96$  at 3 years (Figure 4). Appropriate radiological union was evident in 5 (71.5%) the cases after 6 months of therapy.

Femoral head viability is always of concern in fracture of femoral neck [1,2]. Complications include persistent nonunion, avascular necrosis, collapse and arthritis [8]. We had one collapse making the overall percentage of complication as 14% after 3 years. Those 6 patients which united went ahead to live a pain free life without restriction of any activities of daily living (ADL) even up-to 3 years of follow-up. Vascularized bone grafting on a muscle pedicle such as gluteus medius, quadrates femoris, or Sartorius is also an established method of treatment quoted in literature [9-11]. The advantages of TFL muscle-pedicle bone grafting [12] over others is as follows:



**Fig. 3.** Anteroposterior and lateral view of the femur at 1-year follow up after fascia lata muscle pedicle bone grafting in the same patient.



**Fig. 4.** Anteroposterior view of the femur at 3-year follow up after fascia lata muscle pedicle bone grafting in the same patient demonstrating good bony consolidation

- Supine position facilitating anesthesia and C-arm.
- Blood supply to the femoral neck is not compromised as the posterior capsule is left intact.
- Trochanter is not weakened unlike quadratus femoris muscle-pedicle bone grafting.

To achieve best results essential requirements are an anatomically accurate reduction, impaction and stable fixation. While transferring the muscle-pedicle bone grafting to its recipient site, any torsion or tension of the muscle pedicle should be avoided [13]. Our series has a shortcoming of having only seven cases. The various studies have shown the results to be excellent as tabulated below [14,15]. This case series although with only seven cases to start with, in a short term follow up shows excellent results of 86% with favorable outcome, comparable to the past literature on muscle pedicle bone grafting (Table 1).

In conclusion, younger group less than 50 years presenting with neglected fracture neck femur should always be give an option of head salvage surgery in selected cases. MPBG has been proven although inconsistently as a valid option for fracture neck femur. We encourage osteosynthesis with the use of tensor fascia lata muscle pedicle grafting along with cancellous cannulated screws as a first option in selected cases of neglected femur neck fractures.

**Conflict of Interest:** None declared.

**Table 1.** Results muscle pedicle bone grafting for neglected femur neck fracture in the literature and comparison with our results.

Study	Number of cases	MPBG <sup>b</sup> used	Complication: AVN <sup>a</sup> , NU <sup>c</sup>	Union rate
Meyers <i>et al.</i> [1]	136	Quadratus femoris	AVN: 5 NU: 15	89%
Bakshi <i>et al.</i> [12]	56	Quadratus femoris	AVN: 2 NU: 5	82%
Vallamshetla <i>et al.</i> [14]	42	Quadratic femoris	AVN:1 NU: 0	86%
Day <i>et al.</i> [15]	15	Tensor fascia lata	No	100%
Hou <i>et al.</i> [13]	5	Tensor fascia lata	No	100%
Biswas <i>et al.</i> [9]	12	Tensor fascia Lata/ gluteus medius	NU: 1	92%
Current study	7	Tensor fascia lata	AVN: 0 NU: 1	86%

<sup>a</sup>AVN: Avascular necrosis; <sup>b</sup>MPBG: Muscle pedicle bone grafting; <sup>c</sup>NU: nonunion

## References

- Meyers MH, Harvey JP, Jr., Moore TM. Treatment of displaced subcapital and transcervical fractures of the femoral neck by muscle-pedicle-bone graft and internal fixation. A preliminary report on one hundred and fifty cases. *J Bone Joint Surg Am.* 1973;**55**(2):257-74..
- Jain AK, Mukunth R, Srivastava A. Treatment of neglected femoral neck fracture. *Indian J Orthop.* 2015;**49**(1):17-27.
- Mishra PK, Gupta A, Gaur SC. Results of triple muscle (sartorius, tensor fascia latae and part of gluteus medius) pedicle bone grafting in neglected femoral neck fracture in physiologically active patients. *Indian J Orthop.* 2014;**48**(5):470-5.
- Pingle J. Transfracture abduction osteotomy: A solution for nonunion of femoral neck fractures. *Indian J Orthop.* 2014;**48**(1):25-9.
- Gupta S, Kukreja S, Singh V. Valgus osteotomy and repositioning and fixation with a dynamic hip screw and a 135° single-angled barrel plate for un-united and neglected femoral neck fractures. *J Orthop Surg (Hong Kong).* 2014;**22**(1):13-7.
- Nair N, Patro DK, Babu TA. Role of muscle pedicle bone graft as an adjunct to open reduction and internal fixation in the management of neglected and ununited femoral neck fracture in young adults: a prospective study of 17 cases. *Eur J Orthop Surg Traumatol.* 2014;**24**(7):1185-91.
- Bartoníček J, Fric V, Skála-Rosenbaum J, Dousa P. Avascular necrosis of the femoral head in pertrochanteric fractures: a report of 8 cases and a review of the literature. *J Orthop Trauma.* 2007;**21**(4):229-36.
- Roshan A, Ram S. The neglected femoral neck fracture in young adults: review of a challenging problem. *Clin Med Res.* 2008;**6**(1):33-9.
- Biswas SK, Salgotra L, Lahree MK. Tensor fascia lata/ Gluteus medius muscle pedicle bone graft for nonunion

- of femoral neck fractures. *Med J Armed Forces India*. 1997;**53**(1):18-20.
10. Bhuyan BK. Augmented osteosynthesis with tensor fasciae latae muscle pedicle bone grafting in neglected femoral neck fracture. *Indian J Orthop*. 2012;**46**(4):439-46.
  11. Beris AE, Payatakes AH, Kostopoulos VK, Korompilias AV, Mavrodontidis AN, Vekris MD, et al. Non-union of femoral neck fractures with osteonecrosis of the femoral head: treatment with combined free vascularized fibular grafting and subtrochanteric valgus osteotomy. *Orthop Clin North Am*. 2004;**35**(3):335-43, ix.
  12. Baksi DP, Pal AK, Baksi DD. Long-term results of decompression and muscle-pedicle bone grafting for osteonecrosis of the femoral head. *Int Orthop*. 2009;**33**(1):41-7.
  13. Hou SM, Hang YS, Liu TK. Ununited femoral neck fractures by open reduction and vascularized iliac bone graft. *Clin Orthop Relat Res*. 1993;(294):176-80.
  14. Vallamshetla VR, Sayana MK, Vutukuru R. Management of ununited intracapsular femoral neck fractures by using quadratus femoris muscle pedicle bone grafting in young patients. *Acta Orthop Traumatol Turc*. 2010;**44**(4):257-61.
  15. Day B, Shim SS, Leung G. The iliopsoas muscle pedicle bone graft: An experimental study of femoral head vascularity after subcapital fractures and hip dislocations. *Clin Orthop Relat Res*. 1984;(191):262-8.