



Symptomatic Chiari Malformation with Syringomyelia after Severe Traumatic Brain Injury: Case Report

Luis Rafael Moscote-Salazar^{1*}, Nasly Zabaleta-Churio², Gabriel Alcala-Cerra³, Andres M. Rubiano⁴, Willem Guillermo Calderon-Miranda⁵, Hernando Raphael Alvis-Miranda³, Amit Agrawal⁶

¹Department of Neurosurgery, Red Latino, Latin American Trauma and Intensive Neuro-Care Organization, Colombia

²Universidad Popular del Cesar, Colombia

³Department of Neurosurgery, Universidad de Cartagena, Colombia

⁴Department of Neurosurgery, de Neiva University Hospital, Universidad Surcolombiana de Neiva, Fundacion MEDITECH, Universidad El bosque, RED LATINO, Latin American Trauma and Intensive Neuro-Care Organization, Colombia

⁵Universidad Nacional Autonoma de Mexico, Mexico D.F, Mexico

⁶MM Institute of Medical Sciences & Research, Maharishi Markandeshwar University, Mullana- Ambala, 133-207, Haryana, India

*Corresponding author: Luis Rafael Moscote-Salazar

Address: Department of Neurosurgery, RED LATINO, Latin American Trauma and Intensive Neuro-Care Organization, Colombia.

e-mail: mineurocirujano@aol.com

Received: October 4, 2015

Revised: November 15, 2015

Accepted: December 11, 2015

▶ ABSTRACT

Chiari malformation Type I (CM-I) is a congenital disorder, which is basically a tonsillar herniation (≥ 5 mm) below the foramen magnum with or without syringomyelia. The real cause behind this malformation is still unknown. Patients may remain asymptomatic until they engender a deteriorating situation, such as cervical trauma. The objective of this case report is to give a broad perspective on CM-I from the clinical findings obtained in a patient with asymptomatic non-communicating syringomyelia associated with a CM-I exacerbated within 2 years of a TBI, and to discuss issues related to that condition.

Keywords: Chiari Malformation type-I; Asymptomatic; Traumatic brain injury.

Please cite this paper as:

Moscote-Salazar LR, Zabaleta-Churio N, Alcala-Cerra G, Rubiano AM, Calderon-Miranda WG, Alvis-Miranda HR, Agrawal A. Symptomatic Chiari Malformation with Syringomyelia after Severe Traumatic Brain Injury: Case Report. *Bull Emerg Trauma*. 2016;4(1):58-61.

Introduction

In 1883 Cleland, and in 1891, Hans Chiari described the relationship between descent of the cerebellar tonsils and spinal cord cysts [1]. CM-I is classically defined as a cerebellar tonsillar herniation (≥ 5 mm) below the foramen magnum on sagittal

magnetic resonance imaging (MRI); it is estimated to be incidental, occurring in 0.6-1.0% of a given population [1,2]. Over the past 3 decades, there have been a number of reports of Chiari malformation and syringomyelia occurring either alone or combined following cerebrospinal fluid (CSF) shunting from the lumbar subarachnoid space, birth trauma, tumors

or meningeal reactions at the foramen magnum. We report a case with asymptomatic non-communicating syringomyelia associated with a CM-I exacerbated within 2 years of a TBI.

Case Report

A 45-years-old man presented to our neurosurgical clinic with paresthesia of the left hemibody which was progressive. On physical examination a discrete braquicrural hemiparesis (4+/5) was evident. Eight years ago, the patient had severe traumatic brain injury (TBI), and needed stance in intensive care unit for 17 days. The patient had cerebral edema. The mechanism of trauma was a vehicle rollover. A cervical spine MRI was performed which revealed ptosis of the cerebellar amygdala (McRae Parameter) and cervical syrinx (Figure 1). The surgical correction was planned, consisting of C1 laminectomy, and suboccipital craniectomy plus duroplasty. The patient tolerated the procedure well. During the postoperative period the patient experienced a satisfactory evolution, and was discharged to home at the day 10. In follow up, the patient was symptom-free and had no abnormal neurological findings.

Discussion

CM-I is a heterogeneous entity characterized by impaired cerebrospinal fluid (CSF) circulation at the level of the foramen magnum due to cerebellar tonsillar ectopia [2]. CM-I is predominantly an incidental finding, also can be a secondary consequence of the CSF shunting placement from the lumbar subarachnoid space, birth trauma, tumors or meningeal reactions at the foramen magnum, however acquired descent of the cerebellar tonsils, secondary to TBI is a less frequently reported event.

While in most of the CM-I patients, symptoms may occur spontaneously, 24% of the patients have a cervical trauma history, but TBI is rare. Taghipour *et al.*, [3] showed a similar case of isolated post-traumatic syringobulbia presenting insidiously with cranial nerve palsies, ataxia and dysarthria.

Taking into account that “acquired” CM-I is radiographically indistinguishable from that congenital CM-I [4], different theories have been hypothesized trying to explain CM-I. Barbosa *et al.*, [5] hypothesize that CM-I may be the result of an evolutionary anthropological imprint, caused by evolving species populations that eventually met each other and mingled in the last 1.7 million years. CM-I is associated with reduced posterior fossa volume and caudal descent of the cerebellar tonsils; thus, the prevalence of one of the most obvious consequences, syringomyelia (SM) secondary to CMI is high as altered CSF hydrodynamics occur at the level of the foramen magnum and the cranial cervical spinal cord [6].

Syringomyelia is frequently associated with abnormalities of the craniocervical junction, particularly CM-I. It has been proposed that obstruction of CSF outflow from the 4th ventricle leads to dissection of CSF into the central canal and syrinx formation [7,8]. It has also been pointed out that the abnormal pressure gradient from the cranial to the spinal subarachnoid space could ‘suck’ CSF downward along the central canal and produce the syrinx. Ball and Dayan [9] emphasized that with craniospinal dissociation, pressure waves in the spinal subarachnoid space remain confined to its space rather than dissipating throughout the entire CSF compartment. With a Valsalva maneuver, CSF could dissect into Virchow-Robin spaces and eventually produce gross cavities [9]. Oldfield *et al.*, [10] suggest that syrinx development in CM-I is secondary to CSF

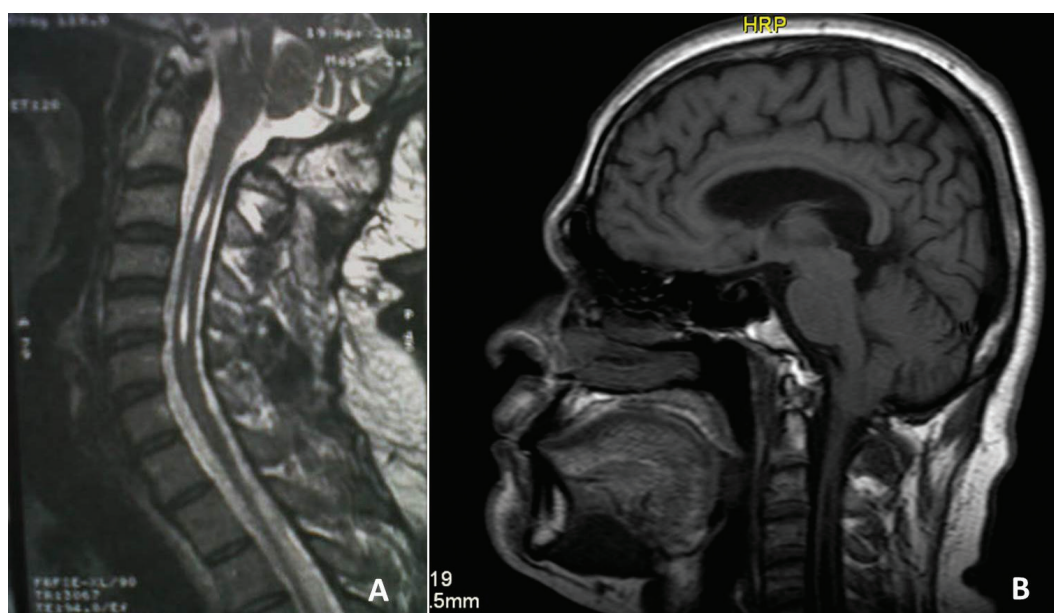


Fig. 1. A) Preoperative sagittal T2-weighted cervical MRI of the patient revealing a syringomyelia descending from C1 to T3 level with CM-I at 14 mm tonsillar herniation, 0.7 mm in diameter; B) Postoperative T1-weighted brain MRI of the patient revealing a significant decrease in the diameter of the syringomyelia.

pressure waves created at the craniocervical junction caused by occlusion of the foramen magnum by the cerebellar tonsils during systole.

Elliott *et al.*, [11] through physical and mathematical models provide insights about pathogenesis hypotheses. They suggest that syrinx fluid derives from either interstitial fluid, flowing down a pressure gradient, or CSF, being pumped up-hill. For the latter, two systolic valve mechanisms have been identified: (i) a perivascular space valve that depends on the phasing of the CSF and arterial pulses, (ii) a cyclic pressure dissociation about a flexible spinal subarachnoid space stenosis with an underlying syrinx.

Adult Chiari malformation is far different from Chiari malformation occurring in early childhood or infancy, especially when planning the surgical treatment. It appears that near-total collapse of a true syrinx cavity is more likely to be seen postoperatively in younger patients than in an older patient population. The dura may similarly be more elastic in younger patients, permitting a greater degree of dural expansion in response to normal CSF pressure once the overlying occipital bone has been removed. Posterior fossa decompression is still the preferred treatment modality in patients with CM-I and syringomyelia, regardless of symptoms. Although most surgeons open the dura, preferred techniques for decompression can vary. When planning posterior fossa decompression, one must consider several factors (Table 1) [12].

The aim of the surgery has to be the restoration of normal cerebrospinal fluid (CSF) circulation at the foramen magnum and relief of brainstem compression. Reduction in size of an associated syrinx cavity will result, particularly in younger patients, if CSF circulation has been restored [3]. Usually surgery consists of a posterior decompressive craniectomy of the cervico-occipital junction associated with duraplasty, arachnoid opening and, sometimes, tonsillectomy. However, a number of surgical adjuvants to standard bony decompression remain controversial.

Lee *et al.*, [13] analyzed the outcome of posterior fossa decompression accompanied by widening of the cisterna magna, without disturbing the arachnoid, in patients with CMI associated with syringomyelia; because a number of surgical techniques have been described to restore the CSF circulation and decompress the neuraxis, no consensus has been reached as to the optimal technique.

Thus to minimize the risks related to handling of the arachnoid membrane and tonsillectomy, they performed decompressive craniectomy and arachnoid-preserving duraplasty consecutively to adult CM-I patients. They conclude that arachnoid-preserving posterior fossa decompression is a safe and effective treatment for patients with CMI with associated syringomyelia.

Kalb *et al.*, [14] evaluated symptomatic outcomes using diverse surgical techniques in 104 patients who underwent decompression surgery. They observed that patients with syringomyelia showed less symptomatic improvement; however, syringomyelia was not associated with postoperative symptomatic worsening, experimenting a 62.5% improvement rate on postoperative MRI. Neither arachnoid opening nor fourth ventricle visualization was associated with the clinical outcome. Duraplasty was performed in 94.2% of patients; they conclude that bony decompression and dural opening are important aspects of Chiari I surgery, with symptomatic improvement observed in most patients.

Yilmaz *et al.*, [6] evaluated the effect of duraplasty based on cerebellar tonsillar descent (CTD) grade in the surgical treatment of CM-I. They found that posterior fossa decompression and duraplasty for the treatment of CTD grade 3 Chiari malformation may lead to a more reliable reduction in the volume of concomitant syringomyelia and Japanese Orthopaedic Association (JOA) scores. In CTD grade 1 and 2 patients, posterior fossa decompression without duraplasty may be performed. Recognized complications of duraplasty are CSF leak, pseudomeningocele, aseptic meningitis, worsening of the tonsillar descent with lumbar subarachnoid drain to control pseudomeningocele, or CSF leakage. Cerebellar ptosis is associated with too large decompression or patulous duraplasty [10,15].

In conclusion, CM-I still remains as a routine challenge under investigation that can be an evolutionary phenomenon, or consequence of trauma, cervical or TBI (although less frequently). More common secondary causes are CSF shunting from birth trauma, tumors or meningeal reactions at the foramen magnum. Overall, the surgical corrective treatment is a good option for resolving neurological deficits, not for asymptomatic patients, in which a more conservative treatment can be attained.

Conflict of Interest: None declared.

Table 1. Factors to be considered when planning posterior fossa decompression.

Degree of tonsillar descent
Architecture of the posterior fossa
Shape of the cerebellar hemispheres, including the presence of arachnoid cysts
Presence of syringomyelia
Associated congenital anatomical variants, such as atlas assimilation
Stability of the craniocervical junction
Presence of hydrocephalus
Presence of a co-existing cord tethering mechanism

References

1. Anson JA, Benzel EC. Syringomyelia and the Chiari malformations: Thieme; 1997.
2. Furtado SV, Reddy K, Hegde AS. Posterior fossa morphometry in symptomatic pediatric and adult Chiari I malformation. *J Clin Neurosci*. 2009;**16**(11):1449-54.
3. Taghipour M, Derakhshan N, Ghaffarpasand F. Isolated Post-Traumatic Syringobulbia; Case Report and Review of the Literature. *Bull Emerg Trauma*. 2014;**2**(4):166-169
4. Chen HH, Chang FC, Wong TT. Scoliosis and syringomyelia with Chiari malformation after lumbar shunting. *J Chin Med Assoc*. 2010;**73**(7):384-8.
5. Fernandes YB, Ramina R, Campos-Herrera CR, Borges G. Evolutionary hypothesis for Chiari type I malformation. *Med Hypotheses*. 2013;**81**(4):715-9.
6. Yilmaz A, Kanat A, Musluman AM, Colak I, Terzi Y, Kayaci S, et al. When is duraplasty required in the surgical treatment of Chiari malformation type I based on tonsillar descending grading scale? *World Neurosurg*. 2011;**75**(2):307-13.
7. Gardner WJ, Angel J. The mechanism of syringomyelia and its surgical correction. *Clin Neurosurg*. 1958;**6**:131-40.
8. Gardner WJ. Hydrodynamic mechanism of syringomyelia: its relationship to myelocoele. *J Neurol Neurosurg Psychiatry*. 1965;**28**:247-59.
9. Ball MJ, Dayan AD. Pathogenesis of syringomyelia. *Lancet*. 1972;**2**(7781):799-801.
10. Oldfield EH, Muraszko K, Shawker TH, Patronas NJ. Pathophysiology of syringomyelia associated with Chiari I malformation of the cerebellar tonsils. Implications for diagnosis and treatment. *J Neurosurg*. 1994;**80**(1):3-15.
11. Elliott N, Bertram C, Martin BA, Brodbelt A. Syringomyelia: A review of the biomechanics. *Journal of Fluids and Structures*. 2013;**40**:1-24.
12. Batzdorf U. Considerations regarding decompressive surgery for Chiari malformation. *World Neurosurg*. 2011;**75**(2):222-3.
13. Lee HS, Lee SH, Kim ES, Kim JS, Lee JI, Shin HJ, et al. Surgical results of arachnoid-preserving posterior fossa decompression for Chiari I malformation with associated syringomyelia. *J Clin Neurosci*. 2012;**19**(4):557-60.
14. Kalb S, Perez-Orribo L, Mahan M, Theodore N, Nakaji P, Bristol RE. Evaluation of operative procedures for symptomatic outcome after decompression surgery for Chiari type I malformation. *J Clin Neurosci*. 2012;**19**(9):1268-72.
15. Badie B, Mendoza D, Batzdorf U. Posterior fossa volume and response to suboccipital decompression in patients with Chiari I malformation. *Neurosurgery*. 1995;**37**(2):214-8.