



## Administration of Intravenous Infliximab for Prevention of Peritoneal Adhesions Formation in Rats

**Saman Nikeghbalian<sup>1</sup>, Homeira Vafaei<sup>2</sup>, Farid Moradian<sup>3\*</sup>, Kourosh Kazemi<sup>4</sup>, Nader Tanideh<sup>4</sup>, Leila Shayan<sup>3</sup>, Zahra Nikeghbalian<sup>5</sup>**

<sup>1</sup>Department of Transplantation, School of Medicine, Shiraz University of Medical Sciences, Shiraz, Iran

<sup>2</sup>Department of Obstetrics and Gynecology, School of Medicine, Shiraz University of Medical Sciences, Shiraz, Iran

<sup>3</sup>Trauma Research Center, Shahid Rajaei (Emtiaz) Trauma Hospital, Shiraz University of Medical Sciences, Shiraz, Iran

<sup>4</sup>Animal Laboratory, School of Medicine, Shiraz University of Medical Sciences, Shiraz, Iran

<sup>5</sup>Department of Anesthesiology, School of Medicine, Shiraz University of Medical Sciences, Shiraz, Iran

**\*Corresponding author: Farid Moradian**

Address: Trauma Research Center, Shahid Rajaei (Emtiaz) Trauma Hospital, Shiraz, Iran. PO Box: 71345-1876, Tel: +98-917-7209238; Fax: +98-71-36254206  
e-mail: moradian.farid@yahoo.com

Received: March 12, 2015

Revised: April 18, 2015

Accepted: June 3, 2015

### ► ABSTRACT

**Objectives:** To investigate the effects of intravenous infliximab in preventing the formation of peritoneal adhesions in an animal model of rat.

**Methods:** This was an experimental study being performed in animal laboratory of Shiraz University of Medical Sciences during 2012. Sixty albino rats were randomly assigned in to three groups by Random Design Method. The first group received single infliximab injection (n=20), the second one received double infliximab injection (n=20) and the third received nothing (n=20), after receiving intra-peritoneal injection of talc for induction of peritoneal adhesions. All the animals were sacrificed after 6 weeks and the peritoneal adhesions were evaluated according to Nair classification.

**Results:** We observed that the mean adhesion grade was lower in those who received double dose of infliximab when compared to single dose and controls. However the difference did not reach a significant value ( $p=0.178$ ). The grade of peritoneal adhesion was also comparable between the three study groups ( $p=0.103$ ). The mean number of 1st WBC count was also comparable between three study groups ( $p=0.382$ ). We observed that 2nd WBC count was also comparable between two study groups ( $p=0.317$ ).

**Conclusion:** Administration of intravenous infliximab after intraabdominal surgical procedures would not prevent the formation of peritoneal adhesions in animal model of albino rat.

**Keywords:** Postoperative; Tissue adhesions; Peritoneum; Infliximab; Animal models; Rats.

Please cite this paper as:

Nikeghbalian S, Vafaei H, Moradian F, Kazemi K, Tanideh N, Shayan L, Nikeghbalian Z. Administration of Intravenous Infliximab for Prevention of Peritoneal Adhesions Formation in Rats. *Bull Emerg Trauma*. 2015;3(3):97-103.

## Introduction

Peritoneal adhesions are among the most common long-term complications of the abnormal surgeries exclusively laparotomies [1]. The prevalence is estimated to be as high as 93-100% of all abdominal surgical procedures [2]. Peritoneal adhesion is worldwide complication of intraabdominal surgeries and may develop following any type on peritoneal procedure [3]. The signs and symptoms depend on the involved organ. For instance involvement of small or large intestine will result in partial or complete obstruction while involvement of female reproductive organs results in infertility, chronic pelvic pain or dyspareunia [4,5]. It has been reported that in more than 80% of patients, the adhesion bands develop between the incision site and the omentum [6]. In more 50% of the patients other organs such as intestine are also involved [7]. Peritoneal adhesions are responsible for about 70-80% of all intestinal obstructions [8].

Peritoneal adhesions are result of aberrant wound healing process secondary to mesothelial damage by the surgical procedures. Inflammation of the surgical site would result in increased collagenation and fibrosis which in a long period of time produce extensive amount of fibrotic tissue known as peritoneal adhesions [9]. In addition vascular damage during the surgical interventions on the peritoneum will result in increased vascular permeability and minor bleedings in the site of operation which in turn result in exudation of fibrinogen [5,9,10]. It has been demonstrated that in acute inflammation, the peritoneal fluid shows increased concentrations of the inflammatory and pro-inflammatory cytokines including IL-1, IL-6, IL-8 and TNF- $\alpha$  [11-13]. IL-1 and TNF- $\alpha$  are pro-inflammatory cytokines secreted by activated macrophages in peritoneal fluid following the surgical interventions [14]. Intraoperative serum levels of IL-1 and TNF- $\alpha$  has been demonstrated to be correlated with peritoneal adhesions. Thus, it is assumed that early elevations of IL-1 and TNF- $\alpha$  are reliable biological markers for postoperative adhesions in humans [14].

Infliximab is a chimeric monoclonal anti-TNF- $\alpha$  antibody which locks the immune and inflammatory system being administered as immunosuppressive agent. It has being approved for treatment of psoriasis, psoriatic arthritis, Crohn's disease, ulcerative colitis, rheumatoid arthritis and ankylosing spondylitis [15,16]. Some studies reported that intra-muscular administration of vitamin E was the most effective way to reduce adhesions but not prevent it entirely. The role of vitamin E could differ based on the intensity of the damage and mode of administration [17]. Administration of infliximab can prevent formation of peritoneal adhesion. Infliximab is associated with several side effects including leukopenia and agranulocytosis [16], WBC was count twice after the procedure to evaluate agranulocytosis due to infliximab injection. The aim of this study was to

investigate the effects of intravenous infliximab in preventing the formation of peritoneal adhesions in an animal model of rat.

## Materials and Methods

### License

The study was performed at 2011-2012 in Shiraz University of Medical Sciences trauma research center. The study was approved by the institutional review board and ethics committee of Shiraz University of Medical Sciences and the Ethics Committee of Natural Chemotherapeutics Research Laboratory of Iran's Ministry of Health. Study animals were handled in conformity with guidelines for the care and handling of laboratory animals provided by Shiraz Laboratory Animals Center in accordance with global standards for laboratory biosafety guidelines.

### Animals and Housing

Sixty Wistar-Albino rats (all males, 5-6 months of age) at Shiraz University of Medical Sciences animal research laboratory, weighing 200 to 250 g, were included in this study. The animals were purchased from the laboratory animal department of Iran's Pasteur Institute of Pharmacy. All the animals were housed individually and fed standard food throughout the experiment. The animals were initially evaluated for illness by physical examination and laboratory screening.

The animals freely lived in cages (one animal per cage) with water and standard rodent chow. They were monitored and acclimated to the new environment for 1 week. They were all housed under controlled standard laboratory conditions (temperature 24 °C, relative humidity and 12/12 hour light/dark cycle). The animals were further randomly divided to three study groups by Randomized Block Design Method to receive one intravenous injection of infliximab (n=20), two intravenous injections of infliximab (n=20) or without intravenous injection of infliximab (n=20).

### Study Protocol

All procedures were carried out under aseptic conditions. The protocols for intraperitoneal injection, postoperative care, and sacrifice were identical for all animals. None of the rats was fasted before intervention. The peritoneal adhesions were induced by intraperitoneal injection of 3 mL of a 10% sterile talc solution just after the procedure. Those who were assigned to the single dose infliximab group (n=20) received an injection of infliximab (Centocor BV, Leiden, the Netherlands) in a dosage of 3-5 mg/kg through the tail vein the day after the procedure. Those in double dose infliximab group (n=20) received two intravenous infliximab (Centocor BV, Leiden, the Netherlands) injection in a dosage 3-5 mg/kg, first dose the day after the

procedure and the second dose 2 weeks after the first dose. The rats assigned to control group (n=20) didn't receive any infliximab after the procedure. Animals were housed in individual cages. No oral feeding was given at the first postoperative day; then full alimentation was resumed after a day post-procedure. Other care was routine for the research facility.

#### Outcome Assessment

The animals were put to death by an intravenous overdose of Diethyl ether. All the 60 rats were killed at 6 weeks after intraperitoneal injection of talc. After death, laparotomy was performed through a midline incision and the abdomen was explored. The peritoneal adhesions were assessed on a 0 to 4 scale according to Nair *et al.*, [18] (Figure 1). We also measured the white blood cell (WBC) count after the procedure. The WBC count was repeated in two study groups 1 week after in order to detect possible agranulocytosis due to infliximab injection.

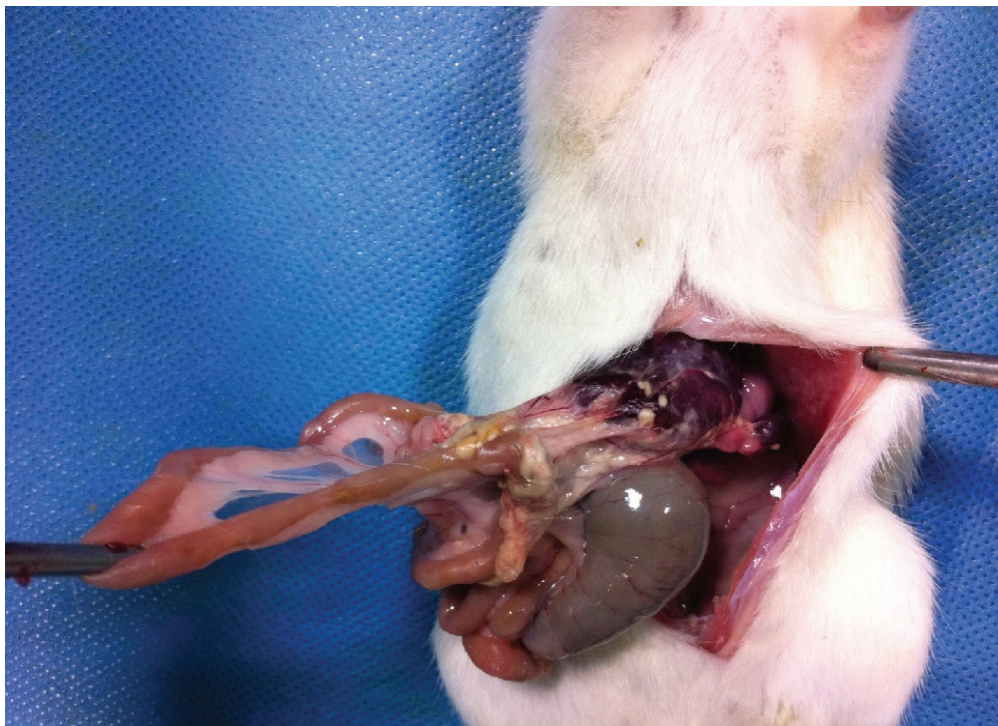
#### Statistical Analysis

The statistical package for social science, SPSS

for Windows, Version 15.0 (SPSS, Chicago, IL, USA) was used for data analysis. The grade of peritoneal adhesions was compared between three study groups using Kruskal-Wallis. The parametric data were compared using one-way analysis of variance (ANOVA) with LSD as the post Hoc test. Data are reported as the mean±SD or proportions as appropriate. A two sided *p*-value less than 0.05 was considered statistically significant.

#### Results

Overall, 60 albino rats receiving intraperitoneal injection of talc were included in the study. None of the rats died during the study period and thus the final number of animals that finished the study was 20 in each study group. None of the rats developed complications during the study. All the animals were comparable regarding the baseline characteristics including age and weight. Table 1 summarizes the grade of peritoneal adhesions in three study groups. The peritoneal adhesion grades according to study groups shown in Table 2. We observed that the mean



**Fig. 1.** Results are showing More than two adhesion bands between small intestine and viscera in an albino rat that received one dosages of infliximab after intraperitoneal injection of talc.

**Table1.** Classification of peritoneal adhesion according to Nair et al [17].

Grade	Description of adhesion bands	Remarks
0	Complete absence of adhesion	Insubstantial adhesion
1	Single band of adhesions, between viscera or from one viscus to abdominal wall	Insubstantial adhesion
2	Two bands, either between viscera or from viscera to abdominal wall	Insubstantial adhesion
3	More than two bands, between viscera or from viscera to abdominal wall; or whole intestine forming a mass without being adherent to abdominal wall	Substantial adhesion
4	Viscera directly adherent to abdominal wall, irrespective of number and extent of adhesive bands	Substantial adhesion



adhesion grade was lower in those who received two dose of infliximab when compared to single dose and controls. However the difference did not reach a significant value ( $p=0.178$ ). The grade of peritoneal adhesion was also comparable between the three study groups ( $p=0.103$ ).

The mean number of 1st WBC count was also comparable between three study groups ( $p=0.382$ ). We observed that 2nd WBC count was also comparable between two study groups ( $p=0.317$ ), (Table 3).

### Discussion

In this experimental study we tried to determine the efficacy of infliximab injection for prevention of peritoneal adhesions in an animal model of albino rat. We also compared the single dose administration of infliximab with the double dose injection. We observed that those rats receiving double dose infliximab had lower peritoneal adhesion grade when compared to single dose and controls. However the difference did not reach a significant value. The infliximab administration (nor single dose neither double dose) was not associated with lower peritoneal adhesion grade in animal model of rat. To the best of our knowledge, this is among the few studies investigating the role of intravenous infliximab in preventing the peritoneal adhesions formation. However we should indicate that the intravenous infliximab would not be an effective approach for prevention of peritoneal adhesion formation.

Surgical interventions of the abdominal and pelvic cavities cause extensive peritoneal injury leading to chemotaxis of inflammatory cells including macrophages and neutrophils which secrete extensive amounts of cytokines and inflammatory biomarkers [10,12]. In turn, fibrinogen-rich inflammatory exudates are released into the abdominal cavity and finally fibrin filaments are generated leading to peritoneal adhesion formation [8,9]. According to these aforementioned mechanisms for peritoneal adhesions formation, several strategies could be

used to prevent this event [3,4]. These include reduction of the initial inflammatory response and preventing the release of the exudates, prevention of exudates coagulation, increase the fibrinolysis process and removing the fibrinous surfaces [3-6]. Our strategy in the current study was reducing the initial inflammatory response. Thus we used infliximab as an anti-TNF- $\alpha$  antibody which blocks the initial inflammatory cascade through blocking TNF- $\alpha$ , the biological markers of peritoneal adhesion in human [14,19]. However, we could not determine and positive effects from infliximab in preventing peritoneal adhesions in an animal model of rat. Our results are in consistent with a previous report by Kaidi and colleagues [18] who investigated the effects of preoperative intravenous administration of antibodies against TNF- $\alpha$  and IL-1 on peritoneal adhesion formation. They used animal model of Sprague-Dawley rats that underwent induction of peritoneal adhesion formation using cecal serosa scratching technique. They found that peritoneal adhesions were less formed in those who were treated with a combination of anti-TNF- $\alpha$  and anti IL-1 when compared to controls. The administration of anti IL-1 alone was also associated with less peritoneal adhesion formation; however intravenous injection of anti-TNF- $\alpha$  was not found to prevent peritoneal adhesion effectively [19]. These results are similar to ours rejecting the hypothesis that administration of anti-TNF- $\alpha$  may be effective in prevention of peritoneal adhesion formation. Regarding the method of induction of peritoneal adhesion formation (cecum scratching technique) and the time of infliximab injection (postoperative vs. preoperative). But the results are comparable because these two minor differences might not affect the results significantly.

Some researchers investigated the effects of melatonin (ME) as an agent to prevent the adhesion formation, in the study Serosal injury was created using a standard technique, one group received a single dose of intraperitoneal (IP) ME immediately after injury; a single dose of subcutaneous (SC) ME

**Table 2.** Peritoneal adhesion grades according to the groups.

Grades	Control group	One dose group	Two dose group	Total
0	0	3	1	4
1	3	3	4	10
2	4	4	10	18
3	13	9	5	27
4	0	1	0	1
<b>Total</b>	20	20	20	60

**Table 3.** The mean number of 1<sup>st</sup> & 2<sup>nd</sup> WBC were count.

Groups	1 <sup>st</sup> WBC	2 <sup>nd</sup> WBC
One dose group	11755.000	11735.000
Two dose group	11930.000	12835.000
<b>Total</b>	12331.666	12285.000

was given to the second group 30 minutes prior to surgery; but the control group did not received ME. They concluded that single dose ME therapy can be effective in the prevention of post operative adhesion formation [20].

In another study that was performed on Thirty-five rats in the Faculty of Medicine, Gazi University, Turkey, Adhesion formation was evaluated with macroscopic and microscopic adhesion scoring systems. Peritoneal fluid samples and mesenteric lymph node biopsies were taken to rule out bacterial peritonitis. Blood and peritoneal irrigation fluid samples were taken to measure the Tumor necrosis factor-alpha (TNF-alpha) levels. As our results showed, Macroscopic adhesion scores showed fewer adhesions in the infliximab group. The infliximab group had significantly fewer adhesions than the abrasion control and saline groups. According to the histological findings, there were no statistically significant differences between the groups. They concluded that early blocking of the activity of TNF-alpha after cecal abrasion resulted in lower rates of adhesion formation, macroscopically. The TNF-alpha, a proinflammatory cytokine appears to be an important mediator for postoperative adhesion formation. [21]

In the Gemici *et al.* study that aimed at investigating the effect of placing hyaluronate- carboxymethyl-cellulose membrane on the formation of adhesion postoperatively in a damaged area in the peritoneum of the anterior stomach wall, suggested that the use of hyaluronate-carboxymethyl-cellulose could be beneficial on damaged peritoneum surfaces following abdominal surgery in order to reduce postoperative adhesion development to a minimum [22]. But in another experimental study, that the results was similar to ours, it was showed that orally administered simvastatin has no significant effect on preventing formation of postoperative adhesions [23].

Several approaches have been introduced for prevention of peritoneal adhesion formation including administration of fibrinolytic agents such as recombinant t -PA [24], anticoagulants [25] or gonadotrophin releasing hormone agonist (GnRH $\alpha$ ) [26], applying immunomodulation by using transforming growth factor (TGF)- $\beta$ -1 antibodies [27], IL-1 and TNF- $\alpha$  antibodies [28], or IL-10 and ketorolac (NSAID) [29] and disruption of cell interaction with extra-cellular matrix (ECM) [30]. We have previously demonstrated that oral D-penicillamine is as effective as oral colchicine in prevention of peritoneal adhesion band formation in rats [31]. Several other herbal agents have also been used effectively in prevention of peritoneal adhesion formation including aloe vera gel [32], micronized purified flavonoid fraction [33] and chitosan [34]. However these have been tested in animal models

and clinical studies are scarce. In humans, the surgical approaches have been shown to be effective in prevention of adhesion formation. In this regards, it has been recommended that as less invasive the procedure is, the least risk of peritoneal adhesion exists [3,4]. Thus it is recommended to minimize the incision of the peritoneum [35], use humid environments [36], minimize the tissue trauma and hemorrhage [30] and reduce the manipulation of the surgical site and structures [36]. These approaches could lead to appropriate risk reduction of peritoneal adhesion formation in humans.

In gonzales-Gay *et al.* study that Thirty-four RA patients fulfilled the inclusion criteria. Following infliximab infusion a reduction of the overall mean values of the five adhesion molecules was observed. However, when a Wilcoxon signed-rank test was used, only significant differences for sICAM-3 and sP-selectin were observed. In this regard, sICAM-3 and sP-selectin levels fell in 26 (77%) and 28 (82%) of the 34 patients. Since their the purpose of this study was to assess the potential immediate effect of anti-TNF- $\alpha$  infliximab administration on serum levels of soluble adhesion molecules in RA patients on periodical treatment with this drug, their study confirms a rapid and beneficial effect of infliximab infusion on expression of some adhesion molecules in RA patients treated periodically with this anti-TNF- $\alpha$  monoclonal antibody because of severe disease [37]. We was not able to buy enough Infliximab doses for 30 rats because of expensiveness and boycott of Infliximab in iran, this limitation made us to use 20 rats. Infliximab is associated with several side effects including leukopenia and agranulocytosis [16] and indeed, it is very expensive. These disadvantages, limit the use of infliximab in clinical practice and as our study as well as previous report [19] has demonstrated, its administration for prevention of peritoneal adhesion formation should be prohibited.

In conclusion, intravenous administration of infliximab after intraabdominal surgical procedures would not prevent the formation of peritoneal adhesions in animal model of albino rat.

### Acknowledgment

This article is extracted from a thesis for partial fulfillment of the requirements for the degree of specialty in general surgery written by Dr. Farid Moradian. We would like to acknowledge the personnel of Shiraz animal laboratory for their assistance. We would also like to acknowledge Dr. Fariborz Ghaffarpasand assistance in English and scientific content editing.

**Conflict of interest:** None declared.

## References

1. Brüggmann D, Tchertchian G, Wallwiener M, Münstedt K, Tinneberg HR, Hackethal A. Intra-abdominal adhesions: definition, origin, significance in surgical practice, and treatment options. *Dtsch Arztebl Int.* 2010;**107**(44):769-75.
2. Ouaisi M, Gaujoux S, Veyrie N, Deneve E, Brigand C, Castel B, et al. Post-operative adhesions after digestive surgery: their incidence and prevention: review of the literature. *J Visc Surg.* 2012;**149**(2):e104-14.
3. Liakakos T, Thomakos N, Fine PM, Dervenis C, Young RL. Peritoneal adhesions: etiology, pathophysiology, and clinical significance. Recent advances in prevention and management. *Dig Surg.* 2001;**18**(4):260-73.
4. Attard JA, MacLean AR. Adhesive small bowel obstruction: epidemiology, biology and prevention. *Can J Surg.* 2007;**50**(4):291-300.
5. Dijkstra FR, Nieuwenhuijzen M, Reijnen MM, van Goor H. Recent clinical developments in pathophysiology, epidemiology, diagnosis and treatment of intra-abdominal adhesions. *Scand J Gastroenterol Suppl.* 2000;(232):52-9.
6. Holmdahl L, Eriksson E, Rippe B, Risberg B. Kinetics of transperitoneal tissue-type plasminogen activator absorption. *Fibrinolysis.* 1996;**10**(1):1-7.
7. Senthilkumar MP, Dreyer JS. Peritoneal adhesions: pathogenesis, assessment and effects. *Trop Gastroenterol.* 2006;**27**(1):11-8.
8. Reed KL, Fruin AB, Bishop-Bartolomei KK, Gower AC, Nicolaou M, Stucchi AF, et al. Neurokinin-1 receptor and substance P messenger RNA levels increase during intraabdominal adhesion formation. *J Surg Res.* 2002;**108**(1):165-72.
9. Cheong YC, Laird SM, Li TC, Shelton JB, Ledger WL, Cooke ID. Peritoneal healing and adhesion formation/reformation. *Hum Reprod Update.* 2001;**7**(6):556-66.
10. Fieren MW. The local inflammatory responses to infection of the peritoneal cavity in humans: their regulation by cytokines, macrophages, and other leukocytes. *Mediators Inflamm.* 2012;**2012**:976241.
11. Sanz AB, Aroeira LS, Bellon T, del Peso G, Jimenez-Heffernan J, Santamaria B, et al. TWEAK promotes peritoneal inflammation. *PLoS One.* 2014;**9**(3):e90399.
12. Zemel D, Koomen GC, Hart AA, ten Berge IJ, Struijk DG, Krediet RT. Relationship of TNF-alpha, interleukin-6, and prostaglandins to peritoneal permeability for macromolecules during longitudinal follow-up of peritonitis in continuous ambulatory peritoneal dialysis. *J Lab Clin Med.* 1993;**122**(6):686-96.
13. Cahill RA, Redmond HP. Cytokine orchestration in post-operative peritoneal adhesion formation. *World J Gastroenterol.* 2008;**14**(31):4861-6.
14. Kawalec P, Mikrut A, Wiśniewska N, Pilc A. Tumor necrosis factor- $\alpha$  antibodies (infliximab, adalimumab and certolizumab) in Crohn's disease: systematic review and meta-analysis. *Arch Med Sci.* 2013;**9**(5):765-79.
15. D'Souza A, Meissner BL, Tang B, McKenzie RS, Piech CT. Effectiveness of anti-tumor necrosis factor agents in the treatment of rheumatoid arthritis: observational study. *Am Health Drug Benefits.* 2010;**3**(4):266-73.
16. Bai J, Liu H, Li D, Cui L, Wu X. Duodenum clamping trauma induces significant postoperative intraperitoneal adhesions on a rat model. *PLoS One.* 2012;**7**(11):e49673.
17. Aram S, Mostajeran F, Shahraki AD, Adibi S, Shamloo S. Effect of vitamin E on decreasing post-operative adhesion in rat uterine horn. *Journal of Research in Medical Sciences.* 2012;**17**.
18. Kaidi AA, Gurchumelidze T, Nazzal M, Figert P, Vanterpool C, Silva Y. Tumor necrosis factor-alpha: a marker for peritoneal adhesion formation. *J Surg Res.* 1995;**58**(5):516-8.
19. Kaidi AA, Nazzal M, Gurchumelidze T, Ali MA, Dawe EJ, Silva YJ. Preoperative administration of antibodies against tumor necrosis factor-alpha (TNF-alpha) and interleukin-1 (IL-1) and their impact on peritoneal adhesion formation. *Am Surg.* 1995;**61**(7):569-72.
20. Ara C, Kirimlioglu H, Karabulut AB, Coban S, Hascalik S, Celik O, et al. Protective effect of melatonin against oxidative stress on adhesion formation in the rat cecum and uterine horn model. *Life Sci.* 2005;**77**(12):1341-50. PubMed PMID: 15958275.
21. Kurukahvecioglu O, Koksall H, Gulbahar O, Erdem O, Engin D, Yazicioglu O, et al. Infliximab "TNF-alpha antagonist" decreases intraabdominal adhesions. *Saudi Med J.* 2007;**28**(12):1830-5.
22. Gemici K, Kucukpinar T, Cifter C, Okus A, Ay S. The effect of hyaluronate-carboxymethyl-cellulose on the formation of postoperative adhesion in stomach visceral peritoneum damage. *Bratisl Lek Listy.* 2014;**115**(12):749-52.
23. Yildiz MK, Okan I, Dursun N, Bas G, Alimoglu O, Kaya B, et al. Effect of orally administered simvastatin on prevention of postoperative adhesion in rats. *Int J Clin Exp Med.* 2014;**7**(2):405-10.
24. Arikan S, Adas G, Barut G, Toklu AS, Kocakusak A, Uzun H, et al. An evaluation of low molecular weight heparin and hyperbaric oxygen treatment in the prevention of intra-abdominal adhesions and wound healing. *Am J Surg.* 2005;**189**(2):155-60.
25. Schindler AE. Gonadotropin-releasing hormone agonists for prevention of postoperative adhesions: an overview. *Gynecol Endocrinol.* 2004;**19**(1):51-5.
26. Chegini N. The role of growth factors in peritoneal healing: transforming growth factor beta (TGF-beta). *Eur J Surg Suppl.* 1997;(577):17-23. Review. PubMed PMID: 9076448.
27. Cahill RA, Redmond HP. Cytokine orchestration in post-operative peritoneal adhesion formation. *World J Gastroenterol.* 2008;**14**(31):4861-6.
28. Hellebrekers BW, Trimbo-Kemper TC, Trimbo JB, Emeis JJ, Kooistra T. Use of fibrinolytic agents in the prevention of postoperative adhesion formation. *Fertil Steril.* 2000;**74**(2):203-12.
29. Rout UK, Saed GM, Diamond MP. Expression pattern and regulation of genes differ between fibroblasts of adhesion and normal human peritoneum. *Reprod Biol Endocrinol.* 2005;**3**:1.
30. Nikeghbalian S, Atefi S, Kazemi K, Roshan N, Tanideh N, Jalaieian H. Effect of oral D-penicillamine vs. colchicine on experimentally induced peritoneal adhesions in rats. *Fertil Steril.* 2007;**88**(4 Suppl):1187-9.
31. Aysan E, Bektas H, Ersoz F. A new approach to postoperative peritoneal adhesions: prevention of peritoneal trauma by aloe vera gel. *Eur J Obstet Gynecol Reprod Biol.* 2010;**149**(2):195-8.
32. Yilmaz HG, Tacyildiz IH, Keles C, Gedik E, Kilinc N. Micronized purified flavonoid fraction may prevent formation of intraperitoneal adhesions in rats. *Fertil Steril.* 2005;**84** Suppl 2:1083-8.
33. Zhang ZL, Xu SW, Zhou XL. Preventive effects of chitosan on

- peritoneal adhesion in rats. *World J Gastroenterol.* 2006;**12**(28):4572-7.
34. Gutt CN, Oniu T, Schemmer P, Mehrabi A, Büchler MW. Fewer adhesions induced by laparoscopic surgery? *Surg Endosc.* 2004;**18**(6):898-906.
35. van Goor H. Consequences and complications of peritoneal adhesions. *Colorectal Dis.* 2007;**9** Suppl 2:25-34.
36. Schafer M, Krahenbuhl L, Buchler MW. Comparison of adhesion formation in open and laparoscopic surgery. *Dig Surg.* 1998;**15**(2):148-52.
37. Gonzalez-Gay MA, Garcia-Unzueta MT, De Matias JM, Gonzalez-Juanatey C, Garcia-Porrúa C, Sanchez-Andrade A, et al. Influence of anti-TNF-alpha infliximab therapy on adhesion molecules associated with atherogenesis in patients with rheumatoid arthritis. *Clin Exp Rheumatol.* 2006;**24**(4):373-9.