

Case Report

Vital Pulp Therapy of an Immature Traumatized Permanent Tooth with External Inflammatory Root Resorption, a Case Report

Sahebi S^a; Pourhatami N^b; Ahzan SH^b

^a Associate Professor, Department of Endodontics, School of Dentistry, Shiraz University of Medical Sciences, Shiraz, Iran

^b Postgraduate Student, Department of Endodontics, School of Dentistry, Shiraz University of Medical Sciences, Shiraz, Iran

ARTICLE INFO

Article History:

Received: 5 March 2018

Accepted: 13 May 2018

Key words:

External inflammatory root resorption

Dental trauma

Vital pulp therapy

Mineral trioxide aggregate

Corresponding Author:

Negar Pourhatami

Postgraduate Student,

Department of Endodontics,

School of Dentistry, Shiraz

University of Medical Sciences,

Shiraz, Iran

Email: pourhatamn@sums.ac.ir

Tel: +98-9177382620

Abstract

External inflammatory root resorption is a serious complication of a dental trauma, which leads to progressive loss of the tooth structure and destruction of periodontal tissues. Therefore, it represents a challenge in endodontic practice especially in cases of young children with incomplete root development. Vital pulp therapy (VPT) is an appropriate technique in the management of immature permanent teeth with partial pulp necrosis. This case report describes the outcome of a successful VPT in an immature traumatized permanent tooth with concurrent associated partial necrosis and external root resorption limited to the coronal part of the root in a 7-year-old boy. The tooth was treated according to the protocol suggested by American Association of Endodontics (AAE), consisted of disinfecting the root canal system beyond the resorptive lesion. Afterwards, mineral trioxide aggregate (MTA) was packed into the coronal portion of the canal and the tooth was restored with composite resin. The radiographic follow-up at 3 months showed arrest of root resorption followed by re-establishment of the periodontal space at 6 and 12 months in the absence of clinical symptoms. The satisfactory outcome of this case suggests that this conservative approach can heal a partially necrotic pulp and create a favorable environment for continued root development, and arrest of the resorptive process.

Cite this article as: Sahebi S , Pourhatami N , Ahzan SH. Vital Pulp Therapy of an Immature Traumatized Permanent Tooth with External Inflammatory Root Resorption, a Case Report .J Dent Biomater, 2018;5(2):583-587.

Introduction

The completion of root development and closure of the apex occur up to 3 years after eruption of the tooth in the oral cavity. Dental caries, trauma, and anomalous tooth morphology such as dens evaginatus

are potential causes of pulpal and periapical diseases [1]. Most dental traumas occur in the 7 - 10 year-old age group with incomplete root development [2]. Immature traumatized teeth may become infected through crown fractures or cracks [3]. Bacterial invasion gradually promotes inflammation of the

pulp tissue, and if not treated, pulp necrosis will happen, leading to destruction of odontoblasts and cessation of the root development. The outcomes of the interrupted root development include a poor crown-root ratio, a root with very thin walls, an increased risk of fracture, and an open apex [4]. External inflammatory root resorption is one of the potential consequences of trauma to the teeth and occurs when there has been loss of cementum due to damage to the external surface of the root and concurrent bacterial infection of the root canal system. The loss of cementum causes reaching intracanal bacteria and their byproducts to the adjacent periodontal ligament (PDL) and bone and this can ultimately lead to the development of the inflammatory resorptive process [5].

Conventional treatment of external inflammatory root resorption is based on eliminating bacteria and their irritants from dentinal tubules and the entire root canal system by means of thorough chemomechanical preparation of the canal space and a short-term dressing of creamy paste of calcium hydroxide for disinfection, followed by a long-term dressing with densely packed calcium hydroxide until cessation of the resorptive process [6,7]. Although documented data show that long-term calcium hydroxide therapy for this situation has a high success rate and stimulates hard tissue formation at the root apex of immature teeth with external inflammatory root resorption induced by trauma, the time-consuming nature of this method, weakening of the root structure and necrotizing effect of calcium hydroxide on PDL cells are some complicating disadvantages [8]. Regenerative endodontic therapy has been suggested to be an appropriate therapeutic technique in the management of immature permanent teeth with total pulpal necrosis. In 2004, Banchs & Trope published a case report describing this new approach for the treatment of an immature necrotic tooth and called it revascularization [9]. Vital pulp therapy (VPT) of permanent teeth includes partial/coronal extirpation of dental pulp tissue and covering the remaining wound with dental biomaterials. The ultimate goal of this approach is preservation of the healthy portion of the pulp tissue, and therefore maintaining its healing ability [10]. VPT is an ideal therapeutic technique in the management of immature permanent teeth

with partial pulpal necrosis and has the potential to allow for continuation of root development and thickening of dentinal walls [11]. Thus, the objective of the current case was to determine if the presented protocol would result in the formation of a longer and thicker root in a tooth believed to exhibit a partial loss of vital pulp tissue with associated external root resorption.

Case Report

A 7-year-old boy was referred to the Department of Endodontics due to the history of impact trauma to the anterior region of maxilla three days earlier. The medical history was unremarkable. Clinical examination showed uncomplicated crown fractures with no pulpal exposures of both maxillary central incisors. Sensitivity to percussion and no response to cold and electric pulp tests were observed in both teeth. Radiographic examination revealed that the fractured teeth had immature apices (Figure 1A). Based on clinical and radiographic examinations, the treatment plan was dentin coverage with glass ionomer cement (GC, Tokyo, Japan) and permanently restoring the teeth with composite resin (Filtek Z350, 3M ESPE, St. Paul, MN, USA). Oral hygiene instruction was provided, and the patient and his parents were told that they should come to the clinic immediately if there was pain or swelling on each of the traumatized teeth. At the recall appointments (2 weeks, 1, 2, 3, and 4 months), both maxillary central incisors were asymptomatic, although none of them respond to cold and electric pulp tests. In addition, no abnormalities were found in radiographs of both teeth. When the patient was recalled 5 months after the first visit, the teeth were asymptomatic but in clinical examination, the maxillary left central incisor was sensitive to percussion and palpation and showed the probing depth of 5 mm at the distal surface of its root. No response to vitality tests was detected. Radiographic examination revealed that the tooth had still an immature apex. Moreover, external inflammatory root resorption at the coronal part of distal root wall of the mentioned tooth was obvious (Figure 1B). The initial diagnosis of pulpal necrosis was established based on clinical and radiographic examinations. The parents were informed that the prognosis of the tooth would be

highly unfavorable and the treatment would be an attempt to extend the tooth life. It was decided to accomplish the treatment according to the clinical protocol recommended by AAE for the management of external inflammatory root resorption at the first appointment by chemomechanical preparation of the entire root canal system. Local anesthesia using 2 % lidocaine with 1:100000 epinephrine (DarouPakhsh, Tehran, Iran) was administered and tooth #9 was isolated with rubber dam. Access cavity preparation was made utilizing a high speed handpiece with water-coolant. While a size #15 k file (K-file, Mani Corp, Tochigi, Japan) was inserted into the coronal two thirds of the canal, hemorrhage into the pulp chamber was observed and the patient reported discomfort, potentially indicating the survival of the residual pulp tissue. The clinical diagnosis was revised from total pulpal necrosis to partial necrosis. After evaluating the treatment options, it was established that the patient would benefit greatest from maintaining the viability of the remaining portion of pulp tissue through VPT. Then parents were comprehensively informed about the benefits, complications, and alternative treatment approaches (apexification and regenerative endodontic therapy) and the relevant consent was obtained. The coronal portion of the canal was irrigated with 10 ml of 5.25% NaOCl

and then rinsed with sterile saline solution. No instrumentation was performed. White mineral trioxide aggregate (MTA) (ProRoot MTA, Dentsply, Tulsa, OK, USA) was gently packed into the coronal portion of the canal beyond the resorptive lesion. The access cavity was sealed with 4 mm of cavisol (Golchai, Karaj, Iran). One day later, the temporary restoration was removed from the tooth #9, and access cavity was refined and restored with composite resin (Figure 1C). The patient returned two weeks later, asymptomatic with no sensitivity to percussion and palpation. No significant radiographic changes were noted. At the 3-month post-op visit, the patient was asymptomatic. Tests for percussion, palpation, mobility and probing depth were all within normal limits for tooth # 9. Decreasing the diameter of the apex and thickening of the radicular walls were evident radiographically in this tooth. The resorptive process was arrested, and interestingly a dentinal bridge was seen at the site of vital pulp therapy (Figure 1D). At the 4-month post-op recall, a sinus tract was observed on the buccal mucosa of tooth #8. No caries were clinically detected in this tooth. Neither teeth #8 nor #9 were sensitive to palpation, percussion and vitality tests. Radiographically, in tooth #9, the lamina dura could be traced around the entire root surface and

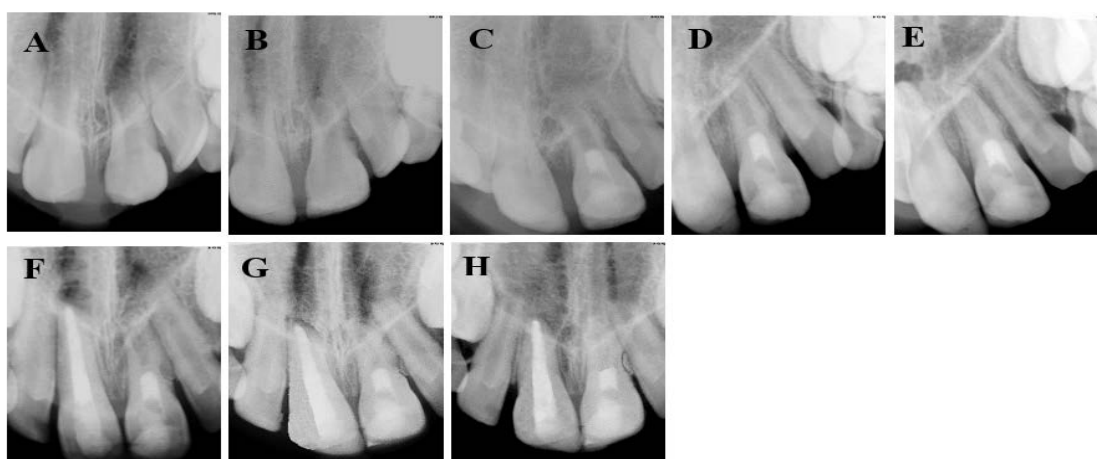


Figure 1: (A) The first-visit radiograph of teeth # 8 and # 9 with uncomplicated crown fractures. (B) Preoperative radiograph of tooth # 9 with external root resorption (C) Postoperative radiograph after VPT of tooth # 9 (D) 3-month post-op follow-up with a dentinal bridge formation at the site of VPT in tooth # 9 (E) 4-month post-op follow-up; in tooth # 9 the inflammatory root resorption was stopped and the lamina dura could be traced around the entire root surface Tooth # 8 had a radiolucent periapical lesion (F) Immediately after obturation of tooth # 8 with MTA plug and thermoplastic gutta percha (G) 6-month post-op follow-up (H) 12-month post-op follow-up; in tooth # 9, a longer and thicker root could be seen and the resorptive lacuna was filled with newly formed bone Re-establishment of a normal periodontal condition could be seen around the whole root surfaces of teeth # 8 and # 9

the periodontal ligament space was re-established. However, tooth #8 had a periapical radiolucent lesion (Figure 1E). The definitive diagnosis for tooth #8 based on clinical and radiographic examinations was total pulpal necrosis with asymptomatic apical abscess. Because of an absence of apical stop, it was decided to place an MTA plug and the rest of the canal was obturated with thermoplastic gutta percha using Obtura III gun (Courtesy Kerr, Orange, CA) (Figure 1F). At the 6- and 12-month follow up visits, no tenderness to percussion and palpation was noted in treated teeth. Periodontal pocket depths and mobility were within normal limits for both teeth. The cold and electric pulp tests were negative for tooth #9. Radiographic findings were also normal for the traumatized teeth (Figure 1G, H).

Discussion

External inflammatory root resorption is an important complication of a traumatic injury [12]. Normally an intact tooth is resistant to resorption even in the presence of inflammation. However, when an impact trauma damages the protective layer of precementum, inflammation of the pulp or periodontium will motivate root resorption. The aim of the interceptive treatment of external inflammatory root resorption is to reduce PDL inflammation, inhibit clastic cells, eliminate bacteria and their byproducts in the root canal system and encourage healing of periradicular hard tissues [5]. Historically, the conventional treatment of such cases was performed using long-term calcium hydroxide therapy to stop the resorptive process by making alkaline pH in dentinal tubules for killing bacteria and neutralizing their endotoxins, which are potent stimulators of inflammatory process [6]. Despite a high success rate, multiple patient visits, low patient compliance, probability of canal contamination between visits, and increased risk of root fracture due to dentin brittleness are some disadvantages of this protocol. Additionally, the necrotizing effect of calcium hydroxide on PDL cells might result in replacement resorption and ankylosis [8]. One-visit apexification by using MTA as an apical barrier is another alternative approach and may shorten the treatment time. Although MTA is effective in promoting new hard

tissue formation in the apical area of the affected immature teeth, the risk of future fracture may still exist, because the dentin thickness will not increase. Therefore, the long-term prognosis of such teeth will be compromised [13]. In the present case, after access cavity preparation and inserting a size # 15 k file into the coronal two thirds of the canal, hemorrhage into the pulp chamber was observed, meaning that although the part of pulp tissue adjacent to the resorptive lesion was necrotic, the residual pulp tissue was vital. VPT was regarded the optional treatment choice for this case considering the stage of root development, the thin dentinal walls and the wide open apex. The interesting successful outcome in this case indicates that the management of external inflammatory root resorption in an immature tooth with partial necrosis does not necessitate the clinician to eliminate the entire pulp tissue from the root canal space, similar to what happens in regenerative endodontic therapy or the apexification process. Indeed, the conventional treatment of a tooth with external inflammatory root resorption is complete root canal therapy. However, the findings of this case report revealed that maintaining the vital apical portion of the pulp even in the presence of inflammation, in a tooth with immature apex, can improve the chance of root development and its long-term prognosis. The satisfactory outcome of the current case can be explained as the diseased residual pulp tissue, which probably had the granulation tissue nature, was healed after inflammation control and pulp protection with MTA through VPT, and subsequently promoted root end closure. In fact, VPT was selected to treat our patient because it is considered as an adequate conservative approach in a trauma victim. VPT allows further root maturation by sustaining a viable Hertwig's epithelial root sheath, which is responsible for signaling the physiological development of the root [10]. The presence of bacteria and their byproducts in the root canal system is one of the most substantial reasons for VPT failure. Therefore, a tight seal against bacterial ingress to the pulp tissue space may warrant the success of VPT [11]. Previous reports demonstrated that the pulp tissue has an inherent ability for soft tissue healing and hard tissue formation under different dental biomaterials [14, 15]. MTA was

used in this study to provide an effective pulpal seal. Releasing of calcium hydroxide, exponential marginal adaptation, and inducing the release of bioactive proteins from dentin matrix, make MTA a potentially favorable biomaterial in the treatment of external inflammatory root resorption [16]. The deposition of hard tissue bridge beneath MTA in the present case, appears to be due to the stimulation of dental pulp stem cells proliferation and cell migration from stem cells of apical papilla with subsequent differentiation.

Conclusions

In conclusion, the current case report demonstrates a successful VPT of an immature traumatized permanent tooth with external inflammatory root resorption and partial necrosis based on clinical and radiographic evidence. In spite of a poor prognosis at the beginning of treatment, this approach caused healing of a progressive external root resorption within 12 months regarding the re-establishment of a normal periodontal condition, and a stronger and longer mature root. Further large-scale clinical trials with long-term follow-up periods are required to confirm this protocol.

Conflict of Interest: None declared.

References

- Cehreli ZC, Isbitiren B, Sara S, *et al.* Regenerative endodontic treatment (revascularization) of immature necrotic molars medicated with calcium hydroxide: a case series. *J Endod.* 2011;37:1327-30.
- Bastone EB, Freer TJ, McNamara JR. Epidemiology of dental trauma: a review of the literature. *Aust Dent J.* 2000;45:2-9.
- Sundqvist G, Figdor D. Life as an endodontic pathogen. *Endod Topics.* 2003;6:3-28.
- Cotti E, Mereu M, Lusso D. Regenerative treatment of an immature, traumatized tooth with apical periodontitis: report of a case. *J Endod.* 2008;34:611-6.
- Abbott PV. Prevention and management of external inflammatory resorption following trauma to teeth. *Aust Dent J.* 2016;61:82-94.
- Fuss Z, Tsesis I, Lin S. Root resorption—diagnosis, classification and treatment choices based on stimulation factors. *Dent Traumatol.* 2003;19:175-82.
- Rafter M. Apexification: a review. *Dent Traumatol.* 2005;21:1-8.
- Hammarström L, Blomlöf L, Feiglin B, *et al.* Effect of calcium hydroxide treatment on periodontal repair and root resorption. *Dent Traumatol.* 1986;2:184-9.
- Banchs F, Trope M. Revascularization of immature permanent teeth with apical periodontitis: new treatment protocol? *J Endod.* 2004;30:196-200.
- Ingle JI, Bakland L, Baumgartner J, *et al.* *Ingles endodontics* 6th ed. Hamilton, ON: BC Decker Inc. 2008:1348-51.
- JOE Editorial Board. Vital pulp therapy: an online study guide. *J Endod.* 2008;34:e103-6.
- Trope M. Root resorption due to dental trauma. *Endod Topics.* 2002;1:79-100.
- Steinig TH, Regan JD, Gutmann JL. The Use And Predictable Placement Of Mineral Trioxide Aggregate In One-Visit Apexification Cases. *Aust Endod J.* 2003;29:34-42.
- Ford TR, Torabinejad M, Abedi HR, *et al.* Using mineral trioxide aggregate as a pulp-capping material. *J Am Dent Assoc.* 1996;127:1491-4.
- Schuurs AH, Gruythuysen RJ, Wesselink PR. Pulp capping with adhesive resin-based composite vs. calcium hydroxide: a review. *Endod Dent Traumatol.* 2000;16:240-50.
- Torabinejad M, Parirokh M. Mineral trioxide aggregate: a comprehensive literature review--part II: leakage and biocompatibility investigations. *J Endod.* 2010;36:190-202.