

**Original Article****The Expression of B7-H3 Molecule in Periodontal Disease**

Saumya John<sup>1</sup>, Arun Kurumathur<sup>2</sup>, Avaneendra Talwar<sup>2</sup>, Keerthana Kumar<sup>2</sup>, Teenu Abraham<sup>2</sup>, Ananthi Alagiri<sup>2</sup>, Gnanasagar Walaja<sup>2</sup>, Jasmine Clements<sup>2</sup>

<sup>1</sup> Dept. of Periodontics, Pushpagiri College of Dental Sciences, Kerala University of Health Sciences, Kerala, India.

<sup>2</sup> Dept. of Periodontics & Implantology, Ragas Dental College, Tamil Nadu Dr MGR Medical University, Tamil Nadu, India

**KEY WORDS**

B7-H3;  
Periodontitis;  
Immunohistochemistry;

Received August 2015;  
Received in Revised form September 2015;  
Accepted February 2015;

**ABSTRACT**

**Statement of the Problem:** T cells have been shown to play a role in the etiopathogenesis of periodontal disease. B7-H3, a costimulatory molecule, is found to be associated with regulation of T cell function in some tumoral tissues, as well as autoimmune and inflammatory diseases.

**Purpose:** The aim of this study was to investigate the expression of B7-H3 molecule in healthy and diseased gingival tissue samples.

**Materials and Method:** Gingival samples were taken from 2 groups (A and B) representing periodontal health and periodontal disease, respectively. These were paraffinized and processed to carry out immunostaining to identify B7-H3 expression. The slides were then examined under light microscope to assess the positive staining in epithelium and connective tissue. The intensity of positive staining in epithelium and the number of positive cells in the connective tissue were evaluated. Statistical analysis was done using kappa analysis and independent t-test.

**Results:** Kappa analysis revealed good inter-examiner agreement for both the groups (group A: 0.718; group B: 0.797). Intensity of staining in the epithelium ranged from intense to moderate for both the groups. In the connective tissue, there was a statistically insignificant decrease ( $p$  value= 0.415) in the number of positive cells from group A (mean labeling index:  $50.28 \pm 26.09$ ) to group B (mean labeling index=  $41.37 \pm 25.29$ ).

**Conclusion:** B7-H3 molecule has been found to be expressed in gingival tissue samples; however, it showed a statistically insignificant decrease in periodontal disease group compared to healthy group.

**Corresponding Author:** John S., Dept. Periodontics, Pushpagiri College of Dental Sciences, Kerala University of Health Sciences, Kerala, India. Email: drsaumyajohn85@gmail.com

**Cite this article as:** John S., Kurumathur A., Talwar A., Kumar K., Abraham T., Alagiri A., Walaja G., Clements J. The Expression of B7-H3 Molecule in Periodontal Disease. *J Dent Shiraz Univ Med Sci.*, 2017 March; 18(1): 1-6.

**Introduction**

Periodontal disease is a chronic, non-resolving inflammatory lesion that may result in the destruction of the tooth supporting structures. Although bacteria are thought to initiate the inflammatory response, the tissue destruction is believed to be largely mediated by the host response. [1]

The host response involves a complex interplay of several cell types of the innate and adaptive immune responses. T cells are believed to play a critical role in the etiopathogenesis of periodontal disease by regulatio-

n of both tissue homeostasis and inflammatory/ immune responses. [2-3]

T cell differentiation and activation is a two-step process. The initial step involves antigen recognition by antigen presenting cells (APCs) and subsequent presentation to the T cell receptor. This is followed by ligation of costimulatory molecules belonging to the B7 family on APCs to their receptors on T cells: CD28 and CTLA4. [4] Costimulation is essential for optimal differentiation and prevention of T cell apoptosis/ anergy.

The traditional costimulatory molecules such as

CD80 (B7-1) and CD86 (B7-2) were thought to be primarily stimulatory in function. T cell activation or inactivation was thought primarily to be the function of the receptors such as CD28 or CTLA4 to which these costimulatory molecules adhere. In recent years, it has been realized that costimulatory molecules may play dual functions. Evidence for this gained strength with the expansion of the family of costimulatory molecules to include newer members such as inducible costimulator ligand (ICOS-L), programmed death-1 ligand (PD-L1), programmed death- 2 ligand (PD-L2), B7-H3, and B7-H4. [5] Of these costimulatory molecules, there is extensive literature regarding B7-1 and B7-2 in gingival tissue. [6-8] These molecules have been reported to promote Th1 and Th2 responses respectively, along with other factors. However, the role of newer members of the B7 family is not yet well recognized. Recently, increased expression of PD-1 has been noted in gingival tissues of patients with chronic periodontitis and is reportedly involved in regulation of T cell responses. [9]

B7-H3 is a new member of the B7 family, whose expression can be induced in activated dendritic cells, lymphocytes, and synovial-like fibroblast. [10] This costimulatory molecule has been proposed to play a role in the etiopathogenesis of non-linear inflammatory diseases such as rheumatoid arthritis and asthma. [10-11] The role of B7-H3 in T cell function is yet to be fully understood. Though an earlier study demonstrated a stimulatory function, subsequent studies have shown that B7-H3 mediated an inhibitory as well as a stimulatory effect on T cells. [12-15]

The expression of B7-H3 in periodontal tissue and its role, if any, in periodontal disease pathogenesis have not yet been documented. Thus, the aim of the present study was to investigate its expression in healthy and diseased gingival tissue samples.

## Materials and Method

### Subjects

Thirty subjects selected from the patient pool attending the outpatient clinic, Department of Periodontics, Ragas Dental College and Hospital, were enrolled in the study between January and July of 2011. Subjects exhibiting good general health with no history of smoking or periodontal treatment or antimicrobial therapy for the past 6 months were chosen for the study. The subjects were

divided into two groups. Group A consisted of 15 subjects (5 males and 10 females; age: 20 to 50 years; mean 35.6 years) with clinically healthy gingiva (probing depth [PD]  $\leq$  3 mm; no clinical attachment loss [CAL]; no bleeding on probing and minimum 20 teeth). Group B consisted of 15 subjects (7 males and 8 females; age: 20 to 65 years; mean 45.7 years) with chronic generalized periodontitis (PD  $\geq$  5mm, CAL  $\geq$  3mm in at least six sites and minimum 20 teeth). [16] The study protocol was approved by the Institutional Review Board of Ragas Dental College and Hospital, and a written informed consent was obtained from each subject in accordance with the principals of good clinical practice and the *Declaration of Helsinki*.

### Tissue Collection

Gingival samples were collected from subjects in group A during the crown lengthening procedure. In the group B subjects, gingival samples were taken during periodontal surgery after completion of phase I therapy, from sites with the deepest PD. [17-18] The patients were evaluated for persistent disease activity based on the clinical parameters of PD  $\geq$  5mm and CAL  $\geq$  3mm after completion of phase I therapy. The samples were taken after a thorough phase I therapy to reduce the tissue friability during their collection and processing.

The tissues obtained from the subjects were fixed with 10% neutral buffered formalin and paraffinized. Sections that were 4 microns thick were made from the specimens and mounted on APES (3-aminopropyltriethoxysilane) pretreated slides to carry out immunohistochemistry. Sections were also made from same paraffin blocks for hematoxylin and eosin stained slides to confirm the gingival specimens.

### Immunohistochemistry

The sections for immunochemistry were deparaffinized using xylene following which rehydrated in descending series of isopropanol (100%, 70% and 50%). Antigen retrieval was carried out using EDTA (ethylene diamino tetraacetic acid), by autoclaving at a temperature of 121°C and pressure of 20 psi for 15 minutes. The slides were cooled to room temperature and treated with 3% hydrogen peroxide for 10 minutes to quench endogenous peroxidase activity, then put in one change of PBS (phosphate buffer saline) and treated with avidin blocking agent for 15 minutes. Slides were rinsed in PBS and treated with biotin blocking agent for 15 minutes. Avi-

din and biotin blocking agents were used to suppress endogenous avidin binding activity (EABA). Slides were again rinsed in PBS.

The primary antibody, polyclonal goat antihuman B7-H3 (R&D Systems, USA) was added to the tissue and the slides were incubated overnight at 2-8°C. The slides were then washed in three changes of cold PBS for 5 minutes to remove the excess antibody. From the secondary antibody kit (R&D Systems, USA), a drop of biotinylated secondary antibody was added onto the sections and the slides were incubated for 1 hour after which they were washed in three changes of cold PBS for 15 minutes each and wiped carefully without touching the tissue section to remove excess PBS. Then a drop of HSS- HRP (high sensitive streptavidin- horse radish peroxidase conjugate) from the kit was added onto the sections and incubated for 30 minutes. The sections were then washed in three changes of cold PBS for 2 minutes each and wiped carefully to remove excess PBS. A drop of freshly prepared DAB (diamino benzidine- a substrate chromogen) was added onto the sections and incubated for 15 minutes. Slides were then washed in three changes of PBS for 10 minutes each and then rinsed in distilled water and counterstained with Harris' hematoxylin. The tissue sections were washed with ascending series of isopropanol (50%, 100%) and xylene and mounted with DPX (di-n-butyl phthalate in xylene) for microscopic examination.

The prostate cancer specimens were used as positive control for the study. Negative controls were used by incubating the sections without a primary antibody prior to the addition of appropriate secondary antibodies was also used. All of the slides were observed under the microscope at magnifications of 10 X and 40 X.

#### Evaluation

The slides were observed by two independent examiners. The staining on the epithelium was evaluated based on the intensity of staining, scored as negative (-), mildly positive (+), moderately positive (++), or highly positive (+++), respectively.

Positively stained cells in the connective tissue were evaluated by counting the number of cells that were stained. The percentage of positive cells was the ratio of the number of cells in the connective tissue that showed intense staining divided by the total number of cells counted. A total of 1000 cells were counted in each

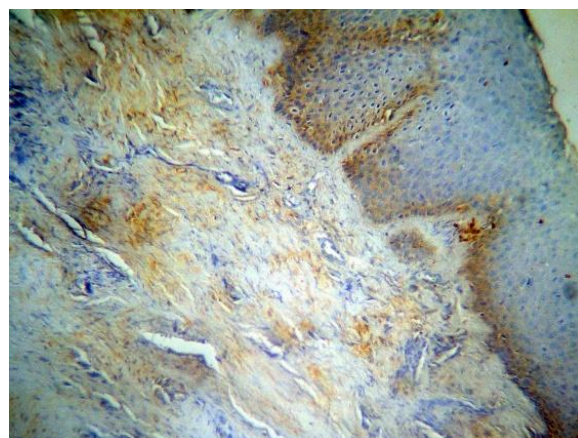
slide. Thus, labeling index (LI)= (number of positive cells/1, 000) X 100.

#### Statistical Analysis

Data entry and descriptive analysis was performed using a statistical software program (SPSS version 10.0.5). Independent t test, was used to compare the groups (healthy and periodontitis) with regard to the B7-H3 expression in the connective tissue. The intensity of staining was determined by two examiners and the inter-examiner variation was determined by kappa analysis.

#### Results

A good inter-examiner agreement was observed between the two examiners (health-0.718; disease - 0.797). Table 1 summarizes the results of the present study. In the periodontal health group (group A) the gingival epithelium demonstrated intense staining in 5 specimens, moderate staining in 7 specimens and pale staining in 3 specimens. The mean LI in the connective tissue was  $50.28 \pm 26.09$ . (Figure 1)



**Figure 1:** Immunohistochemistry of membranous staining B7-H3 in gingival epithelia and connective tissue of healthy (Group A) samples (original magnification 10X) with high intensity staining.

In the periodontitis group (group B), the gingival epithelium demonstrated intense staining in 4 specimens, moderate staining in 8 specimens and pale staining in 1 specimen. The mean LI in the connective was  $41.37 \pm 25.29$ . Two specimens did not demonstrate any staining. The difference in intensity of epithelial staining between the groups was statistically insignificant ( $p > 0.713$ ) while in the connective tissue, the mean LI demonstrated a statistically insignificant decrease in chronic periodontitis group (group B) group ( $41.37 \pm 25.29$ ) when compared to healthy (group A) group ( $50.28 \pm 26.09$ ) with  $p$  value = 0.415 as described in Table 2.

**Table 1:** Tabulation of intensity and labeling index in gingival samples

S.NO.	AGE/SEX	SITE	PPD	CAL	Procedure	Intensity 1	Intensity 2	LI	SLIDE NO.
1.	21/F	13-P*	2 2 2	-	CL*	++	++	20	4555
2.	49/F	36-B*	3 3 3	-	CL	++	+	75.3	4521
3.	20/F	17-B*	2 3 3	-	CL	+++	+++	-	4519
4.	44/M	36-L*	3 3 3	-	CL	++	+	22.2	4509
5.	32/F	21-P	2 3 3	-	CL	+++	+++	73.5	4627
6.	24/M	16- B	2 1 2	-	CL	++	++	75.3	4342
7.	24/F	37-L	2 3 3	-	CL	+++	+++	69.3	4464
8.	22/M	46-L	3 2 3	-	CL	++	++	-	4437
9.	39/M	27-B	2 2 2	-	CL	+++	+++	71.9	4585
10.	25/F	25-P	2 2 2	-	CL	+	+	13.2	4694
11.	21/F	46-B	3 2 3	-	CL	+++	+++	18.4	4239
12.	26/M	25-B	3 3 3	-	CL	+	+	-	4333
13.	25/F	25-B	3 2 3	-	CL	++	++	-	4592
14.	24/F	36-L	3 3 3	-	CL	++	++	56.1	4234
15.	22/F	13-P	2 2 2	-	CL	+	+	57.9	4345
16.	43/M	27-B	8 6 8	9 8 9	MWF*	++	+	92.6	4674
17.	60/F	11-P	6 6 6	7 7 7	MWF	+++	+++	-	4359
18.	38/F	45-L	6 5 6	7 7 7	MWF	+	+	53.3	4612
19.	48/M	47-B	10 8 8	10 9 9	MWF	++	++	44.7	4488
20.	39/M	46- B	10 6 8	12 7 8	MWF	++	++	26.1	4327
21.	28/F	36-B	4 2 10	6 4 11	MWF	+++	+++	29.8	4683
22.	45/M	25-B	5 7 7	7 8 8	MWF	+++	+++	18.9	4720
23.	55/M	23-B	6 8 8	7 10 9	MWF	++	++	14.3	4719
24.	36/F	17-P	7 6 8	8 7 9	MWF	++	++	49.4	4443
25.	40/F	46-L	8 6 8	9 8 9	MWF	++	++	31.4	4554
26.	58/M	16 -B	7 10 8	9 10 9	MWF	-	-	-ve*	4711
27.	37/F	46-L	6 4 6	7 5 7	MWF	-	+	-ve	4344
28.	37/F	16- B	8 8 8	10 9 9	MWF	+++	+++	26.3	4247
29.	43/M	16- P	9 9 7	10 11 8	MWF	++	++	85.7	4499
30.	48/F	34-B	9 7 9	10 9 10	MWF	++	++	24.0	4540

\*B- Buccal, L- Lingual, P- Palatal, CL- Crown Lengthening, MWF- modified Widman flap, -ve- Negative

**Table 2:** Comparison of Intensity Scoring and Mean Labeling Index between Health and Disease

	Group A (health)	Group B (periodontal disease)	p value
Epithelium (intensity)	Intense-5 Moderate-7 Mild-3	Intense- 4 Moderate-8 Mild-1 Negative-2	-
Connective tissue (mean LI± SD)	50.28±26.09	41.37±25.29	0.415

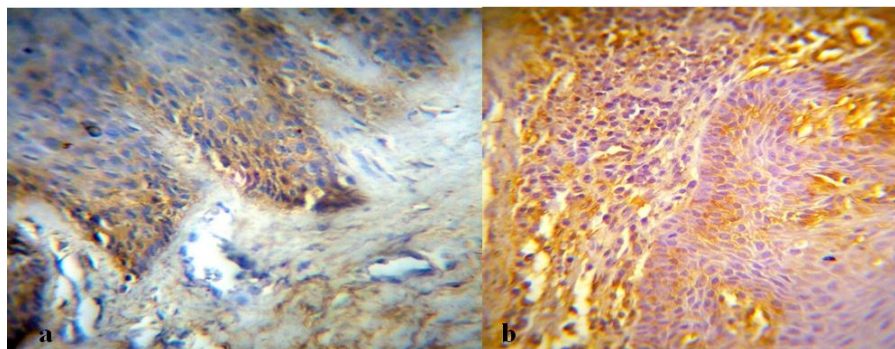
(p value <0.001-statistically significant; p value >0.001- statistically insignificant)

**Discussion**

The progression of periodontal disease is characterized by short bursts of disease activity and long periods of quiescence. [19] Though the factors that have been proposed to play a role are not yet well defined, it has been postulated to be related to a change in quantity or quality of periodontopathogenic bacteria and/or host response. [19-20]

This study sought to identify B7-H3 in the gingival tissues as it may play a role in regulating T cell responses by either co-stimulation/ co-inhibition. T cell activation may in turn regulate the host response thereby significantly affecting disease progression. [2] The role of the newer B7 family members in periodontal disease is not yet fully understood. To the best of our knowledge, the present study is the first to identify the presence of B7-H3 in gingival tissues.

In the healthy samples, B7-H3 was present predominantly in the basal layer of gingival epithelium and in the connective tissue just beneath the basal lamina. The role of the gingival epithelium in providing innate immune functions is well documented. In addition to functioning as a mechanical barrier, immune cells such as dendritic cells and neutrophils help in antigen presentation and clearance. [21] The results of our study provides evidence that the epithelium may, in addition to influencing innate immune mechanisms, activate or infl-



**Figure 2a:** Immunohistochemistry of membranous staining B7-H3 in gingival epithelia and connective tissue of healthy (group A) samples (original magnification 40X) with high intensity staining. **b:** Immunohistochemistry of membranous staining B7-H3 in gingival epithelia and connective tissue of periodontitis (group B) samples (original magnification 40X) with high intensity staining

uence T cell behavior through expression of costimulatory molecules. Our results suggest that B7-H3 was expressed constitutively in the epithelium most likely as a result of exposure to commensal bacteria present in the oral cavity.

In the connective tissue, B7-H3 was present just beneath the basal lamina and was not detected in the deeper layers of the connective tissue. (Figure 2a, 2b) Although, it is difficult to assign a role or suggest a function for these molecules based on this study, we speculate that connective tissue infiltration is part of the basal inflammatory tone that is crucial to mounting an effective defense against the periodontopathogens. [22-23]

In the present study, periodontally diseased samples demonstrated a statistically insignificant decrease in the expression of B7-H3 when compared to healthy samples. It is beyond the scope of this study to accurately identify the role of B7-H3 in T cell activation. The exact mechanism of B7-H3 mediated T cell activation has not yet been elucidated at its receptor, and downstream signaling remains as yet unknown.

Investigators have examined the role of B7-H3 in inflammatory bone disorders and chronically inflamed tissues. B7-H3 has been identified in fibroblast-like synovocytes obtained from patients with rheumatoid arthritis, and air way epithelium. [10-11] Their role in the development of inflammation in these systems by regulating T-helper cell function has been proposed. Luo et al. concluded from their study that B7-H3 differentially regulates T-helper subsets. [24] It has been found to play a costimulatory role on Th-1 and Th-17 subsets and a co-inhibitory role on Th-2 subsets. It is proposed to be the reason for the differential expression pattern of B7-H3 in chronic inflammatory diseases.

Since this study clearly proves the presence of B7-H3 in gingival tissues, future studies are needed to clearly outline the role of B7-H3 in the pathogenesis of periodontal disease.

The limitations of this study include the small sample size and the lack of staging of periodontal disease at time of biopsy. The diseased specimens were obtained during periodontal surgery after phase I therapy was completed. Hence, it is possible that this may not truly represent the picture during active periodontal disease. Other costimulatory signal molecules such PD-1 has been demonstrated in periodontal tissues previously in a similar manner. [9] Finally, since polyclonal B7H3 antibodies were used this could have further affected the results.

### Conclusion

In conclusion, in the light of the present study it may be hypothesized that the costimulatory molecules play a more complex role than originally believed in the progression of periodontal disease. Targeted therapeutic strategies aimed at controlling periodontal disease and periodontal regeneration must take this into account before being put to clinical practice.

### Acknowledgements

Authors are especially grateful to Dr. T.S.S. Kumar (Professor, Department of Periodontics) and to the staff of the Department of Oral and Maxillofacial Pathology for their guidance and assistance in carrying out this project.

### Conflict of Interest

None to declare.

**References**

- [1] Gaffen SL, Hajishengallis G. A new inflammatory cytokine on the block: re-thinking periodontal disease and the Th1/Th2 paradigm in the context of Th17 cells and IL-17. *J Dent Res.* 2008; 87: 817-828.
- [2] Gemmell E, Yamazaki K, Seymour GJ. The role of T cells in periodontal disease: homeostasis and autoimmunity. *Periodontol* 2000. 2007; 43: 14-40.
- [3] Teng YT, Nguyen H, Gao X, Kong YY, Gorczynski RM, Singh B, et al. Functional human T-cell immunity and osteoprotegerin ligand control alveolar bone destruction in periodontal infection. *J Clin Invest.* 2000; 106: R59-R67.
- [4] Lane P. Regulation of T and B cell responses by modulating interactions between CD28/CTLA4 and their ligands, CD80 and CD86. *Ann N Y Acad Sci.* 1997; 815: 392-400.
- [5] Collins M, Ling V, Carreno BM. The B7 family of immune-regulatory ligands. *Genome Biol.* 2005; 6: 223.
- [6] Orima K, Yamazaki K, Aoyagi T, Hara K. Differential expression of costimulatory molecules in chronic inflammatory periodontal disease tissue. *Clin Exp Immunol.* 1999; 115: 153-160.
- [7] Gemmell E, McHugh GB, Grieco DA, Seymour GJ. Costimulatory molecules in human periodontal disease tissues. *J Periodontal Res.* 2001; 36: 92-100.
- [8] Han DC, Huang GT, Lin LM, Warner NA, Gim JS, Jewett A. Expression of MHC Class II, CD70, CD80, CD86 and pro-inflammatory cytokines is differentially regulated in oral epithelial cells following bacterial challenge. *Oral Microbiol Immunol.* 2003; 18: 350-358.
- [9] Figueira EA, de Rezende ML, Torres SA, Garlet GP, Lara VS, Santos CF, et al. Inhibitory signals mediated by programmed death-1 are involved with T-cell function in chronic periodontitis. *J Periodontol.* 2009; 80: 1833-1844.
- [10] Tran CN, Thacker SG, Louie DM, Oliver J, White PT, Endres JL, et al. Interactions of T cells with fibroblast-like synoviocytes: role of the B7 family costimulatory ligand B7-H3. *J Immunol.* 2008; 180: 2989-2998.
- [11] Nagashima O, Harada N, Usui Y, Yamazaki T, Yagita H, Okumura K, et al. B7-H3 contributes to the development of pathogenic Th2 cells in a murine model of asthma. *J Immunol.* 2008; 181: 4062-4071.
- [12] Chapoval AI, Ni J, Lau JS, Wilcox RA, Flies DB, Liu D, et al. B7-H3: a costimulatory molecule for T cell activation and IFN-gamma production. *Nat Immunol.* 2001; 2: 269-274.
- [13] Prasad DV, Nguyen T, Li Z, Yang Y, Duong J, Wang Y, et al. Murine B7-H3 is a negative regulator of T cells. *J Immunol.* 2004; 173: 2500-2506.
- [14] Suh WK, Gajewska BU, Okada H, Gronski MA, Bertram EM, Dawicki W, et al. The B7 family member B7-H3 preferentially down-regulates T helper type 1-mediated immune responses. *Nat Immunol.* 2003; 4: 899-906.
- [15] Luo L, Chapoval AI, Flies DB, Zhu G, Hirano F, Wang S, et al. B7-H3 enhances tumor immunity in vivo by costimulating rapid clonal expansion of antigen-specific CD8+ cytolytic T cells. *J Immunol.* 2004; 173: 5445-5450.
- [16] Savage A, Eaton KA, Moles DR, Needleman I. A systematic review of definitions of periodontitis and methods that have been used to identify this disease. *J Clin Periodontol.* 2009; 36: 458-467.
- [17] Matsuyama T, Kawai T, Izumi Y, Taubman MA. Expression of major histocompatibility complex class II and CD80 by gingival epithelial cells induces activation of CD4+ T cells in response to bacterial challenge. *Infect Immun.* 2005; 73: 1044-1051.
- [18] Tinti F, Soory M. Mechanisms for redox actions of nicotine and glutathione in cell culture, relevant to periodontitis. *Sci Rep.* 2012; 2: 566.
- [19] Goodson JM, Tanner AC, Haffajee AD, Sornberger GC, Socransky SS. Patterns of progression and regression of advanced destructive periodontal disease. *J Clin Periodontol.* 1982; 9: 472-481.
- [20] Graves DT, Fine D, Teng YT, Van Dyke TE, Hajishengallis G. The use of rodent models to investigate host-bacteria interactions related to periodontal diseases. *J Clin Periodontol.* 2008; 35: 89-105.
- [21] Dale BA. Periodontal epithelium: a newly recognized role in health and disease. *Periodontol* 2000. 2002; 30: 70-78.
- [22] Vankeerberghen A, Nuytten H, Dierickx K, Quirynen M, Cassiman JJ, Cuppens H. Differential induction of human beta-defensin expression by periodontal commensals and pathogens in periodontal pocket epithelial cells. *J Periodontol.* 2005; 76: 1293-1303.
- [23] Feng Z, Weinberg A. Role of bacteria in health and disease of periodontal tissues. *Periodontol* 2000. 2006; 40: 50-76.
- [24] Luo L, Zhu G, Xu H, Yao S, Zhou G, Zhu Y, et al. B7-H3 Promotes Pathogenesis of Autoimmune Disease and Inflammation by Regulating the Activity of Different T Cell Subsets. *PLoS One.* 2015; 10: e0130126.