

Prolonged Atrio-Ventricular Block Following Scorpion Bite: A Case Report

M. B. Sharifkazemi, G.R. Rezaian,
M. Zamirian, S.A.R. Hashemi

Abstract

This report describes a 55-year-old woman in whom yellow scorpion sting resulted in the development of Mobitz type 1 and transient complete heart blocks unresponsive to atropine administration. It might be concluded that although autonomic involvement including parasympathetic overactivity is present in such cases, other factors such as toxic damage to the cardiac conduction system may play a role in the development of some of the cardiovascular manifestations of scorpion toxin.

Iran J Med Sci 2003; 28(2):

Keywords • Heart block • Scorpion venoms

Introduction

The venom of scorpion can produce a series of cardiovascular effects including short-lived bradyarrhythmias and varying degrees of atrioventricular block.^{1,2} Herein we report a case of scorpion bite with prolonged asymptomatic Mobitz type I and transient complete heart block.

Case History

A 55-year-old housewife referred to our university hospital emergency room a few hours after being stung on the second toe of her left foot by a yellow scorpion (*Buthus quinquestratus*). She complained of local pain and swelling at the site of bite but had no sweating, weakness, dizziness or respiratory difficulty.

On examination, she appeared to be fully conscious, oriented and not in respiratory distress. Her blood pressure was 140/80 mmHg, respiratory rate 12/min and her pulse rate was around 48/min. Except for mild swelling, redness and tenderness at the site of scorpion sting, other parts of the physical examination were unremarkable.

Paraclinical investigations including complete blood count (CBC), blood urea nitrogen, serum electrolytes, urinalysis and chest X-ray were all within normal limits. A standard 12-lead electrocardiogram showed narrow QRS complexes at a rate of about 48/min and 2:1 atrio-ventricular block which temporarily changed to 3:2 Mobitz type I block following injection of a total dose of 1.5 mg of atropine. She also had ST-T changes and T-wave inversion in the precordial leads. Antivenom was simultaneously given and she was admitted to the Coronary Care Unit for cardiac monitoring. During the next 2-3 days, she developed new ST segment and T wave changes in the inferior leads, mimicking non-Q-wave myocardial infarction (Fig1).

Department of Medicine (Cardiology),
Shiraz University of Medical Sciences,
Shiraz, Iran.

Correspondence: MB Sharifkazemi
MD. Nemazee Hospital P.O.Box
71935-1334, Shiraz-Iran.
Fax: +98-711-6279733
E-mail: sharifkm@sums.ac.ir

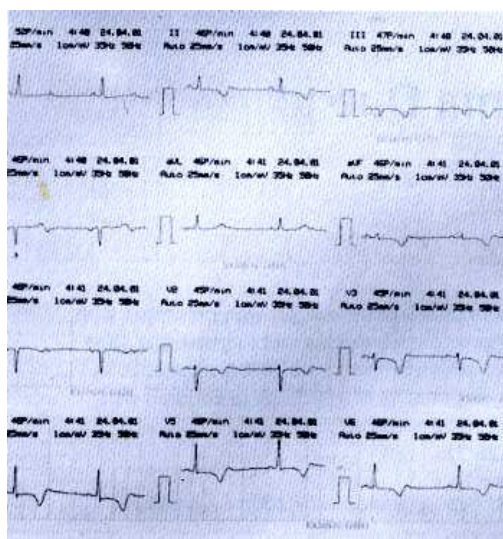


Figure 1: Initial electrocardiogram showing 2:1 AV block and diffuse ST-segment and T-wave inversion.

Serial serum creatine phosphokinase measurements, however, did not show any rise and her subsequent echocardiogram revealed no left ventricular wall motion abnormality either. She remained well and asymptomatic over the next 13 days of her CCU admission, during which her cardiac rhythm showed 2:1 AV- block with intermittent 3:2 Wenckebach periodicity and also a few episodes of transient complete heart block with ventricular escape rhythm. On the 14th hospitalization day, her cardiac rhythm finally reverted to normal sinus rhythm and ST-T changes improved, which remained so until her discharge from the hospital a few days later.

Discussion

Scorpion venom is a very potent cardiotoxic agent and cardiac involvement is usually the cause of death of the victims, especially in children.³ Elevated levels of circulating catecholamines are thought to be the underlying cause for most of these cardiovascular effects.⁴

Sympathetic overactivity, pulmonary edema, tachycardia and death are mainly seen with red scorpion sting⁵, while bradyarrhythmias are usually associated with black⁵ and yellow² scorpion bites. The latter two apparently carry a more benign clinical presentation.

A variety of electrocardiographic changes have been described in association with scorpion sting.^{6,7} Our patient presented with asymptomatic bradycardia associated with 2:1 A-V block and intermittent 3:2 Wenckebach periodicity. Although such

rhythm was reported to be responsive to atropine and lasting for only a few hours², this, however, was not seen in our patient in whom the rhythm persisted for about two weeks and was associated with short runs of transient complete A-V block with ventricular escape rhythm. Toxic damage to the cardiac conduction system, rather than parasympathetic overactivity, may therefore play a role in the development of A-V blocks in these patients. Additionally, our patient developed ST-segment and T-wave changes in the inferior leads suggestive of a non-Q-wave myocardial infarction. These changes have invariably been attributed to toxic myocarditis induced by the toxin,^{6,8} however no CPK elevation or ventricular arrhythmias were detected. Left ventricular wall motion abnormalities or valvular leaks were not detected by 2-D and color-Doppler echocardiographic studies either. Post-mortem studies in fatal cases, could of course elucidate some of these unresolved issues.

References

- 1 Shapira MY, Haviv YS, Sviri S: Second degree atrio-ventricular block and cardiotoxicity secondary to envenomation by scorpion *Leiurus quinquestriatus* ("yellow scorpion")- an indication for serotherapy?. *Hum Exp Toxicol* 1998; **17(10)**:541-3.
- 2 Cantor A, Wanderman KL, Ovsyshcher I, Gueron M: Parasympathomimetic action of scorpion venom on the cardiovascular system. *Isr J Med Sci* 1997;**13(9)**:908-11.
- 3 Santhanakrishnan BR, Ranganathan G, Ananthasubramaniam P, et al: Cardiovascular manifestations of scorpion sting in children. *Indian Pediatr* 1997;**14(5)**:353-6.
- 4 Freire-Maia L, Pinto GI, Franco I: Mechanism of the cardiovascular effects produced by purified scorpion toxin in rat. *J Pharmacol Exp Ther* 1974;**188(1)**:207-13.
- 5 Bawaskar HS: Diagnostic cardiac premonitory signs and symptoms of red scorpion sting. *Lancet* 1982;**1(8271)**:552-4.
- 6 Sinha AK: Cardiovascular manifestations of scorpion sting in a case of congenital complete atrioventricular block. *J Indian Med Assoc* 1989;**87(10)**:237-8.
- 7 Kari RK, Yeolekar ME: Electrocardiographic changes in experimental myocarditis induced by scorpion (*Buthus tamulus*) venom. *Indian Heart J* 1986;**38(3)**:206-11.
- 8 Alagesan R, Srinivasaraghavan J, Balambal R, et al: Transient complete right bundle branch block following scorpion sting. *J Indian Med Assoc* 1977;**69(5)**:113-14.