

Case Report

Endodontic Management of a Mandibular Second Premolar with Unusual Four-canal Anatomy and Coronal Perforation: A Case Report

Fahime Alimardani ¹; Yasamin Ghahramani ²; Ali Rezaei Nejad ¹;

¹ Postgraduate Student, Dept. of Endodontics, School of Dentistry, Shiraz University of Medical Sciences, Shiraz, Iran.

² Dept. of Endodontics, School of Dentistry, Shiraz University of Medical Sciences, Shiraz, Iran.

KEY WORDS

Mandibular second premolar;
Root Canal Therapy;
Complex Anatomy;
Root Canal Morphology;

Received:
Revised:
Accepted:

ABSTRACT

Mandibular second premolars pose a considerable challenge in endodontic therapy due to the complex and highly variable nature of their root canal morphology. Failure to recognize atypical anatomical configurations can result in untreated canals and subsequent treatment failure. This case report describes a rare instance of a mandibular second premolar exhibiting two separate roots and four distinct root canals. Additionally, an iatrogenic perforation on the distal crown surface occurred during access cavity preparation. The tooth anomaly was accurately diagnosed and successfully managed using cone-beam computed tomography (CBCT), which facilitated precise identification of canal anatomy and guided appropriate endodontic and perforation repair procedures.

Corresponding Author: Rezaei Nejad A. Ghasrodasht St., Dental School, Shiraz, Iran.
Postal Address: 7195615878 Tel: +98-9137075400 Email: alirezaeinejad5400@gmail.com

Cite this article as:

Introduction

The success of nonsurgical endodontic therapy depends on identifying all root canals, thorough mechanical and chemical cleaning, and proper obturation with suitable materials [1]. Clinicians must understand root canal morphology, which varies significantly across ethnicities and even individuals of the same ethnicity [2]. Mandibular second premolars are most commonly found to possess a single root canal, with this configuration occurring in 98.8% of cases [3]. However, it is also observed that these teeth can exhibit variations in the number of canals. The occurrence of two canals has been reported to range from 1.2% to 29%, depending on the population studied [3]. The presence of three canals is notably rare, with a prevalence of 0.4% to 0.5%. Additionally, reports of four or five canals are exceedingly scarce and typically found only in isolated case reports [3]. Hasheminia *et al.* [4] conducted a cone-beam computed tomography (CBCT) study to investigate the root and canal morphology of mandibular second premolars in an Iranian population. Out of 384 evaluated teeth, 88.8% exhibited a single root, 9.11% had two roots, and 2.09% presented with three roots. Regarding canal anat-

omy, 83.6% of the teeth demonstrated a single root canal, whereas 16.4% exhibited multiple canals. Given the high prevalence of anatomical variations in these teeth, incorporating supplementary diagnostic methods- such as dental loupes, headlamps, surgical operating microscopes (SOMs), ultrasonic devices, and CBCT- is strongly advised to improve the identification of additional canals during clinical procedures [3].

In addition to anatomical complexities, iatrogenic perforation represents one of the most significant procedural complications in endodontics. Perforations may arise during access cavity preparation or canal instrumentation due to insufficient knowledge of the tooth's internal anatomy or inadequate visualization. Such defects create a direct pathway between the root canal system and the periodontal tissues, which can lead to persistent infection, inflammation, and ultimately, treatment failure if not promptly diagnosed and properly managed. Therefore, recognizing predisposing factors and applying advanced imaging techniques is critical to preventing and addressing these complications [5].

This report presents a rare case of a mandibular second premolar exhibiting two separate roots and four

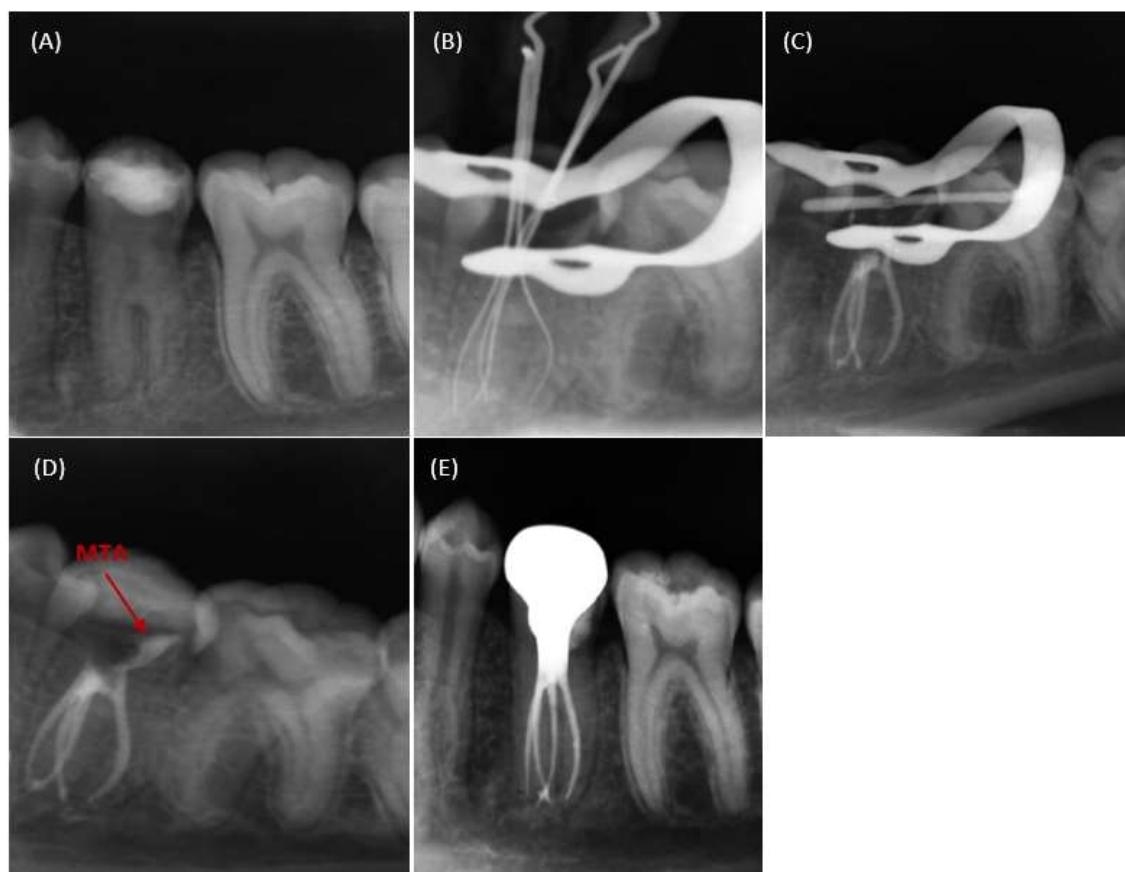


Figure 1: **a:** Preoperative periapical radiograph, **b:** Working length determination, **c:** Postoperative radiograph immediately after obturation, **d:** Postoperative radiograph after temporary filling placement, **e:** Six-month follow-up

distinct root canals, complicated further by an iatrogenic perforation on the distal crown surface. This highlights the critical importance of comprehensive radiographic assessment, including CBCT, and meticulous treatment planning to effectively manage such complex anatomical and clinical challenges.

Case Presentation

A 16-year-old Iranian female with no significant medical history was referred to the Endodontic Department of Shiraz Dental School for treatment of the mandibular left second premolar (#20) due to a perforation during access cavity preparation and the complex anatomy of the root canal system. The patient reported spontaneous pain and discomfort during chewing. Clinical examination revealed good oral hygiene and partially completed endodontic therapy on tooth #20, with no visible swelling or sinus tracts. Radiographic evaluation demonstrated atypical root anatomy (at least two roots with multiple canals), a normal periodontal ligament and a perforation on the distal aspect of the crown (Figure 1a).

To accurately determine the precise location and ex-

tent of the perforation and to comprehensively evaluate the morphology, number of roots, and canal configuration of the tooth, CBCT was performed, revealing two roots—one mesial and one distal—with two canals in each root, resulting in a total of four canals. The point of division of the roots was located in about 12 mm apical to buccal aspect (Figure 2). Local anesthesia was administered using 1.8 mL of 2% lidocaine with epinephrine 1:100,000 (Darupakhsh, Tehran, Iran). The tooth was isolated with a rubber dam and disinfected with 0.2% chlorhexidine (Najo, Tehran, Iran). Temporary restoration and carious tissue were removed, and the access cavity was adjusted. Perforation defect was cleaned and prepared with ultrasonic instruments. Calcium hydroxide (Ultradent, South Jordan, Utah, USA) was passively syringed into defect to control bleeding and allowed to remain in the perforation defect for five minutes. Then it was flushed from the field using sodium hypochlorite. Repeated placement and removal of calcium hydroxide for three times effectively controlled the bleeding [6].

The four canals were located at the same level (Figure 3), and patency was achieved using #10 K-files

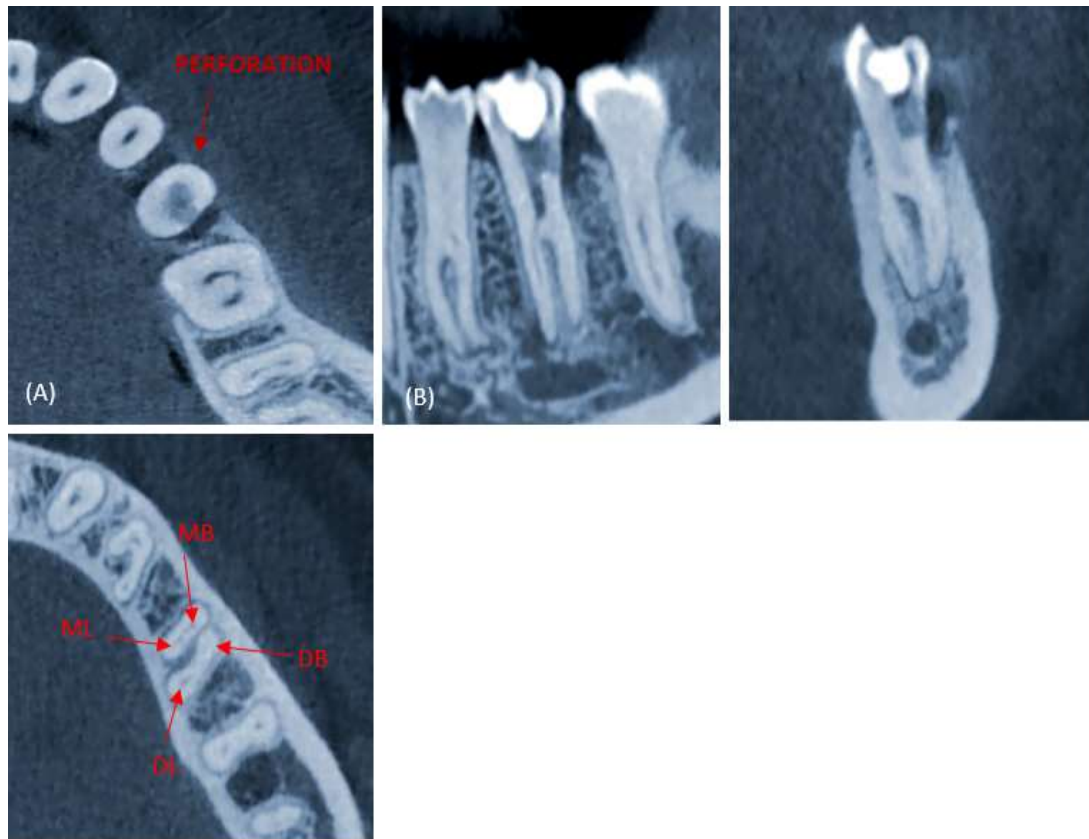


Figure 2: **a:** Axial view of Cone beam computed tomography (CBCT) (perforation site), **b:** Sagittal plane, **c:** Coronal plane, **d:** Axial plane (MB: Mesiobuccal Canal, ML: Mesiolingual Canal, DB: Distobuccal Canal, DL: Distolingual Canal)

(Mani, Tochigi, Japan). The initial working length of the root canal was determined by diagnostic X-ray and an apex locator (Root ZX; Morita, Tokyo, Japan) and was measured as mesiobuccal (20.5mm), distobuccal (21mm), distolingual (21mm), and mesiolingual (20 mm) (Figure 1b). The rotary nickel-titanium instruments (ProTaper Universal; Dentsply, Maillefer, Ballaigues, Switzerland) were employed to shape the canals up to size F2, with 2.5% sodium hypochlorite (Nikdarman, Tehran, Iran) used as an irrigant between each step. Ultrasonic activation of sodium hypochlorite by ultrasonic handpiece Ultra X (Eighteenth, Changzhou Sifary Medical Technology Co., Ltd, Changzhou City, China) was performed followed by final irrigation with 17% EDTA (Nikdarman, Tehran, Iran) for one minute to remove the smear layers. After drying the canals, obturation was completed using gutta-percha cones and Endoseal mineral trioxide aggregate (MTA) sealer (Maruchi, Wonju, South Korea) employing the single-cone technique. The perforation site was sealed with MTA material (Morvabon, Tehran, Iran).

A periapical radiograph confirmed successful obturation (Figure 1c). The tooth was temporarily restored

with a wet cotton pellet over the MTA and sealed with Cavison material (Golchai, Tehran, Iran) (Figure 1d). At a six-month follow-up, no symptoms or clinical issues were observed in tooth #20 (Figure 1e).

Discussion

The success of root canal treatment is fundamentally dependent on the thorough eradication of microorganisms from the entire root canal system and the prevention of their recolonization. Given the complex and variable anatomy of root canals, incomplete debridement or failure to locate all canals can result in persistent bacterial infection, ultimately leading to treatment failure [7]. Missed canals represent a primary etiological factor in the development of apical periodontitis, with studies indicating their presence in up to 98% of such cases. Moreover, evidence from CBCT investigations demonstrates that teeth with untreated canals exhibit a more than fourfold increased risk of periapical pathology [8]. Among all teeth, premolars are particularly susceptible to the issue of missed canals. These teeth are predominantly single-rooted, with a common Type I canal configuration [8]. However, anatomical variations, includi-

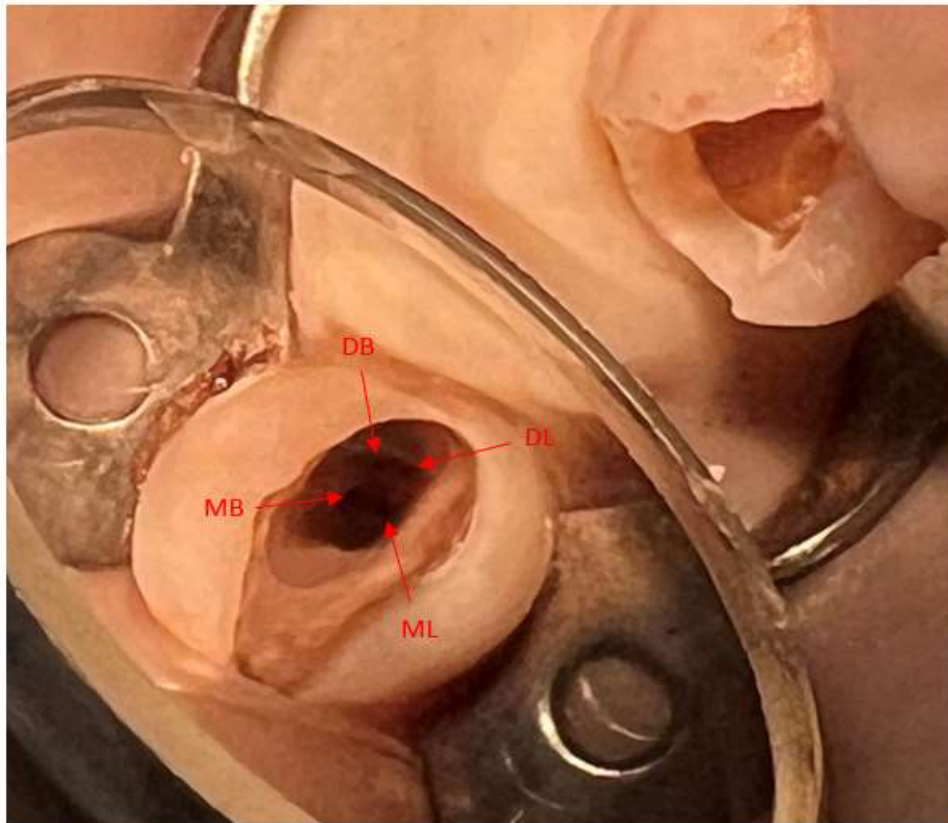


Figure 3: The four canal orifices were exposed. MB: Mesiobuccal canal, ML: Mesiolingual canal, DB: Distobuccal canal, DL: Distolingual canal

ing the presence of multiple canals, can complicate treatment and increase the risk of missed canals, which account for 42% of retreatment cases [9].

The complexity of root canal morphology in mandibular premolars is influenced by factors such as ethnicity and individual anatomical variations. For example, in the Iranian population, clinicians may encounter a higher likelihood of multiple canals, leading to potential misdiagnosis and treatment failure if these variations are not identified.

Obtaining radiographic images from multiple angulations is essential for a comprehensive assessment of root canal anatomy and the detection of additional canals that may not be apparent on conventional periapical views. Careful evaluation of the periodontal ligament outline can provide important diagnostic indicators; for instance, in mandibular premolars, the abrupt narrowing or disappearance of the primary canal space in the middle third of the root is frequently suggestive of apical bifurcation or accessory roots [10]. In addition to traditional radiographs, CBCT offers highly valuable three-dimensional information that facilitates accurate visualization of complex internal anatomy, including the num-

ber, configuration, and curvature of canals. Furthermore, the combined use of high-resolution magnification via a dental operating microscope and the precise refinement of the access cavity with ultrasonic instruments were critical in this case. The enhanced visualization afforded by magnification, together with the diagnostic power of CBCT imaging, significantly improves the clinician's ability to differentiate subtle anatomical landmarks and variations in dentin coloration between the chamber floor and walls, thereby supporting precise identification and negotiation of complex canal configurations [3].

It is also important to highlight that, in the present case; a contemporary obturation strategy was adopted, utilizing a single-cone technique in conjunction with a bioceramic sealer. This approach may facilitate treatment procedures in cases with complex root canal anatomy. In contrast, Niavarzi *et al.* [3] and Morreira *et al.* [10] reported using resin-based sealers for obturation in their respective case reports. However, it is worth noting that a recent systematic review and meta-analysis by Zamparini *et al.* [11] demonstrated no significant differences between bioceramic and resin-based sealers in

terms of tooth survival, overall treatment outcomes, postoperative pain, or periapical extrusion. Therefore, according to the authors' conclusion, the choice of sealer should primarily be based on clinician preference and specific clinical considerations, as the current evidence does not support the clear superiority of one material over the other [11].

In the present case, the occurrence of an iatrogenic perforation during access cavity preparation added a considerable level of complexity. The perforation likely resulted from the operator's attempt to locate all canals in a tooth with highly atypical internal anatomy, combined with the divergence of the roots at an unusual apical level. One of the immediate challenges was achieving adequate control of hemorrhage from the perforation site to allow further canal disinfection and obturation. This was accomplished through repeated application of calcium hydroxide and copious irrigation with sodium hypochlorite, followed by careful drying of the defect.

MTA was selected as the sealing material for the perforation due to its proven biocompatibility, excellent sealing ability, and capacity to promote periradicular healing [12]. The choice of MTA aligns with current recommendations favoring bioceramic materials over conventional alternatives for perforation repair [13].

Radiographic imaging, particularly preoperative periapical radiographs, played a pivotal role in identifying the perforation and gaining a precise understanding of the tooth's complex anatomy, which was essential for planning an appropriate treatment strategy without further compromising the tooth or adjacent structures [12]. In addition to conventional radiography, adjunctive methods such as CBCT, electronic apex locators, and the use of high-resolution magnification with a dental operating microscope can significantly enhance the clinician's ability to detect and accurately localize perforations, especially in teeth presenting with atypical root canal configurations. The integration of these diagnostic modalities with a detailed anatomical assessment enables precise sealing and repair of the defect, thereby reducing the risk of microbial contamination, postoperative complications, and ultimately improving the prognosis of endodontic treatment [14].

Despite the additional complexity posed by the perforation, the treatment was successfully completed, as

demonstrated by the absence of symptoms and radiographic evidence of healing at the six-month follow-up. This case highlights the importance of early identification, immediate management, and careful material selection in treating perforations associated with complex root canal anatomy. Overall, the successful resolution of this challenging scenario underscores the critical role of advanced imaging modalities and meticulous clinical technique in modern endodontic therapy.

Ethical Consideration

Prior to data collection, informed consent was obtained from the patient for the use of their medical information in this study. All data were handled confidentially and in accordance with ethical principles.

Conclusion

The case report contributes to enhanced comprehension of the variations in the root canal anatomy of mandibular second premolars. Comprehensive knowledge of root canal morphology and the use of advanced diagnostic techniques along with thorough preoperative planning lead to improved treatment outcomes. Knowledge of these variations not only reduces the risk of missed canals but also enhances long-term success rates in endodontic therapy.

Acknowledgment

The authors would like to thank Oral and Dental Disease Research Center of Shiraz University of Medical Sciences for its support during the study.

Funding Support

No funding was received for this study

Conflict of Interest

None

References

- [1] Hamed A, Jafarzadeh H, Navabi S. Endodontic Management of a Maxillary Premolar with a Rare Configuration (Three Buccolingually Positioned Canals in a Single Root) as Confirmed by Cone Beam Computed Tomography: a Case Report. *J Dent.* 2022; 23: 506-510.
- [2] Ahmed HA, Abu-Bakr N, Yahia N, Ibrahim Y. Root and canal morphology of permanent mandibular molars in a Sudanese population. *Int Endo J.* 2007; 40: 766-771.
- [3] Niavarzi S, Ghabraei S, Malekpour F. Mandibular second

- premolar with four canals: a case report. *Iranian Endo J.* 2022; 17: 209.
- [4] Hasheminia SM, Mehdizadeh M, Bagherieh S. Anatomy assessment of permanent mandibular premolar teeth in a selected Iranian population using cone-beam computed tomography. *Dent Res J.* 2021; 18: 40.
- [5] Clauder T. Present status and future directions—Managing perforations. *Iranian Endo J.* 2022; 55: 872-891.
- [6] Ingle JJ, Bakland LK, Baumgartner JC, Hargreaves KM, editors. *Ingle's Endodontics*. 7th ed. Hamilton: BC Decker; 2019. p.785.
- [7] Nikhil V, Jha P, Mishra P, Sahu S, Bhargava A. Two palatal roots in maxillary first molar, a rare entity: report of two cases. *J Dent.* 2024; 25: 178.
- [8] Ghabraei S, MahjourianQomi R, Bagheri P. Endodontic management of a four-canal mandibular second premolar; using an operative microscope: A case report. *Clin Case Reports.* 2024; 12: e8821.
- [9] Glassman GD. Flare-up with associated paresthesia of a mandibular second premolar with three root canals. *Oral Surg Oral Med Oral Pathol.* 1987; 64: 110-113.
- [10] Moreira-Pinto L, Peixoto-de-Araújo L, Pinto-Carpena L, de-Souza-Ferreira N, Rolim-de-Sousa EL. Endodontic re-intervention of a mandibular second premolar with four root canals: a case report. *CES Odontología.* 2022; 35: 47-59.
- [11] Zamparini F, Lenzi J, Duncan HF, Spinelli A, Gandolfi MG, Prati C. The efficacy of premixed bioceramic sealers versus standard sealers on root canal treatment outcome, extrusion rate and post-obturation pain: A systematic review and meta-analysis. *Int Endo J.* 2024; 57: 1021-1042.
- [12] Haghgoo R, Niyakan M, Moghaddam KN, Asgary S, Mostafaloo N. An in vitro comparison of furcal perforation repaired with pro-root MTA and new endodontic cement in primary molar teeth-a microleakage study. *J Dent.* 2014; 15: 28.
- [13] Roberts HW, Toth JM, Berzins DW, Charlton DG. Mineral trioxide aggregate material use in endodontic treatment: a review of the literature. *Dent Mater.* 2008; 24: 149-164.
- [14] Shemesh H, Cristescu RC, Wesselink PR, Wu MK. The use of cone-beam computed tomography and digital periapical radiographs to diagnose root perforations. *J Endo.* 2011; 37: 513-516.