



Short and Mid-term Outcomes of Percutaneous Perimembranous Ventricular Septal Defect Closure Using Amplatzer Duct Occluders Type II in Children and Adolescents

Hamid Amoozgar¹, MD;  Hamid Arabi¹, MD; Mohammadreza Edraki¹, MD;  Amir Naghshzan¹, MD; Nima Mehdizadegan¹, MD; Hamid Mohammadi¹, MD; Mohammadjavad Nobakhti², MD; Kambiz Keshavarz³, MD

¹Department of Pediatrics, School of Medicine, Shiraz University of Medical Sciences, Shiraz, Iran;

²Department of Cardiology, School of Medicine, Shiraz University of Medical Sciences, Shiraz, Iran;

³Department of Pediatrics, School of Medicine, Yasuj University of Medical Sciences, Yasuj, Iran

Correspondence:

Mohammadreza Edraki, MD;
Pediatric Ward, Namazi Hospital, Namazi Sq., Zand Blvd., Postal code: 71936-13311, Shiraz, Iran

Tel: +98 71 36474332

Email: edrakidr@yahoo.com

Received: 01 June 2024

Revised: 26 August 2024

Accepted: 22 September 2024

What's Known

- Percutaneous closure of perimembranous ventricular septal defects using Amplatzer devices is a safe and effective treatment option for pediatric and adolescent patients.

What's New

- The Amplatzer Duct Occluder Type II, a newer generation device, appears to be a safe and effective transcatheter occlusion device for patients with perimembranous ventricular septal defects (pmVSD). It demonstrates the potential to reduce the severity of valve regurgitation while maintaining a low risk of conductive disturbances.

Abstract

Background: Percutaneous closure of perimembranous ventricular septal defects (pmVSD) with Amplatzer duct occluder type II (ADO II) is a novel method. The present study aimed to evaluate the short and mid-term outcomes of this method in children and adolescents.

Methods: This retrospective study was conducted at Shiraz University of Medical Sciences from July 2019 to September 2023. It evaluated the outcomes of pmVSD closure using the ADO II. The effects on tricuspid regurgitation (TR), mitral regurgitation (MR), and aortic regurgitation (AR) were assessed, along with the presence of residual shunts and conduction disturbances. Data were analyzed using SPSS software (version 24.0). Fisher's exact test and the Chi square test were employed for statistical analysis. $P < 0.05$ was considered statistically significant.

Results: This study included 102 patients. 31 patients had a short-term follow-up with a median of 79 (71.02, 97.01) days, and 71 patients had a mid-term follow-up with a median of 900 (384.25, 1044.75) days. The severity of TR, MR, and AR dropped to lower levels in most patients during follow-ups ($P = 0.003$, $P = 0.030$, and $P = 0.033$, respectively). There was no significant difference in the valvar regurgitation changes between patients weighing more or less than 10 Kg or between those with short and mid-term follow-ups ($P > 0.05$). There were no hemolysis, clot, embolization, death, or third-degree atrioventricular blocks. However, 2 (2%) patients developed a small residual shunt.

Conclusion: Overall, ADO II appeared to be a safe transcatheter occlusion device for patients with pmVSD, and this method could reduce the severity of TR, MR, and AR with few complications.

Please cite this article as: Amoozgar H, Arabi H, Edraki MR, Naghshzan A, Mehdizadegan N, Mohammadi H, Nobakhti MJ, Keshavarz K. Short and Mid-term Outcomes of Percutaneous Perimembranous Ventricular Septal Defect Closure Using Amplatzer Duct Occluders Type II in Children and Adolescents. Iran J Med Sci. 2025;50(6):393-403. doi: 10.30476/ijms.2024.102819.3595.

Keywords • Heart septal defects • Septal occluder device • Cardiac catheterization

Introduction

Perimembranous ventricular septal defects (pmVSD) are the most prevalent congenital cardiac condition, and several therapeutic options have been proposed. One of them is the transcatheter approach. Although it seems safe, it is not free from complications,

such as tricuspid valve regurgitation (TR), mitral valve regurgitation (MR), aortic valve regurgitation (AR), and atrioventricular blocks, necessitating meticulous short-term and mid-term monitoring.¹

High-velocity flow through pmVSD can affect the tricuspid, mitral, and tricuspid valves, leading to regurgitation. Consequently, closing a pmVSD might reduce the severity of regurgitation.^{2, 3}

The area surrounding a pmVSD is anatomically complicated, including fibrous tissues, leaflets, and chordae tendineae. These fibrous tissues, which are frequently adhered to the chordae tendineae and form a lamellar structure, are vulnerable to fracture or damage during pmVSD closure procedures, potentially causing TR or MR.^{4, 5}

AR, while rare, remains a serious complication following the transcatheter closure of pmVSD, often caused by either accidental pinching of the aortic leaflets by the VSD occluder devices or tearing of the aortic leaflets by the catheter.⁶

The Amplatzer duct occluder type two (ADO II) was primarily designed to close patent ductus arteriosus, with a fine and flexible texture without using fabric materials, and required a low profile small 4F or 5F catheter system. The soft texture of the device is intended to lower the risk of full atrioventricular block and may preclude the onset of TR, MR, and AR. The device has been used off-label to close pmVSDs since 2011, delivering a performance comparable to other off-label devices for heart disease.⁷⁻⁹

The present study aimed to investigate the short and mid-term outcomes of pmVSD closure using the ADO II device in children and adolescents with TR, MR, AR, residual shunt, and arrhythmias.

Patients and Methods

Patients and Follow-ups

This retrospective study evaluated consecutive patients under 18 years of age from two teaching hospitals affiliated with Shiraz University of Medical Sciences (Shiraz, Iran) from July 2019 to September 2023.

The research was conducted in accordance with the Helsinki Declaration. Besides, it was approved by the Ethics Committee of Shiraz University of Medical Sciences (code: IR.SUMS.MED.REC.1401.580). Before proceeding with the procedures, written informed consent was obtained from the guardians of all participants.

VSD closure criteria included left to right shunt through the pmVSDs, accompanied by at least one of the following: cardiomegaly, a QP/QS ratio ≥ 1.5 , left ventricular dilatation with an

end-diastolic volume ≥ 2 z-score, a left atrium-to-aortic diameter ratio ≥ 1.5 , pulmonary artery hypertension, worsening of TR, MR, or AR, or failure to thrive.

In patients with pulmonary artery hypertension, VSD closure was performed only if the pulmonary vascular resistance was less than 6 Wood Units M^2 .

The exclusion criteria were tricuspid, mitral, and aortic valve impairments that were not associated with VSDs, and conduction abnormalities.

Transthoracic echocardiography and electrocardiograms were used to monitor the patient before, during, and after the procedures. Follow-ups were conducted either annually or every 6 months.

Patients' data from 1 to 30 days after the procedures were deemed early follow-up, from 30 days to 2 years as a short-time follow-up, and after that as a mid-term follow-up.

The patients were categorized into two groups based on their follow-up period: ≤ 2 years (short-term) and > 2 years (mid-term).

One of the aims of the present study was to compare TR, MR, and AR in short-term follow-up with mid-term follow-up. For this purpose, patients from the mid-term group were selected. The echocardiography findings of patients aged 1-12 months following the procedure were regarded as the short-term follow-up, and the echocardiography findings of the same patients at the last follow-up were recorded as the mid-term observations. Finally, the echocardiography findings of the same patients were compared between the two periods.

Some specialists recommend that percutaneous pmVSD closure should be performed on patients weighing more than 8-10 Kg.^{10, 11} Therefore, the patients were also classified into two groups based on their weights (≤ 10 Kg and > 10 Kg), and the outcomes were compared between these two groups.

VSD Closure Protocol

The pmVSDs were small to medium size, and the retrograde percutaneous method was performed from femoral arteries. Some patients had no TR, MR, or AR, while others had only moderate TR, MR, or mild to moderate AR. The patients had no aortic cusp prolapse or less than moderate prolapse. The aortic rim of the VSDs was greater than 2 mm, and the occluders were of the ADO II type (Abbott Medical, MN, USA).

Catheterization Procedure

All patients underwent cardiac catheterization under conscious anesthesia. Occluders were

typically selected to be 1-2 mm larger than the maximal diameter of the defects during diastole, as determined by angiography. After accessing the femoral arteries, intravenous heparin (100 U/Kg) was administered. Left ventriculography was performed in a long axial oblique position (60° left anterior oblique/20° cranial). To navigate via the left ventricle and the femoral artery defect, a 5 Fr partly cut-pigtail catheter was utilized. We passed a 0.035-inch hydrophilic guidewire through the defect and into the right ventricle, preferably via the superior vena cava or pulmonary artery. Subsequently, a long delivery sheath was guided over the guidewire into the right ventricle. An occluder was then advanced through the delivery sheath and positioned at the defect site, ensuring the occluder's waist was aligned with the aneurysmal/defect pouch right ventricular outlet orifice. The left disc of the occluder was shifted closer to the ventricular septum.

Prior to the occluder deployment, left ventricular angiography was performed using a contrast agent through the cut pigtail or the delivery sheath to confirm the appropriate placement of the device and complete occlusion (figure 1). Subsequently, transthoracic or transesophageal echocardiography was performed to exclude any residual shunt and confirm normal function of the tricuspid, mitral, and aortic valves.

All patients underwent clinical evaluations, electrocardiographic monitoring, and chest X-rays following the treatment before being discharged. They were also prescribed 6 months of antiplatelet medication with aspirin at a dosage of 3–5 mg/Kg/day orally.

Echocardiography

Transthoracic echocardiography was performed following standard guidelines.¹² Measurements from two-dimensional, M-mode, and color Doppler techniques were acquired using a Samsung HS70 echo system (Samsung Medison Co., Korea) and recorded in the database system of our institution.

TR, MR, and AR had five grade categories: no-trivial, mild, mild to moderate, moderate, and severe. TR and MR were graded using a semi-quantitative evaluation method from the four-chamber view based on the volume of color Doppler blood jet as follows: no-trivial (no flow to less than one-third of the atrium); mild (one-third of the atrium); mild to moderate (from one to two-thirds of the atrium), moderate (two-thirds of the atrium), and severe (more than two-thirds of the atrium).¹³

The dimensions of the aortic valve annulus and vena contracta dimensions were obtained in the long-axis view to evaluate AR. Then, the vena contracta/aortic annulus ratio was calculated, with ratios of <5%, 5-10%, 10-20%, 20-50%, and >50%, indicating no-trivial, mild, mild to moderate, moderate, and severe AR, respectively.¹⁴

Statistical Analysis

Data were analyzed using SPSS software (version 24.0, SPSS, Chicago, USA) and presented as mean±SD, median and interquartile range (Q1, Q3), and percentage. The Friedman test was used to analyze how each variable changed over time. Statistical comparisons were conducted using Fisher's exact test and the Chi square test, $P \leq 0.05$ was considered statistically significant.

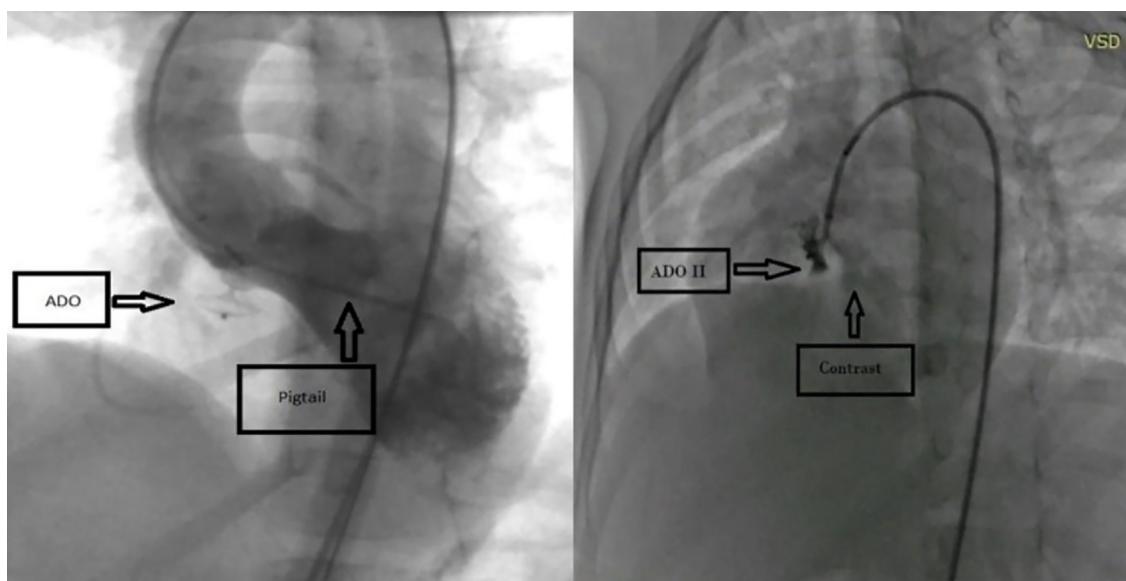


Figure 1: According to the contrast injection procedure, one or two femoral artery accesses could be used to determine the appropriate position of the device. The left image shows the injection site from a cut pigtail, which requires access from two femoral arteries. The right image shows an injection from the delivery sheath, which requires access to only one femoral artery.

Results

Data from 102 out of 103 patients were ultimately analyzed, comprising 46 females (45.1%) and 56 males (54.9%). One patient was excluded due to the lack of acceptable data.

The median and (Q1, Q3) of the age was 57.50 (30.75, 100.50) months, the median and (Q1, Q3) of the weight was 17.0 (12.07, 28.01) Kg, and the mean \pm SD of the VSDs size was 3.43 \pm 0.68 mm.

Thirty-one patients had short-term follow-ups of 79 (71.02, 97.01) days, and 71 patients had mid-term follow-ups with a median of 900 (384.25, 1044.75) days.

Figure 2 shows the changes in the severity of TR, MR, and AR before and after the procedure in all patients during follow-up. There was a decrease in the severity of TR ($P=0.001$) and MR ($P=0.627$), along with a slight worsening of AR ($P=0.092$).

Table 1 displays the severity of TR, MR, and AR before and immediately after the procedure in all cases. According to Fisher's exact test results, the changes in TR ($P=0.401$) and AR ($P=0.170$) before and immediately after the procedures were not statistically significant. However, the changes in MR severity were significant ($P=0.022$), indicating a reduction in the severity of MR.

The changes in TR, MR, and AR among patients in the mid-term group were investigated to determine changes at short- and mid-term follow-up. Using Fisher's exact test, the echocardiographic data of the same patients were compared between the 1-12 months follow-up and follow-up more than two years (table 2). Significant changes were observed at both short- and mid-term follow-ups, as indicated by the P values for TR ($P=0.003$), MR ($P=0.030$),

and AR ($P=0.033$). In a few patients, the severity of TR, MR, and AR increased from no-trivial to mild. However, the severity of other valve categories decreased to less severe degrees.

The percentages of TR changes among patients with short- and mid-term follow-ups were compared using the Chi square test (figure 3).

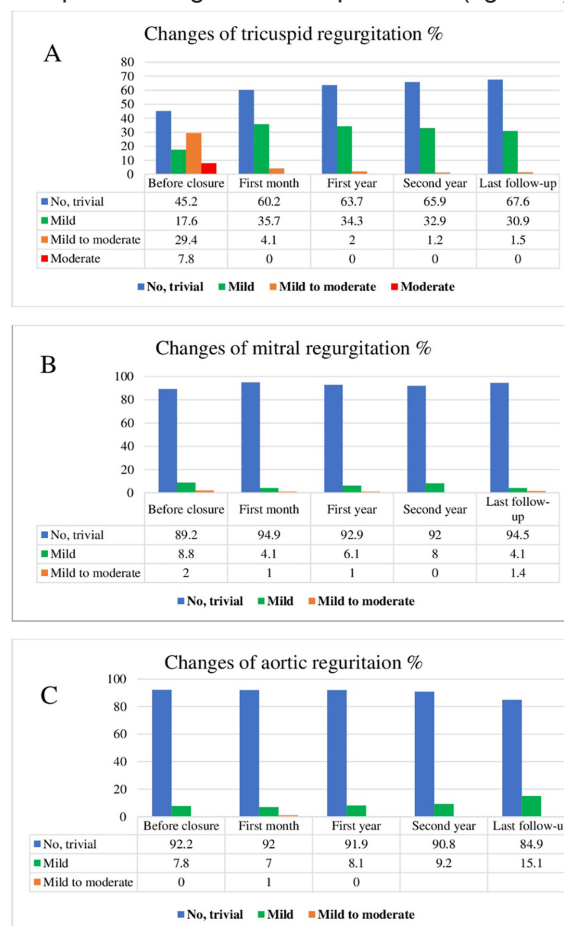

Figure 2: The distribution of different degrees of tricuspid regurgitation, mitral regurgitation, and aortic regurgitation is shown in all patients over the follow-up of the study.

Table 1: Valves regurgitation severity before and early after the procedure among all patients who underwent echocardiography

Regurgitation before procedures		Total	Regurgitation early after procedures				P value of all regurgitation classifications
			No-trivial n (%)	Mild n (%)	Mild to moderate n (%)	Moderate n (%)	
TR	No-trivial	45	32 (71.1)	11 (24.4)	2 (4.5)	0	0.401*
	Mild	17	8 (47.1)	8 (47.1)	1 (5.8)	0	
	Mild to moderate	29	15 (51.7)	13 (44.8)	1 (3.5)	0	
	Moderate	7	4 (57.1)	3 (42.9)	0	0	
MR	No-trivial	88	85 (96.6)	3 (3.4)	0	0	0.022*
	Mild	9	8 (88.9)	1 (11.1)	0	0	
	Mild to moderate	2	1 (50)	0	1 (50)	0	
	Moderate	0	0	0	0	0	
AR	No-trivial	92	86 (93.5)	5 (5.4)	1 (1.1)	0	0.170*
	Mild	8	6 (75)	2 (25)	0	0	
	Mild to moderate	0	0	0	0	0	
	Moderate	0	0	0	0	0	

*Fisher exact test; AR: Aortic regurgitation; MR: Mitral regurgitation; TR: Tricuspid regurgitation; $P<0.05$ was considered significant.

Table 2: Valvular regurgitation at 1-12 months and more than 2 years after procedures among patients who underwent echocardiography with mid-term follow-up

Regurgitation 1-12 months after procedures		Total	Regurgitation at least 2 years after procedures				P value of all regurgitation classifications
			No-trivial n (%)	Mild n (%)	Mild to moderate n (%)	Moderate n (%)	
TR	No-trivial	37	31 (83.8)	5 (13.5)	1 (2.7)	0	0.003*
	Mild	27	13 (48.1)	14 (51.9)	0	0	
	Mild to moderate	2	1 (50)	1 (50)	0	0	
	Moderate	0	0	0	0	0	
MR	No-trivial	68	65 (95.6)	3 (4.4)	0	0	0.030*
	Mild	1	1 (100)	0	0	0	
	Mild to moderate	1	0	0	1 (100)	0	
	Moderate	0	0	0	0	0	
AR	No-trivial	65	58 (95.1)	7 (4.9)	0	0	0.033*
	Mild	5	3 (60)	2 (40)	0	0	
	Mild to moderate	1	0	1 (100)	0	0	
	Moderate	0	0	0	0	0	

*Fisher Exact Test; AR: Aortic regurgitation; MR: Mitral regurgitation; TR: Tricuspid regurgitation; P<0.05 was considered significant.

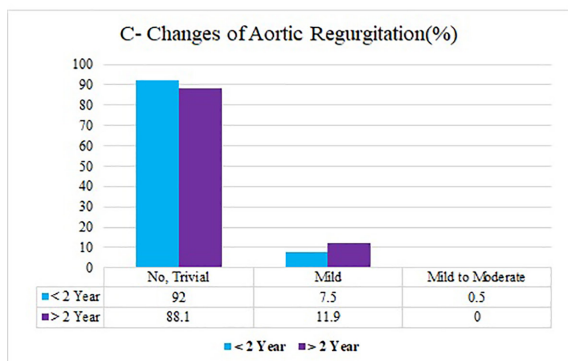
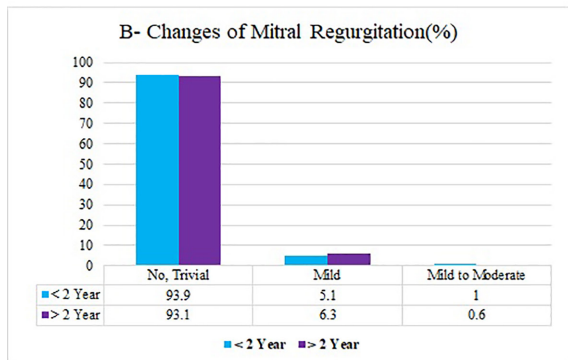
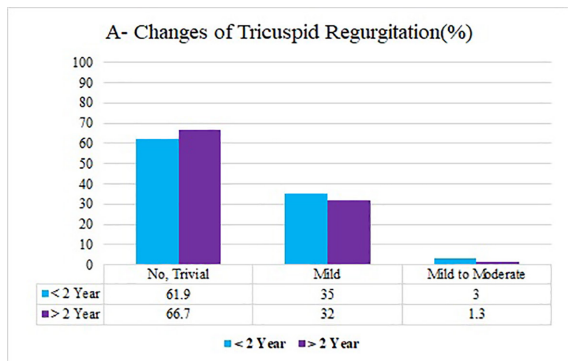


Figure 3: Changes in the severity of tricuspid, mitral, and aortic regurgitation are shown among patients who had short-term (less than 2 years) and mid-term (more than 2 years) follow-up.

There were no significant differences between any of the percentages; no trivial: (61.9%, 66.7%, $P=0.364$), mild: (35.1%, 32%, $P=0.562$), and mild to moderate: (3%, 1.3%, $P=0.290$).

Moreover, the distribution of MR changes among patients with short- and mid-term follow-ups was analyzed using the Chi square test (figure 3). No significant difference in the percentages was observed: no trivial: (93.9%, 93.1%, $P=0.769$), mild: (5.1%, 6.3%, $P=0.621$), and mild to moderate: (1%, 0.6%, $P=0.683$).

Additionally, the distribution of AR changes among the mentioned patients was examined using the Chi square test. There were no significant differences in the percentages: no trivial: (92.0%, 88.1%, $P=0.225$), mild: (7.5%, 11.9%, $P=0.161$), and mild to moderate: (0.5%, 0.0%, $P=0.370$).

To determine the association between regurgitation and weight, the changes in the degree of TR (table 3), MR (table 4), and AR (table 5) were compared between all patients weighing less than and more than 10 Kg, which showed no significant differences.

According to the data presented in table 3, there was no significant association between TR and weight before the procedures ($P=0.961$), early after that ($P=0.423$), or at the final follow-up ($P>0.991$).

The results for MR before closure ($P>0.992$), early after that ($P=0.074$), and at the final follow-up ($P>0.993$) indicated that there was no significant association between MR and weight (table 4).

In table 5, the findings indicated that the differences in AR before the procedures ($P=0.138$), immediately after ($P>0.994$), and at the final follow-up ($P=0.242$) were not statistically significant ($P>0.05$). Therefore, no significant correlation was observed between AR and weight.

Table 3: Changes in the degree of tricuspid regurgitation in patients weighing less or more than 10 Kg

Characteristics		Weight≤10 n=10 n (%)	Weight>10 n=92 n (%)	P value of all regurgitation classifications
TR before Closure	No-trivial	4 (40)	42 (45.7)	0.961**
	Mild	2 (20)	16 (17.4)	
	Mild to moderate	3 (30)	27 (29.3)	
	Moderate	1 (10)	7 (7.6)	
TR early after closure	Notrivial	5 (50)	54 (60.6)	0.423**
	Mild	4 (40)	33 (36)	
	Mild to moderate	1 (10)	3 (3.4)	
TR at the last follow-up	No-trivial	5 (71.4)	41 (67.2)	>0.991**
	Mild	2 (28.6)	19 (31.2)	
	Mild to moderate	0	1 (1.6)	

**Fisher exact test; TR: Tricuspid regurgitation; P<0.05 was considered significant.

Table 4: Changes in the degree of mitral regurgitation in patients weighing less or more than 10 Kg

Characteristics		Weight≤10 n=10 n (%)	Weight>10 n=92 n (%)	P value of all regurgitation classifications
MR before Closure	No-trivial	9 (90)	82 (89.1)	>0.992**
	Mild	1 (10)	8 (8.7)	
	Mild to moderate	0	2 (2.2)	
MR early after closure	No-trivial	8 (80)	86 (96.6)	0.074**
	Mild	2 (20)	2 (2.3)	
	Mild to moderate	0	1 (1.1)	
MR at the last follow-up	No-trivial	7 (100)	62 (93.9)	>0.993**
	Mild	0	3 (4.6)	
	Mild to moderate	0	1 (1.5)	

**Fisher exact test; MR: Mitral regurgitation; P<0.05 was considered significant.

Table 5: Changes in the degree of aortic regurgitation in patients weighing less or more than 10 Kg

Characteristics		Weight≤10 n=10 n (%)	Weight >10 n=92 n (%)	P value of all regurgitation classifications
AR before Closure	No-trivial	8 (80)	86 (93.5)	0.138*
	Mild	2 (20)	6 (6.5)	
AR early after closure	No-trivial	10 (100)	82 (91.1)	>0.994**
	Mild	0	7 (7.8)	
	Mild to moderate	0	1 (1.1)	
AR at the last follow-up	No-trivial	7 (100)	55 (83.3)	0.242*
	Mild	0	11 (16.7)	

*Chi square test; **Fisher exact test, AR: Aortic regurgitation; P<0.05 was considered significant.

One objective of this study was to compare changes in TR, MR, and AR severity between short- and mid-term follow-ups, stratified by patient weight (≤10 Kg and >10 Kg). As shown in table 6, the analysis included 71 patients from the mid-term group. The Chi square test revealed no statistically significant differences in regurgitation changes between the weight groups. However, a decline in the severity of regurgitation was observed across all three valves during the mid-term follow-up.

Complications and Permanent Conduction Disturbance

No serious complications, such as remarkable

hemolysis,¹⁵ clot formation, embolization, or death were observed in our patients. Only one case of device embolization into the pulmonary artery occurred due to the underestimation of the VSD size. However, the device was successfully snared and replaced with a larger one.

Regarding conduction disturbance, only one patient, a 3.5-year-old, 14-Kg female, in the mid-term follow-up group experienced first-degree atrioventricular block 6 months after the procedure. Normal conduction was restored in subsequent follow-ups.

Residual Shunt

This shunt was observed in 8 (7.8%) of

Table 6: The changes of TR, MR, and AR in short- and mid-term follow-ups among patients in the mid-term group with weights less than or equal to 10 Kg and more than 10 Kg

Characteristics		Regurgitation	Follow-up time		P value of each regurgitation classification	P value of all regurgitation classifications
			Short-term follow-up (%)	Mid-term follow-up (%)		
TR	≤10 Kg	No-trivial	57.9	68.7	0.513	0.880
		Mild	31.6	25	0.675	
		Mild to moderate	10.5	6.3	0.660	
	>10 Kg	No-trivial	62.4	66.4	0.461	0.528
		Mild	35.4	32.8	0.639	
		Mild to moderate	2.2	0.8	0.291	
MR	≤10 Kg	No-trivial	85	100	0.114	0.238
		Mild	15	0	0.116	
		Mild to moderate	-	-	-	
	>10 Kg	No-trivial	94.9	92.4	0.353	0.491
		Mild	3.9	6.9	0.239	
		Mild to moderate	1.1	0.7	0.711	
AR	≤10 Kg	No-trivial	95	100	0.374	0.99
		Mild	5	0	0.370	
		Mild to moderate	-	-	-	
	>10 Kg	No-trivial	91.2	86.8	0.165	0.139
		Mild	7.8	13.2	0.112	
		Mild to moderate	1.0	0	0.357	

AR: Aortic regurgitation; MR: Mitral regurgitation; TR: Tricuspid regurgitation; P<0.05 was considered significant.

the patients during 1 month of follow-up, of which six shunts were smaller than 2 mm and were resolved within 6 months of follow-up. The remaining 2 (2%) patients in the mid-term follow-up group were 2 and 6 years old, with weights of 12 and 23 Kg, respectively. These two patients had a shunt larger than 2 mm, which was not removed during the follow-up.

Discussion

The outcomes of transcatheter pmVSD closure using the ADO II device were promising, with minimal rates of morbidity and mortality. Nonetheless, this procedure is not without risks.⁸ This study investigated the emergence or alterations in TR, MR, and AR, as well as conduction disturbances, in adolescents and children following transcatheter pmVSD closure using ADO II. According to the findings of this study, ADO II seemed to be a safe device for pmVSD closure, and the use of this device could reduce the severity of TR, MR, and AR, and had few complications.

This device, which is an evolution of the ADO I, was initially designed for the closure of small to medium-sized patent ductus arteriosus. Its application has expanded to include off-label VSD closure. The ADO II is designed

with a finer, more flexible mesh, allowing it to be deployed using a smaller 5F or 4F catheter system.¹⁶ This softer design aimed to minimize the risk of serious complications such as total atrioventricular block.^{17, 18}

Its waist is more pliable and less rigid than the ADO I; thus, reducing the pressure exerted on adjacent structures. This modification decreased the risk of chronic injury to surrounding tissues, such as the chordae tendineae.¹⁰

This device is soft and low-profile, enabling easier manipulation and better adaptation to the shape of VSDs, particularly as it does not interfere with the aortic valve leaflets. The retrograde method for pmVSD closure was developed alongside the antegrade method. The retrograde technique decreased the risk of tricuspid and aortic valve injuries during the arteriovenous track establishment caused by the catheter and guidewire.^{19, 20}

Anterograde occlusion entails establishing an arteriovenous track, which can be complex and problematic. Issues such as the guide wire navigating through the tricuspid valve's chordae tendineae or the aortic valve can elevate the associated risks.¹⁰

The effects of pmVSD on adjacent tissues, particularly the tricuspid valve, are remarkable. The tissues around the pmVSDs are complex.

This area is close to where the chordae tendineae of the tricuspid valve attaches. The force of the blood flow at the attachment zone can pull on the valve, and the direction of high-speed blood flow, as well as the formation of a tricuspid septal leaflet aneurysm, can deform the chordae tendineae close to the ventricular septum, all contribute to the mechanism of TR.⁵

Theoretically, functional TR and MR should resolve when the VSD closes.⁵

In the 6-month follow-up after VSD closure, both TR and MR were significantly reduced in this research, suggesting that this decrease could be attributed to reduced ventricular volumes. In older patients, as the ventricles and the tricuspid and mitral annuli continue to grow, TR and MR might increase with time and potentially persist after percutaneous closure. The improvement in TR and MR was less pronounced in older patients with an enlarged right ventricle.²¹

Significant TR observed thus far could be attributed to the occluder's entanglement with the chordae tendineae, which became apparent immediately post-procedure. To prevent TR and MR, it is critical to detect any entanglement during the procedure, which can be facilitated by intraprocedural echocardiography.²²

In contrast, some patients might not exhibit immediate post-procedural TR and MR but rather show a gradual increase over 3 to 12 months, which highlighted a subacute to chronic progression.²³

This suggested that tricuspid and mitral valve damage could be gradual and progressive, with a tear developing in the absence of obvious chordae or papillary muscle injury.

The most likely cause of such a rupture is trauma inflicted by the stiff structure of the devices on the valve leaflets, or injury to the leaflets and apparatus due to pulling the device from the aorta or the base of the left ventricle towards the VSD.²³ The main mechanism by which MR increases following transcatheter closure might involve the Amplatzer disk interfering with the chordae tendineae.⁴

A previous study examined the follow-up and clinical data of 102 pediatrics who underwent pmVSD retrograde closure via the femoral artery using the ADO II device. At the final follow-up (6-92 months/ median: 36 months), the complete closure rate was 98%. Nine of these patients had new TR, which resolved in five and reduced in four patients.¹⁰

Furthermore, another study reported that the incidence of TR following pmVSD occlusion varied between 5.4% to 40%.²⁴

Various studies were conducted to determine the effect of pmVSD closure on the MR degree.

The findings highlighted the efficacy of VSD closure in reducing MR severity, remarking that mitral valve repair is unnecessary at the time of VSD closure if MR is caused by dilation of the mitral valve annulus, and in another study, MR severity in children was found to be reduced following pmVSD closure using the transcatheter approach.^{25, 26}

In another study, the MR degree in infants with pmVSD was investigated. The findings indicated that MR often improved following surgical closure with no need for mitral valve replacement, and recommended mitral valve surgery only in cases exhibiting more than moderate MR.²⁷

In the present study, while TR severity showed no significant changes in the short-term, MR degree decreased in short-term follow-up. Additionally, both TR and MR were relieved during mid-term follow-up.

Regarding AR, more than mild aortic leaflet prolapse complicates transcatheter repair. The mechanism behind AR post-perfect closure of pmVSD is attributed to anatomical abnormalities, such as lack of muscular support beneath the aortic valve, which might cause leaflet herniation. Furthermore, the "venturi effect" during systole might pull the cusps to the defect. AR after transcatheter closure might result from the device impinging on the aortic cusps or the left ventricular disk of occluders interfering with the valve leaflets.¹⁰ The incidence of AR following pmVSD occlusion ranged between 3.3% and 11.0%.²⁴

In an investigation, the incidence of AR post-procedure was found to be 1%, with all cases being mild and resolving or disappearing during mid-term follow-up. A meta-analysis was conducted to comprehensively evaluate the ADO II effectiveness and safety for pmVSD closure. The study included patients aged from 0.5 to 55.7 years and found that post-procedure AR, while significant, had a pooled rate of 0% with a 95% confidence interval ranging from 0% to 1%.⁸

Another study among 49 pediatric patients found that 20.0% of their patients experienced the exacerbation of AR. However, AR decreased in severity or even disappeared in 24.4% of other cases.²⁸

In this research, AR indicated no significant changes in short-term follow-up. However, it alleviated in mid-term follow-up.

Based on previous research and findings from this study, the improvement of AR post-procedure differed. Nevertheless, it appeared that AR generally stabilized or diminished in most patients, implying that the transcatheter

approach using ADO II might be appropriate if AR severity and prolapse were mild to moderate.²⁸

Regarding conductive disturbances, it is challenging to determine the exact causes of heart block following pmVSD closure. The most likely risk factors include device oversizing, low body weight, young age, the presence of a ventricular septal aneurysm, and direct compression trauma caused by the device.²⁹ The ADO II is considered safe for pmVSD closure, with a low risk of post-procedure arrhythmias, especially complete atrioventricular block, and left bundle-branch block. The occluder's flexible joints and the absence of internal patches enable it to conform to the patient's anatomy rather than forcing it to adapt to its structure.²⁹

Some specialists claimed that due to the lowest interference of the discs with the AV node, minimal dysfunction would be expected.¹⁰

No heart block occurred during the follow-up analysis of 49 pediatric cases.²⁸

In a previous study, 21 children underwent percutaneous pmVSD closure using an ADO II device and had a median follow-up period of 12 months. During this time, no cases of atrioventricular block were observed.¹⁶ However, another recent study reported two cases of complete atrioventricular block after pmVSD closure with ADO II, both of which were resolved through early surgical removal of the devices.³⁰

Another study found no cases of complete atrioventricular block. However, there was a 1% incidence of intermittent complete left bundle branch block 4 days after the procedure, which resolved to normal sinus rhythm within 2 days.¹⁰

Additional research involved 244 children who underwent effective pmVSD transcatheter closure by ADO-II over a period of 1-48 months. The findings revealed that 35.66% experienced various types of arrhythmias. These included 3.28% with complete left bundle-branch block, 11.07% with incomplete right bundle-branch block, 2.05% with left anterior hemiblock, 0.82% with both incomplete right bundle-branch block and left anterior hemiblock, 5.74% with junctional escape rhythm, and 0.41% with incomplete right bundle-branch block, 0.40% with junctional escape rhythm and left anterior hemiblock, and 0.40% with junctional escape rhythm and ventricular premature beats. Additionally, 0.82% had first-degree atrioventricular block, 0.41% had second-degree atrioventricular block, and other conduction disorders occurred in 5.74% of cases. Although most arrhythmias were transient, arrhythmias persisted in 15 cases (6.15%). There were no reports of complete or high-degree atrioventricular block.³⁰

In the present investigation, only one patient in the mid-term follow-up group developed first-degree atrioventricular block 6 months after the procedure, which subsequently resolved.

In a study evaluating children post-pmVSD closure using the ADO II, a complete closure rate of 98% was noted, with a median follow-up period of 36 months.¹⁰

Moreover, in the present study, only 2 (2%) patients had residual shunt in mid-term follow-ups, which was comparable to previous reports.

This study was conducted at a single center and was not randomized, necessitating a longer follow-up period to fully determine the ADO II's safety and effectiveness in comparison to traditional occluders. Future research should involve larger-scale, multicenter prospective studies to confirm these findings.

Conclusion

The ADO II is emerging as a more effective and safer option for transcatheter closure of pmVSD, with particular effectiveness and decreased rates of complications when employed via the femoral artery for a retrograde approach. Despite these advantages, this device is still deemed "off-label" and has yet to be validated by studies with larger populations and longer follow-up periods. Further research is required to substantiate its benefits in minimizing TR, MR, and AR over longer durations and in larger patient populations.

Acknowledgment

The authors would like to thank Shiraz University of Medical Sciences (Shiraz, Iran) for non-financial support.

Authors' Contribution

H.Am: Study design, data analysis, and drafting; H.A: Data collection, interpretation of data, and reviewing the manuscript; M.E: Data interpretation, drafting, and reviewing the manuscript; A.N: Study design and drafting, N.M: Echocardiography, data analysis, and reviewing the manuscript; H.M: Echocardiography, data analysis, and reviewing the manuscript; M.N: Data collection, data interpretation, and reviewing the manuscript; K.K: Data collection, data analysis, and reviewing the manuscript. All authors have read and approved the final manuscript and agree to be accountable for all aspects of the work in ensuring that questions related to the accuracy or integrity of any part of the work are appropriately investigated and resolved.

Conflict of Interest: None declared.

References

- 1 Zhao J, Li J, Wei X, Zhao B, Sun W. Tricuspid valve detachment in closure of congenital ventricular septal defect. *Tex Heart Inst J*. 2003;30:38-41. PubMed PMID: 12638669; PubMed Central PMCID: PMCPMC152833.
- 2 Sarkislali K, Kalangos A. Late Tricuspid Regurgitation after Percutaneous Transcatheter Closure of Ventricular Septal Defect: an Educational Presentation. *Braz J Cardiovasc Surg*. 2021;36:253-6. doi: 10.21470/1678-9741-2020-0172. PubMed PMID: 33577256; PubMed Central PMCID: PMCPMC8163272.
- 3 Said SM, Dearani JA, Burkhardt HM, Connolly HM, Eidem B, Stensrud PE, et al. Management of tricuspid regurgitation in congenital heart disease: is survival better with valve repair? *J Thorac Cardiovasc Surg*. 2014;147:412-7. doi: 10.1016/j.jtcvs.2013.08.034. PubMed PMID: 24084288.
- 4 Mertens L, Meyns B, Gewillig M. Device fracture and severe tricuspid regurgitation after percutaneous closure of perimembranous ventricular septal defect: a case report. *Catheter Cardiovasc Interv*. 2007;70:749-53. doi: 10.1002/ccd.21198. PubMed PMID: 17563097.
- 5 Liu SP, Li L, Yao KC, Wang N, Wang JC. Investigation of membranous ventricular septal defect complicated with tricuspid regurgitation in ventricular septal defect occlusion. *Exp Ther Med*. 2013;5:865-9. doi: 10.3892/etm.2012.876. PubMed PMID: 23404058; PubMed Central PMCID: PMCPMC3570173.
- 6 Topcuoglu MS, Atalay A, Gocen U, Guzel Y, Basturk Y, Demir F. An Unusual Complication of the Ventricular Septal Defect Closure by Device: Late Right Aortic Cusp Perforation. *Heart Lung Circ*. 2015;24:e118-21. doi: 10.1016/j.hlc.2014.11.010. PubMed PMID: 25937396.
- 7 Tang C, Shao S, Zhou K, Hua Y, Luo C, Wang C. Complete Left Bundle-Branch Block After Transcatheter Closure of Perimembranous Ventricular Septal Defect Using Amplatzer Duct Occluder II. *J Am Heart Assoc*. 2022;11:e022651. doi: 10.1161/JAHA.121.022651. PubMed PMID: 35350872; PubMed Central PMCID: PMCPMC9075492.
- 8 Cen H, Peng B, Li J, Chen S, Sun P. Efficacy and safety of the Amplatzer Duct Occluder II for ventricular septal defect closure: a meta-analysis. *Kardiol Pol*. 2021;79:401-9. doi: 10.33963/KP.15762. PubMed PMID: 33506659.
- 9 Amoozgar H, Edraki MR, Naghshzan A, Mehdizadegan N, Mohammadi H, Ajami G, et al. Midterm follow up of transcatheter closure of coronary artery fistula with Nit-Occlud(R) patent ductus arteriosus coil. *BMC Cardiovasc Disord*. 2021;21:192. doi: 10.1186/s12872-021-01999-3. PubMed PMID: 33879042; PubMed Central PMCID: PMCPMC8056487.
- 10 Jiang D, Zhang J, Fan Y, Han B, Zhao L, Yi Y, et al. The Efficacy and Medium to Long-Term Follow-Up of Transcatheter Retrograde Closure of Perimembranous Ventricular Septal Defects via the Femoral Artery With Amplatzer Duct Occluder II in Children. *Front Pediatr*. 2021;9:571407. doi: 10.3389/fped.2021.571407. PubMed PMID: 34113582; PubMed Central PMCID: PMCPMC8185017.
- 11 Sievert H, Franke J, Qureshi SA, Bertog S, Wilson N, Gafoor S, et al. Interventions in structural, Valvular and congenital heart disease. 2nd ed. London: CRC Press; 2015. doi: 10.1201/b17909.
- 12 Amoozgar H, Shakiba AM, Derakhshan D, Ajami G, Cheriki S, Borzouee M, et al. Evaluation of left ventricular function by tissue Doppler and speckle-derived strain rate echocardiography after percutaneous ductus closure. *Pediatr Cardiol*. 2015;36:219-25. doi: 10.1007/s00246-014-0989-0. PubMed PMID: 25107547.
- 13 Sugiyama H, Hoshiai M, Tan T, Nakazawa S. Functional maturity of tricuspid and mitral valves in school children evaluated by echocardiography. *Heart*. 2005;91:1479-80. doi: 10.1136/hrt.2004.057083. PubMed PMID: 16230453; PubMed Central PMCID: PMCPMC1769171.
- 14 Eidem BW. Functional Evaluation of the Heart by Transesophageal Echocardiography. *Transesophageal Echocardiography for Congenital Heart Disease*. 2014:121-44. doi: 10.1007/978-1-84800-064-3_5.
- 15 Amoozgar H, Soltani R, Edraki M, Mehdizadegan N, Mohammadi H, Ajami G, et al. Hemolysis and its outcome following percutaneous closure of cardiac defects among children and adolescents: a prospective study. *Ital J Pediatr*. 2019;45:128. doi: 10.1186/s13052-019-0728-5. PubMed PMID: 31627743; PubMed Central PMCID: PMCPMC6798493.
- 16 Polat TB, Turkmen E. Transcatheter closure of ventricular septal defects using the Amplatzer Duct Occluder II device: a

- single-center experience. *Postepy Kardiol Interwencyjne*. 2016;12:340-7. doi: 10.5114/aic.2016.63635. PubMed PMID: 27980548; PubMed Central PMCID: PMC5133323.
- 17 Narin N, Baykan A, Pamukcu O, Argun M, Ozyurt A, Mese T, et al. ADO II in Percutaneous VSD Closure in Pediatric Patients. *J Interv Cardiol*. 2015;28:479-84. doi: 10.1111/joic.12222. PubMed PMID: 26345701.
- 18 Kanaan M, Ewert P, Berger F, Assa S, Schubert S. Follow-up of patients with interventional closure of ventricular septal defects with Amplatzer Duct Occluder II. *Pediatr Cardiol*. 2015;36:379-85. doi: 10.1007/s00246-014-1017-0. PubMed PMID: 25179462.
- 19 Zhao LJ, Han B, Zhang JJ, Yi YC, Jiang DD, Lyu JL. Transcatheter closure of congenital perimembranous ventricular septal defect using the Amplatzer duct occluder 2. *Cardiol Young*. 2018;28:447-53. doi: 10.1017/S1047951117002396. PubMed PMID: 29233213.
- 20 Haddad RN, Daou L, Saliba Z. Device Closure of Perimembranous Ventricular Septal Defect: Choosing Between Amplatzer Occluders. *Front Pediatr*. 2019;7:300. doi: 10.3389/fped.2019.00300. PubMed PMID: 31475122; PubMed Central PMCID: PMC6707042.
- 21 Xu XD, Liu SX, Bai Y, Zhang M, Zhao XX, Qin YW. Decreased tricuspid regurgitation following percutaneous closure of congenital perimembranous ventricular septal defect: immediate and 6-month echocardiographic assessment. *Heart Vessels*. 2015;30:611-7. doi: 10.1007/s00380-014-0531-6. PubMed PMID: 24946869.
- 22 Yang J, Yang L, Yu S, Liu J, Zuo J, Chen W, et al. Transcatheter versus surgical closure of perimembranous ventricular septal defects in children: a randomized controlled trial. *J Am Coll Cardiol*. 2014;63:1159-68. doi: 10.1016/j.jacc.2014.01.008. PubMed PMID: 24509270.
- 23 Kuwelker SM, Shetty DP, Dalvi B. Surgical repair of tricuspid valve leaflet tear following percutaneous closure of perimembranous ventricular septal defect using Amplatzer duct occluder I: Report of two cases. *Ann Pediatr Cardiol*. 2017;10:61-4. doi: 10.4103/0974-2069.197052. PubMed PMID: 28163430; PubMed Central PMCID: PMC5241847.
- 24 Rahmath MR, Numan M, Dilawar M. Medium to long-term echo follow-up after ventricular septal defect device closure. *Asian Cardiovasc Thorac Ann*. 2016;24:422-7. doi: 10.1177/0218492316645746. PubMed PMID: 27112358.
- 25 Kulyabin YY, Soynov IA, Zubritskiy AV, Voitov AV, Nichay NR, Gorbatykh YN, et al. Does mitral valve repair matter in infants with ventricular septal defect combined with mitral regurgitation? *Interact Cardiovasc Thorac Surg*. 2018;26:106-11. doi: 10.1093/icvts/ivx231. PubMed PMID: 29049781.
- 26 Cho HJ, Ma JS, Cho YK, Ahn BH, Na KJ, Jeong IS. Timing in resolution of left heart dilation according to the degree of mitral regurgitation in children with ventricular septal defect after surgical closure. *J Pediatr (Rio J)*. 2014;90:71-7. doi: 10.1016/j.jped.2013.06.008. PubMed PMID: 24140379.
- 27 Mahadin DR, Srivastava S, Parness IA, Nguyen K, Love BA, Walsh R, et al. Outcomes of mitral regurgitation associated with large ventricular septal defect and a normal mitral valve apparatus: does intact atrial septum have an impact? *Pediatr Cardiol*. 2011;32:1128-31. doi: 10.1007/s00246-011-9994-8. PubMed PMID: 21512787.
- 28 Lin HC, Lin MT, Chen CA, Hsu JY, Lin SM, Wu MH, et al. Safety and efficacy of transcatheter closure of outlet-type ventricular septal defects in children and adults with Amplatzer Duct Occluder II. *J Formos Med Assoc*. 2021;120:180-8. doi: 10.1016/j.jfma.2020.04.015. PubMed PMID: 32402520.
- 29 Holzer R, de Giovanni J, Walsh KP, Tometzki A, Goh T, Hakim F, et al. Transcatheter closure of perimembranous ventricular septal defects using the amplatzer membranous VSD occluder: immediate and midterm results of an international registry. *Catheter Cardiovasc Interv*. 2006;68:620-8. doi: 10.1002/ccd.20659. PubMed PMID: 16969878.
- 30 Ghosh S, Sridhar A, Sivaprakasam M. Complete heart block following transcatheter closure of perimembranous VSD using amplatzer duct occluder II. *Catheter Cardiovasc Interv*. 2018;92:921-4. doi: 10.1002/ccd.27177. PubMed PMID: 28707408.